

Content available at: <https://www.ipinnovative.com/open-access-journals>

IP Archives of Cytology and Histopathology Research

Journal homepage: <https://www.achr.co.in/>

Original Research Article

Histopathological evaluation of Endometrium hyperplasia and it's correlation with the clinical parameters in a tertiary care hospital

Upasana Uniya¹, Archana Shrivastava¹, Tina Rai^{2,*}, G.S Rai³¹Dept. of Pathology, Gandhi Medical College, Bhopal, Madhya Pradesh, India²Dept. of Pathology, ABV Govt. Medical College, Vidisha, Madhya Pradesh, India³Dept. of Radiology, Peoples College of Medical Sciences and Research Centre, Bhopal, Madhya Pradesh, India

ARTICLE INFO

Article history:

Received 05-07-2021

Accepted 05-08-2021

Available online 16-09-2021

Keywords:

Endometrial hyperplasia

Clinical complains

Clinicopathological correlation

ABSTRACT

Introduction: Abnormal uterine bleeding is a common clinical presentation in the perimenopausal age group its biopsy serves as an excellent clue to the underlying disease. The presentation may vary according to the type of endometrial hyperplasia and their correlation helps in the proper management of the patients complain.

Objective: To analyze the histopathological patterns of endometrial hyperplasia as well as to correlate endometrial hyperplasia with the clinical parameters.

Materials and Methods: It is a retrospective study and included one year data. A total of 125 cases that underwent hysterectomies or endometrial biopsies for abnormal uterine bleeding were recorded with their clinical history. For all cases the histopathology slides were re-evaluated and results were recorded. Epidemiological variables were analyzed by cross tabulation to assess their relationship.

Result: Out of 125 cases 53 cases had endometrial hyperplasia, 24 cases were having simple hyperplasia followed by 14 cases with simple hyperplasia without atypia, 9 cases with complex hyperplasia with atypia followed by 6 cases with complex hyperplasia without atypia. 30 to 50 years age group commonly had endometrial hyperplasia & menorrhagia was the common clinical complain in our patients.

Conclusion: In all the females coming to OPD with abnormal uterine bleeding clinical correlation should be properly made with biopsy report of the patient for the proper management of the condition, which avoids landing up of the patient into further complication.

This is an Open Access (OA) journal, and articles are distributed under the terms of the [Creative Commons Attribution-NonCommercial-ShareAlike 4.0 License](https://creativecommons.org/licenses/by-nc-sa/4.0/), which allows others to remix, tweak, and build upon the work non-commercially, as long as appropriate credit is given and the new creations are licensed under the identical terms.

For reprints contact: reprint@ipinnovative.com

1. Introduction

Endometrium biopsies & hysterectomies specimen for any abnormal bleeding are commonly received in the department of pathology. Their diagnosis made on the light microscopy is quite helpful in planning the treatment for the patient since in most of the patients who are having endometrial hyperplasia with atypia are prone to develop endometrial carcinoma.

Endometrium is constantly engaged in the dynamics of shedding & regrowth during active reproductive life, it is controlled by rise & fall of pituitary hormones. Alterations in the fine tuning mechanism may result in a spectrum of disturbances & endometrial hyperplasia is most important among them. Arising Endometrial hyperplasia often precedes the development of endometrial carcinoma. More recently, studies have found that the risk of endometrial hyperplasia is associated with increasing body mass index & nulliparity.¹ In addition to this increasing obesity, anovulatory cycles & exogenous hormones are associated with endometrial & endometrial carcinoma both.

* Corresponding author.

E-mail address: drtina_rai@yahoo.com (T. Rai).

The role of unopposed estrogen has been supported by many studies since high levels of estrogen has been found in the patients with endometrial carcinoma.^{2,3}

Endometrial hyperplasia is defined as a proliferation of glands of irregular size & shape with an associated increase in gland to stroma ratio compared with proliferative endometrium. The process is generally diffuse but it may be focal also. The WHO classification, presently the most widely used, is a four –tier classification system takes into the account both cytologic & architectural abnormalities.⁴

In the past the terms “adenomatous hyperplasia “ & “atypical hyperplasia “were used to denote proliferative lesions of the endometrium with varying degrees of architectural complexity & cytological atypia^{5–9} in addition, the term “carcinoma in situ” was proposed to describe small lesions, with or without glandular crowding, having the cytologic features of carcinoma but lacking invasion.^{7,9,10} We used WHO Classification in our study. In addition, a more recent epidemiologic study added further support for this simplified classification by showing that the only lesions that significantly increased the relative risk of carcinoma with atypical hyperplasia.¹¹

1.1. WHO classification of endometrial hyperplasia

1. Hyperplasia without atypia, Simple hyperplasia without atypia, Complex hyperplasia without atypia.
2. Atypical hyperplasia, Simple (atypical hyperplasia), Complex atypical hyperplasia.

Patients with endometrial hyperplasia typically have abnormal bleeding. Occasionally the lesion is detected by endometrial biopsy performed during the course of infertility workup or before the start of hormonal therapy in post menopausal females. Hyperplasia usually appears as a result of unopposed estrogen use. And so most patients have a history of either persistent anovulation or exogenous unopposed estrogen usage. Though anovulation occurs at menarche & perimenopausal women, hyperplasia is not usually found in young women.

2. Aims & Objectives

1. To study the Histopathological patterns of endometrial hyperplasia.
2. To correlate endometrial hyperplasia with clinical parameters.

3. Materials and Methods

This is a hospital based study done in the department of pathology at a tertiary care hospital.

Study was conducted on 125 cases of endometrial hyperplasia which were re-evaluated and their relevant clinical details like menstrual history including age of menarche, date of last menstrual period, number of children,

any history of abortions, age of menopause if occurred, any history of taking HRT and were recorded. Histological typing of endometrial hyperplasia by re-evaluating them under light microscopy & typing was done depending on the criteria used in WHO classification.

4. Results

Table 1: Spectrum of lesions

S. No.	Histopathology	No. of cases	%
1.	Endometrial hyperplasia	53	42.4
2.	Proliferative phase	21	16.8
3.	Secretory phase	26	20.8
4.	Hormonal effects	12	9.6
5.	Atrophic endometrium	09	7.2
6.	Irregular shedding with endometritis	04	3.2
Total		125	100

Table 2: Distribution of cases according to the type of endometrial hyperplasia

S. No.	Type of hyperplasia	No. of cases	%
1.	Simple hyperplasia	24	45.2
2.	Complex hyperplasia	06	11.3
3.	Simple hyperplasia with atypia	14	26.4
4.	Complex hyperplasia with atypia	09	17
Total		53	100

Table 3: Age distribution in patients with endometrial hyperplasia

S. No.	Age of the patient	Total	%
1.	21-30yrs	02	4%
2.	31-40yrs	22	42%
3.	41-50yrs	21	39%
4.	> 50yrs	08	15%
		53	

Table 4: Distribution of cases according to clinical complains

S. No.	Clinical complains	No. of cases with Endometrial Hyperplasia	%
1	Menorrhagia	88	70
2	Post menopausal bleed	17	14
3	Continuous bleed	18	15
4.	Others	02	1

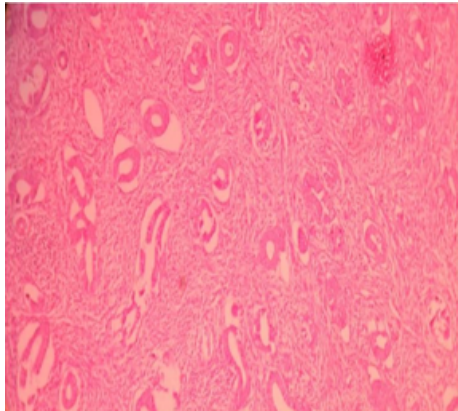


Fig. 1: Pictomicrograph of the section showing endometrial glands in proliferative phase (H&E 10X)

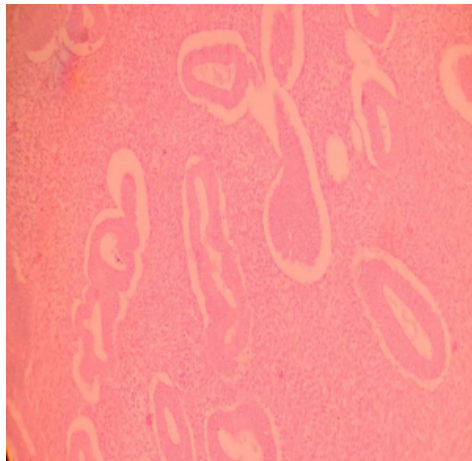


Fig. 2: Pictomicrograph of the section showing of endometrial glands in secretory phase (H&E 10x)

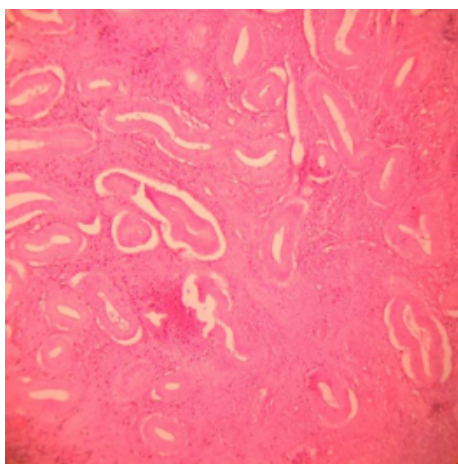


Fig. 3: Pictomicrograph of the section showing of endometrial glands with simple hyperplasia (H&E 10x)

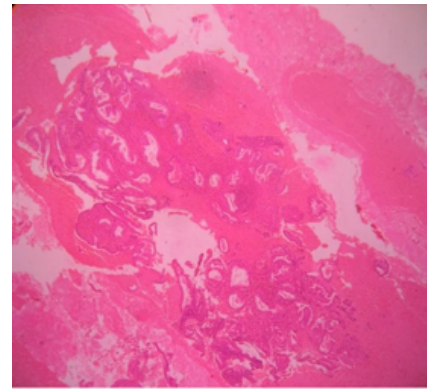


Fig. 4: Pictomicrograph of the section showing of endometrial glands with complex hyperplasia without atypia (H&E 10x)

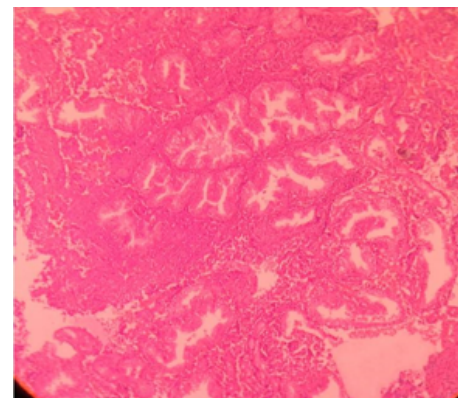


Fig. 5: Pictomicrograph of the section showing endometrial glands with complex hyperplasia with atypia (H&E 10X)

5. Discussion

Endometrial hyperplasia is the most common gynaecological disorder, it is due to unopposed estrogen stimulation. Endometrial assessment is performed to diagnose malignant & premalignant conditions & to evaluate the hormonal influences on the endometrium. In this study a total of 125 cases were assessed.

In our study 53 cases presented with endometrial hyperplasia followed by secretory phase, then proliferative phase, 9 cases presented with atrophic endometrium & four of them had irregular shedding with endometritis.

Out of 53 patients 24 (45%) patients presented with simple hyperplasia, 14 patients had simple hyperplasia without atypia, 9 presented with complex hyperplasia without atypia followed by 6 patients having complex hyperplasia without atypia.

The peak incidence of endometrial hyperplasia was noted in 3rd and 4th decade followed by 5th decade with only 2 patients lying in the age group of 21 to 30 years.

Gusberg & Kaplan¹² in their study (1963) of 191 cases the peak incidence of endometrial hyperplasia was noted in

4th decade followed by 5th decade.

The most common clinical complain in our study was menorrhagia followed by continuous bleeding, post menopausal bleeding in 17 patients our results were in concordance with the studies of Takreem et al.

Takreem et al¹³ also found out that menorrhagia is the commonest complain in endometrial hyperplasia (53.3%) which is in concordance with our study that is 66.6%.

6. Conclusion

It is very important to know the histopathological pattern of endometrium especially the hyperplasia going in them and their correlation with clinical parameters. Since early and proper recognition of these conditions helps in the proper management, treatment avoid landing up of the patients into further complications.

7. Conflict of Interest

The authors declare that there are no conflicts of interest in this paper.

8. Source of Funding

None.

References

1. Epplein M, Reed SD, Voigt LF, Newton KM, Holt VL, Weiss NS, et al. Risk of complex and atypical endometrial hyperplasia in relation to anthropometric measures and reproductive history. *Am J Epidemiol*. 2008;168(6):563–70. doi:10.1093/aje/kwn168.
2. Brinton LA, Berman ML, Mortel R, Twiggs LB, Barrett RJ, Wilbanks GD, et al. Reproductive, menstrual, and medical risk factors for endometrial cancer: results from a case-control study. *Am J Obstet Gynecol*. 1992;167(5):1317–25. doi:10.1016/s0002-9378(11)91709-8.
3. Potischman N, Hoover RN, Brinton LA, Siiteri P, Dorgan JF, Swanson CA, et al. Case-control study of endogenous steroid hormones and endometrial cancer. *J Natl Cancer Inst*. 1996;88(16):1127–35. doi:10.1093/jnci/88.16.1127.
4. Leung ASY, Vinyuvat S, Leong F. Anti-CD38 and VS38 antibodies for detection of plasma cells in the diagnosis of chronic endometritis. *Appl Immunohistochem Mol Morphol*. 1977;5:189–93.
5. Brinton LA, Hoover RN. Endometrial Cancer Collaborative Group (1993) Estrogen replacement therapy and endometrial cancer risk: a meta-analysis. *Obstet Gynecol*;81(2):265–71.
6. Critchley HO, Tong S, Cameron S, Drudy TA, Kelly RW, Baird DT, et al. Regulation of bcl-2 gene family members in human endometrium by antiprogestin administration in vivo. *J Reprod Fertil*. 1999;115(2):389–95. doi:10.1530/jrf.0.1150389.
7. Disep B, Innes BA, Cochrane HR. Immunohistochemical characterization of endometrial leucocytes in endometritis. *Histopathology*. 2004;45(6):625–32. doi:10.1111/j.1365-2559.2004.02052.x.
8. Kaufman RH, Binder GL, Gray PN. Upper genital tract changes associated with exposure in utero to diethylstilbestrol. *Am J Obstet Gynecol*. 1977;128(1):51–9. doi:10.1016/0002-9378(77)90294-0.
9. McKenna M, McCluggage WG. Signet ring cells of stromal derivation in the uterine cervix secondary to cauterization: report of a previously undescribed phenomenon. *J Clin Pathol*. 2008;61(5):648–51. doi:10.1136/jcp.2007.054767.
10. McCluggage WG, Oliva E, Herrington CS. CD10 and calretinin staining of endocervical glandular lesions, endocervical stroma and endometrioid adenocarcinomas of the uterine corpus: CD10 positivity is characteristic of, but not specific for, mesonephric lesions and is not specific for endometrial stroma. *Histopathology*. 2003;43(2):144–50. doi:10.1046/j.1365-2559.2003.01684.x.
11. Grady D, Gebrestsadik T, Kerlikowske K. Hormone replacement therapy and endometrial cancer risk: a meta-analysis. *Obstet Gynaecol*. 1995;85(2):304–13. doi:10.1016/0029-7844(94)00383-O.
12. Gusberg SB, Kaplan AL. Precursors of Corpus Cancer .IV. Adenomatous Hyperplasia as Stage O Carcinoma of the Endometrium. *Am J*. 1963;87(5):662–78.
13. Takreem A, Danish N, Razaq S. incidence of endometrial hyperplasia in 100 cases presenting with polymenorrhagia/menorrhagia in perimenopausal women. *J Ayub Med Coll Abbottabad*. 2008;21(s2):60–3.

Author biography

Upasana Uniya, Assistant Professor

Archana Shrivastava, Associate Professor

Tina Rai, Associate Professor

G.S Rai, Professor

Cite this article: Uniya U, Shrivastava A, Rai T, Rai GS. Histopathological evaluation of Endometrium hyperplasia and it's correlation with the clinical parameters in a tertiary care hospital. *IP Arch Cytol Histopathology Res* 2021;6(3):187-190.