

Content available at: <https://www.ipinnovative.com/open-access-journals>

IP Archives of Cytology and Histopathology Research

Journal homepage: <https://www.achr.co.in/>

Original Research Article

A descriptive study of Endometrial Biopsies in perimenopausal women having Abnormal uterine bleeding

Manjushree Prabhu P¹, Sandhya I^{1,*}, Purnima S Rao¹, Sameeksha Alwa¹¹Dept. of Pathology, A.J. Institute of Medical Sciences and Research Centre, Mangalore, Karnataka, India

ARTICLE INFO

Article history:

Received 15-07-2021

Accepted 23-08-2021

Available online 16-09-2021

Keywords:

Abnormal uterine bleeding
Endometrium

ABSTRACT

Introduction: Abnormal uterine bleeding (AUB) is one of the commonest symptom with which the perimenopausal female visits the gynaecologist accounting for over 70% of all gynecological consultations in that age group.¹ The clinical presentation of AUB can range anywhere menorrhagia, polymenorrhea, polymenorrhagia, metrorrhagia, and menometrorrhagia. Though biopsy is the gold standard it is an invasive procedure and hence often an Ultrasound is used to evaluate the pathology of the endometrium routinely hence, we decided to study the accuracy between radiological ET thickened and its usefulness in detecting endometrial pathology.

Materials and Methods: This study was carried out in the Department of Pathology at AJIMS, Mangalore for a period of 2 years. The sample included endometrial biopsies and hysterectomy specimens of perimenopausal women for AUB. The ultrasonographic findings and Histopathological (HPE) reports were analysed.

Results: Among 101 cases for AUB, 67 cases were diagnosed as non secretory endometrium. Out of these 67 cases, 49 cases were associated with fibroids. Out of the rest of the AUB cases, 31 of them were diagnosed to have endometrial hyperplasia and 3 cases were diagnosed to have endometrial carcinoma. USG thickness of 17(54%) out of 31 endometrial hyperplasia cases were abnormal.

Conclusion: Radiological and pathological evaluation were concordant with diagnosis of AUB associated with fibroids. However only 54% of the endometrial hyperplasia were found to have abnormal endometrial thickness. Radiological evaluation of endometrial thickness is not concordant in 46 % of the cases. This implies that histopathological examination is gold standard diagnostic tool for endometrial abnormalities in perimenopausal women.

This is an Open Access (OA) journal, and articles are distributed under the terms of the [Creative Commons Attribution-NonCommercial-ShareAlike 4.0 License](https://creativecommons.org/licenses/by-nc-sa/4.0/), which allows others to remix, tweak, and build upon the work non-commercially, as long as appropriate credit is given and the new creations are licensed under the identical terms.

For reprints contact: reprint@ipinnovative.com

1. Introduction

Abnormal uterine bleeding (AUB) is one of the commonest symptom with which the perimenopausal female visits the gynaecologist accounting for over 70% of all gynecological consultations in that age group.¹ The clinical presentation of AUB can range anywhere menorrhagia, polymenorrhea, polymenorrhagia, metrorrhagia, and menometrorrhagia.²

Studies done over the past few years have shown that in the past few decades there is a rising trend increase in the incidence of endometrial adenocarcinoma, especially in the Indian subcontinent.³

Though biopsy is the gold standard it is an invasive procedure and hence often an Ultrasound is used to evaluate the pathology of the endometrium routinely. Hence, we decided to study the accuracy between radiological ET thickened and its usefulness in detecting endometrial pathology.

* Corresponding author.

E-mail address: drsandhyai@yahoo.co.in (Sandhya I).

2. Materials and Methods

This study was carried out in the Department of Pathology at AJIMS, Mangalore for a period of 2 years. The study was started after obtaining ethical clearance from the institutions ethical clearance committee.

Patients between the age of 40 and 55 who were confirmed by history to be in the perimenopausal period were selected and explained of the study. Those who gave informed written consent to participate in the study were chosen. These patients underwent ultrasound in which the endometrial thickness was measured at 3 levels and an average noted, the endometrial volume was also noted, following this a pre anaesthetic check-up was done and the patient was posted for biopsy, in those who underwent endometrial biopsies at least 4 samples of tissue was collected for biopsy. Those who had adequate samples were selected sampled and the histology was co related with the ET. A cut off of 4 mm was taken to differentiate between benign and malignant disease.

The sample included endometrial biopsies and hysterectomy specimens of perimenopausal women for AUB. The ultrasonographic findings and Histopathological (HPE) reports were analysed.

3. Results

Among 101 cases for AUB, 67 cases were diagnosed as non secretory endometrium. Out of these 67 cases, 49 cases were associated with fibroids. Out of the rest of the AUB cases, 31 of them were diagnosed to have endometrial hyperplasia and 3 cases were diagnosed to have endometrial carcinoma. USG thickness of 17(54%) out of 31 endometrial hyperplasia cases were increased.

The age group in the study ranged between 40 and 50 years the mean age was 47.89 SD + 5.91 years.

3.1. These were our findings

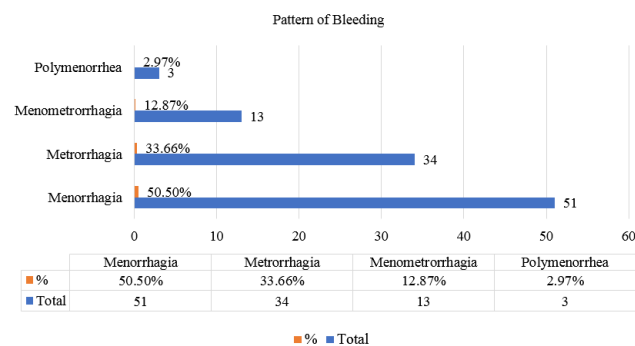


Fig. 1:

Table 1:

Type of endometrium	Case	Percentage
non secretory endometrium	67	66.34%
Endometrial lesions	34	33.66%
non secretory endometrium	Case	Percentage
fibroids	49	73.13%
No fibroids	18	26.87%
	Case	Percentage
endometrial hyperplasia	31	91.18%
endometrial carcinoma	3	8.82%
Endometrial hyperplasia(31)	Case	Percentage
Increased USG thickness	17	54.84%
USG thickness normal	14	45.16%

Table 2:

Statistic	Value	95% CI
Sensitivity	66.67%	44.68% to 84.37%
Specificity	85.71%	42.13% to 99.64%
Positive Likelihood Ratio	4.67	0.74 to 29.28
Negative Likelihood Ratio	0.39	0.20 to 0.74
Disease prevalence (*)	77.42%	58.90% to 90.41%
Positive Predictive Value (*)	94.12%	71.83% to 99.01%
Negative Predictive Value (*)	42.86%	28.31% to 58.76%
Accuracy (*)	70.97%	51.96% to 85.78%

4. Discussion

After ruling out medical reasons, endometrial biopsy or curettage might be a safe and useful diagnostic step in the examination of AUB. The perimenopausal age group is the commonest age group affected in endometrial pathologies shows studies done by Soleymani E et al.⁴ Shwetha Agrawal et al.⁵ Jagadale Kunda et al.⁶ Out of 101 AUB cases, 3 cases were endometrial malignancy a similar study done by K. Gruboeck et al⁷ noted that 11.34% of cases had evidence of endometrial malignancy and in them the mean ET was 29.5 mm + SD 12.59 and the mean volume was 39.0 ml + SD 34.16). 88.66% had endometrial hyperplasia and 7.22 had endometrial polyps and in them the mean ET volume was 15.64 mm (SD 5.26) and 5.47 ml (SD 6.32), respectively.

Richard J. Persadi et al⁸ did a met analytical study and stated that the use of TVS has a good sensitivity to find out endometrial cancer and whenever the thickness is more than 5 mm it needs to be sampled to rule of the possibility of malignant disease. In our study 17 out of 31 cases of endometrial hyperplasia showed increased endometrial thickness. Remaining 14 showed normal

endometrial thickness but with endometrial hyperplasia. A study done by Janesh K Gupta et al⁹ in their meta analysis noted that ultrasound size of ET only, cannot be used to precisely rule out pathology. However, a negative result at < or = 5 mm cut-off level measuring both endometrial layers in the presence of endometrial pathology rules out endometrial pathology with good certainty. Sreelakshmy Krishnankutty Nair et al¹⁰ at a cut off of 4mm noted that transvaginal sonography showed a sensitivity of 71.79%, specificity of 100%, positive predictive value of 100% and negative predictive value of 50% overall.

The sensitivity of transvaginal sonography in detecting premalignant lesions was 75.76%, specificity was 82.35%, positive predictive value was 89.29% and negative predictive value was 63.64%. Ritu Mishra et al¹¹ study showed the sensitivity, PPV and specificity of TVS were 73.9%, 77.3% and 73.7%. Cacciatore et al¹² For TVS the sensitivity and specificity versus endometrial pathology were 73.9% and 73.7%.

5. Conclusion

Radiological and pathological evaluation were concordant with diagnosis of AUB associated with fibroids. However only 54% of the endometrial hyperplasia were found to have abnormal endometrial thickness. Radiological evaluation of endometrial thickness is not concordant in 46% of the cases. This study emphasizes on histopathological examination in perimenopause women with abnormal uterine bleeding with normal endometrial thickness on sonographic findings.

6. Conflict of Interest

The authors declare that there are no conflicts of interest in this paper.

7. Source of Funding

None.

References

1. Mahajan N, Aggarwal M, Bagga A. Health issues of menopausal women in North India. *J Midlife Health*. 2012;3(2):84–7.
2. Kumar P, Malhotra N. Clinical types of abnormal uterine bleeding. In: Kumar P, editor. *Jeffcoate's Principle of Gynecology*. 7th Edn. New Delhi: Jaypee Brothers Medical Publishers; 2008. p. 599.

3. Faria SC, Sagebiel T, Balachandran A. Imaging in endometrial carcinoma. *Indian J Radiol Imaging*. 2015;25(2):137–47.
4. Soleymani E, Ziari K, Rahmani O. Histopathological findings of endometrial specimens in abnormal uterine bleeding. *Arch Gynecol Obstet*. 2014;289(4):845–9.
5. Agrawal S, Mathur A, Vaishnav K. Histopathological study of endometrium in abnormal uterine bleeding in women of all age groups in western rajasthan (400 cases). *Int J Basic Appl Med Sci*. 2014;4(3):15–8.
6. Kunda J, Anupam S. Histopathological study of endometrium in abnormal uterine bleeding in reference to different age groups, parity and clinical symptomatology. *Int J Clin and Biomed Res*. 2015;1(2):90–5.
7. Gruboeck K, Jurkovic D, Lawton F, Savvas M, Tailor A, Campbell S. The diagnostic value of endometrial thickness and volume measurements by three-dimensional ultrasound in patients with postmenopausal bleeding. *Ultrasound Obstet Gynecol*. 1996;8(4):272–6.
8. Persadie RJ. Ultrasonographic assessment of endometrial thickness: a review. *J Obstet Gynaecol Canada*. 2002;24(2):131–6.
9. Gupta JK, Chien PF, Voit D, Clark TJ, Khan KS. Ultrasonographic endometrial thickness for diagnosing endometrial pathology in women with postmenopausal bleeding: a meta-analysis. *Acta Obstet Gynecol Scand*. 2002;81(9):799–816. doi:10.1034/j.1600-0412.2001.810902.x.
10. Nair SK, Nair RV, Rajendran A. Comparative study of transvaginal ultrasound with histopathology in diagnosing endometrial pathology in postmenopausal bleeding. *J Evol Med Dent Sci*. 2016;5(14):640–2.
11. Mishra R, Misra AP, Mangal Y. To Compare the Results of TVS and SIS with Hysteroscopy and Histopathological Examination in Perimenopausal & Postmenopausal Bleeding". *J Evol Med Dent Sci*. 2015;4(7):1230–7.
12. Cacciatore B, Ramsay T, Lehtoirta P, Ylostalo P. Transvaginal sonography and hysteroscopy in postmenopausal bleeding. *Acta Obstet Gynecol Scand*. 1994;73(5):413–6.

Author biography

Manjushree Prabhu P, Post Graduate

Sandhya I, Professor

Purnima S Rao, Professor

Sameeksha Alwa, Post Graduate

Cite this article: Prabhu P M, Sandhya I, Rao PS, Alwa S. A descriptive study of Endometrial Biopsies in perimenopausal women having Abnormal uterine bleeding. *IP Arch Cytol Histopathology Res* 2021;6(3):203-205.