



## Case Report

# Dirofilariasis in humans presenting as a subcutaneous nodule

Srikousthubha MS<sup>1,\*</sup>, Mohandas AS<sup>2</sup>

<sup>1</sup>Dept. of Pathology, Shimoga Diagnostic Centre, Shimoga, Karnataka, India

<sup>2</sup>Dept. of Surgery, Sri Raghavendra Nursing Home, Shimoga, Karnataka, India



### ARTICLE INFO

#### Article history:

Received 10-07-2021

Accepted 27-08-2021

Available online 16-09-2021

#### Keywords:

Dirofilariasis

Human

subcutaneous

### ABSTRACT

Human dirofilariasis is an uncommon zoonotic roundworm infection caused by worms belonging to dirofilaria species transmitted by zoo -anthropophilic blood sucking insects which is known to manifest as ocular infection or as a subcutaneous nodule usually in the upper part of the body. We present a case report of subcutaneous dirofilariasis in the left temporal region besides the eye brow in a 65yr old female, clinically diagnosed as epidermal cyst. Gross and histopathological evaluation revealed the presence of an adult worm with granulomatous inflammatory reaction.

This is an Open Access (OA) journal, and articles are distributed under the terms of the [Creative Commons Attribution-NonCommercial-ShareAlike 4.0 License](https://creativecommons.org/licenses/by-nc-sa/4.0/), which allows others to remix, tweak, and build upon the work non-commercially, as long as appropriate credit is given and the new creations are licensed under the identical terms.

For reprints contact: [reprint@ipinnovative.com](mailto:reprint@ipinnovative.com)

## 1. Introduction

Human dirofilariasis is an uncommon zoonotic disease where man is an accidental host. About forty species of *Dirofilaria* are identified, among which only a few give rise to human infection.<sup>1</sup> *Dirofilaria repens* is the commonest species identified in India. The first reported case of human ocular dirofilariasis in India occurred in Kerala in 1976 and subcutaneous dirofilariasis was recorded in the same region in 2004. Most of the documented cases in India are of ocular dirofilariasis. Very few cases of subcutaneous dirofilariasis have been reported.<sup>2</sup>

## 2. Case History

A 65yr old female housewife from an agricultural background presented with a non tender nodule in the left temporal region besides the eyebrow of 2 months duration which had gradually progressed to the size of 2.5 x 2 cm. It was firm in consistency. Skin over the swelling was normal. A provisional diagnosis of epidermal cyst was made,

excised and submitted for histopathological examination. Grossly, the specimen was grey white m 2.5 x 2 x 1.5 cm, cut section was solid grey white. On closer examination retrospectively revealed a thread like worm (Figure 1) Microscopic examination of Hematoxylin and Eosin stained sections showed granulation tissue with intense neutrophilic and eosinophilic infiltration, multinucleated giant cells, plasma cells. Cross section of a nematode parasite with a thick external cuticle, prominent circumferential muscle and cut section of intestine were recognized (Figure 1). Based on these findings the worm was identified as *Dirofilaria repens*. A diagnosis of Subcutaneous Dirofilariasis was made.

Complete blood counts and Peripheral smear examination did not show eosinophilia. Serum Ig E levels were normal. Ophthalmologic examination was requested to look for ocular parasite which was negative.

## 3. Discussion

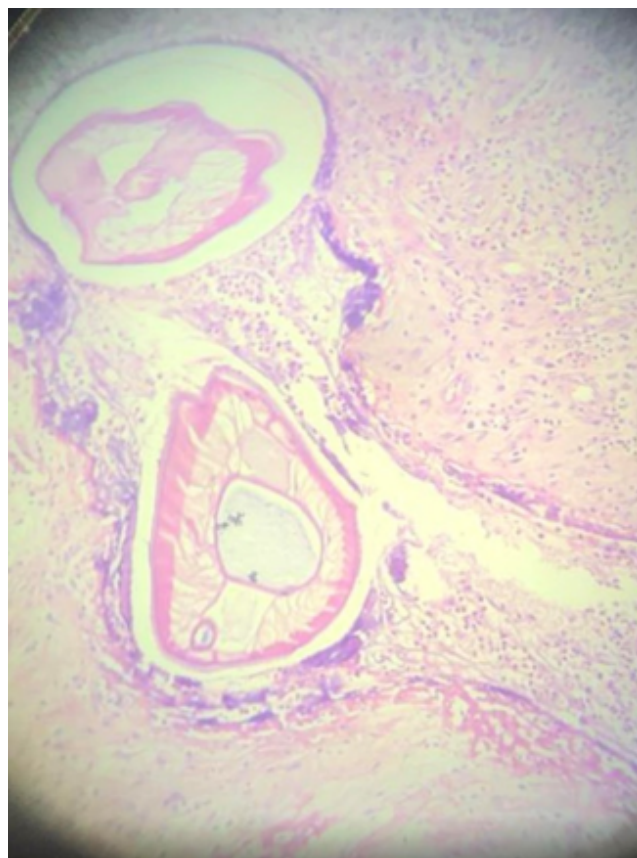
Human dirofilariasis is a zoonosis caused by animal filarial parasite *Dirofilaria* species. *D. repens*, *d. immitis*, *D. tenuis* and *D. urisi* are the known species causing human infection. *D. repens*, a parasite of cats and dogs is most commonly

\* Corresponding author.

E-mail address: [kousthubhaarun@gmail.com](mailto:kousthubhaarun@gmail.com) (Srikousthubha MS).



**Fig. 1:** Gross image of the filiform worm in the excised specimen.



**Fig. 2:** Photomicrograph of the worm showing multilayered cuticle, longitudinal ridges and intestine.

implicated in human dirofilariasis in Europe, Asia and Africa.<sup>1,2</sup> As with human filarial counterparts (*Brugia*, *Wuchereria*) *Dirofilaria* are transmitted by an arthropod intermediate hosts – various mosquito species including *Aedes*, *Anopheles*, *Culex* species, in which the microfilariae develop for about two weeks before reaching the infective stage. Dogs, wild canids and other mammals comprise the definitive host reservoir. After developing in subcutaneous tissue of the definitive host animal *dirofilaria* enter the blood supply and mature in the right side of the cardia and pulmonary arteries resulting in heart failure and pulmonary complications, explaining the lay labeling of *dirofilaria* as ‘Heartworm’. Humans are accidental hosts and human infections does not progress to allow for development into sexually mature helminthes.<sup>3</sup>

In humans, the infective larvae enter subcutaneous tissues. Case reports describe *dirofilaria* isolated from numerous sites including skin, orbits, oral cavity, scrotum, and peritoneal cavity. If the worms enter venous circulation it may embolize to the pulmonary arteries resulting in infarction and formation of a granulomatous pulmonary nodule. Serological studies have implicated *Dirofilaria* as the cause of eosinophilic meningitis, arthritis and childhood asthma.<sup>4</sup>

*Dirofilaria* is a nematode with long thin filiform appearance. Average diameter of the adult worm is approximately 450 micrometer. These worms have longitudinal ridges on an external cuticle, 2-5 chord nuclei per section and robust muscle cells. They have a rounded anterior end with a buccal cavity. In contrast to the rounded short tail of female worms, the male worms have a coiled tail with several perianal papillae. Identification of the species of *Dirofilaria* relies upon its gross and microscopic characteristics. *D.repens* is identified by the presence of external longitudinal cuticular ridges and transverse striations which are absent in *D. immitis*.<sup>5</sup> Worms isolated from human tissue appear to die prior to reaching sexual maturity. Pathology observed in dirofilariasis is generally believed to be due to the host immune response to dying worms and its contents.<sup>1</sup> In order to confirm the species, DNA extraction followed by pan filarial Polymerase chain reaction may be performed.<sup>1,2,6</sup> Surgical excision of the lesion is both diagnostic and therapeutic. Some advocate adding oral treatment with Albendazole, Diethylcarbamazine and Ivermectin.<sup>6</sup>

#### 4. Conclusion

Human infection with *Dirofilaria* has to be in the differential diagnosis of subcutaneous nodules showing granulomatous reaction as it is one of the emerging zoonotic infection in India. Most cases are diagnosed retrospectively, when the histopathological sections of biopsy are viewed. As the number of reported cases are increasing it is imperative that pathologists, microbiologists,

surgeons, ophthalmologists and veterinarians are aware of dirofilariasis. The development of specific and sensitive diagnostic tools for the most common specie *D. repens* and *D. immitis* may help in early diagnosis.

### 5. Conflict of Interest

The authors declare that there are no conflicts of interest in this paper.

### 6. Source of Funding

None.

### References

1. Human dirofilariasis: Clinical and epidemiological aspects. Theory and practice of parasitic disease control. 2020;21:261–6.
2. Khyriem A, Lynrah K, Lyngdoh W, Banik A. Subcutaneous dirofilariasis. *Indian J Med Microbiol.* 2013;31(4):403–5.
3. Simón F, Siles-Lucas M, Morchón R, González-Miguel J, Mellado I, Carretón E, et al. Human and Animal Dirofilariasis: the Emergence of a Zoonotic Mosaic. *Clin Microbiol Rev.* 2012;25(3):507–44.
4. Kini R, Leena J, Shetty P, Lyngdoh R, Sumanth D, George L, et al. Human dirofilariasis: an emerging zoonosis in India. *J Parasit Dis.* 2013;39(2):349–54.
5. Padmaja P, Samuel R, Kuruvilla P, Mathai E. Subcutaneous dirofilariasis in southern India: a case report. *Ann Trop Med Parasitol.* 2005;99(4):437–40.
6. Srinivasamurthy V, Rao S, Thejaswini M, Yoganand. Human subcutaneous dirofilariasis. *Ann Trop Med Public Health.* 2012;5(4):349.

### Author biography

**Srikousthubha MS**, Pathologist

**Mohandas AS**, Surgeon

**Cite this article:** Srikousthubha MS, Mohandas AS. Dirofilariasis in humans presenting as a subcutaneous nodule. *IP Arch Cytol Histopathology Res* 2021;6(3):225-227.