

Content available at: <https://www.ipinnovative.com/open-access-journals>

IP Archives of Cytology and Histopathology Research

Journal homepage: <https://www.achr.co.in/>

Original Research Article

Surgico-pathological analysis of testicular lesions

Surabhi Arun Vidhale^{1,*}, Pragati Upasham¹¹Dept. of Pathology, D.Y.Patil Medical College, Nerul, Navi Mumbai, Maharashtra, India

ARTICLE INFO

Article history:

Received 25-10-2021

Accepted 28-10-2021

Available online 02-12-2021

Keywords:

Testicular lesions

Neoplastic

Non neoplastic

ABSTRACT

Aims and Objective: The primary objective of our study was to identify the different types of histopathological lesions of testes and epididymis occurring in patients admitted in a tertiary care hospital, our aim was to evaluate the prevalence of testicular malignancies and characterize the tumor based on their histo-morphological features. Also, our objective was to correlate the clinico-laboratory findings of the various testicular lesions.

Settings and design: This was a prospective study of 2 years (October 2018 to October 2020) aggregating a total of 52 cases. The surgical specimens were referred to the pathology department for histopathological analysis.

Materials and Methods: A detailed preoperative history of every case with regards to age, presenting symptoms, and signs along with personal history were obtained.

Also, relevant investigations like serum tumor markers and Ultrasonography findings were analyzed. Postoperatively, the tissue was sent to the histopathology department and was studied by proper fixation, gross examination, adequate sampling, and paraffin sections of the same.

10% formalin was used to fix the specimen. Some resources suggest the use of Bouin solution for the fixation of testis biopsy specimens. However, the picric acid in the Bouin solution presents challenges for safe handling and disposal due to its explosive potential.

Hence, given the available resources in our laboratory setting, formalin was the preferred choice of fixative. We ensured that the specimens came in adequate amount of formalin from the OT with correct labeling. We excluded the autolyzed specimens. The data was noted and quantitative analysis was done.

The study was further compared with other previously reported studies.

Results: 52 cases were studied and majority of the cases were reported in the age group of 31-40yrs. 65.4% cases were non neoplastic, with testicular torsion being the commonest lesion. Amongst the 23.1% neoplastic cases that were reported, mixed germ cell tumor was the commonest (75%).

Conclusion: Non neoplastic lesions are more common than neoplastic lesions. Torsion testis was the commonest indication for orchidectomy in younger age group. Amongst the neoplastic testicular lesions mixed germ cell tumor was the commonest tumor. Despite newer techniques in imaging and tumor marker assays the diagnosis of testicular lesions is primarily dependent upon histopathological examination.

This is an Open Access (OA) journal, and articles are distributed under the terms of the [Creative Commons Attribution-NonCommercial-ShareAlike 4.0 License](https://creativecommons.org/licenses/by-nc-sa/4.0/), which allows others to remix, tweak, and build upon the work non-commercially, as long as appropriate credit is given and the new creations are licensed under the identical terms.

For reprints contact: reprint@ipinnovative.com

1. Introduction

The testis can be involved by various pathologies and affect a wide range of age groups. Distinct pathological conditions

affecting the testis and the epididymis mainly fall in the reproductive age group of third to fifth decades.¹

Testicular cancer comprises 1% of all tumors, seen most commonly between 15 - 34 years of age.²

Testicular lesions comprise both non-neoplastic and neoplastic lesions which are seen in pediatric as well

* Corresponding author.

E-mail address: surabhividhale93@gmail.com (S. A. Vidhale).

as adult age groups. They commonly present with scrotal pain, scrotal swelling, abdominal mass. Cryptorchid (undescended) testis, testicular torsion, testicular atrophy, epidermoid cysts, infections of testis like tuberculosis, infertility, malakoplakia, vasculitis form the spectrum of non-neoplastic testicular lesions.³

Undescended testis is the commonest genital malformation found in approximately 3% of term infants and 33% of premature boys.⁴

The most probable causes for atrophy of testis include cryptorchidism, the orchitis of mumps, liver cirrhosis, estrogen administration, radiation exposure, chemotherapy, AIDS, exposure to environmental toxins.¹

Nonspecific epididymo-orchitis is usually associated with infections in the urinary tract. Testicular torsion commonly seen in the age group of 10-25 years is considered a surgical emergency.⁵

Genitourinary tuberculosis commonly manifests as Tuberculous epididymo-orchitis. It may present as an isolated case or coexist with either pulmonary tuberculosis or tuberculosis of other parts of the lower genitourinary system including the urinary bladder, ureter, prostate. An isolated case of tuberculous epididymo-orchitis may mimic a testicular tumor.⁶

Neoplastic lesions of the testis are rare tumors seen in approximately 1% of all male cancers. They present in a younger age group between 15-35 years. Testicular carcinoma follows a reverse pattern with the incidence rate decreasing with increasing age.⁵

Clinically patients present with scrotal swelling with or without pain, fever, empty scrotum. Biochemically, the tumor markers including the Beta subunit of human chorionic gonadotropin, Alpha-fetoprotein, Lactate Dehydrogenase may be raised.

Histo-pathologically, the testicular tumors have varied gross and microscopic findings.

Various investigative modalities including ultrasound, CT scan, tumor marker assays, histopathological evaluation have made significant advances in providing an accurate diagnosis thus, contributing to the prognostic and therapeutic aspect of the disease. Histopathological study remains the prime modality of choice for the diagnosis of testicular tumors.

With this background, the present prospective study on surgico-pathological analysis of testicular lesions with clinical, biochemical, radiological correlations was done in the Department of Pathology, Dr. D. Y. Patil Medical College and Hospital, Navi Mumbai.

2. Observation and Results

Histopathological study of testis specimens was carried out in a total of 52 cases.

Ages at presentation ranged from < 1 year to 86 years.

The mean age of our study participants was 36.2 years with standard deviation of 21.3 years. Testicular lesions were more common in the age group of 31 to 40 years (26.9%) and least common in age groups 41 to 50 years of age (5.8%).

The majority of the patients (67.3%) were within the 4th decade of life at the time of initial diagnosis.

Amongst testicular lesions, 65.4% were non-neoplastic lesions and 23.1% were neoplastic lesions.

Non-neoplastic lesions include cryptorchidism, epididymo-orchitis, and torsion of testis and a few other like testicular hematoma, abscess, atrophic testis, infected tunica vaginalis and nubbin of testis.

Neoplastic testicular lesions categorized into 2 major types primary germ cell tumor and sex cord stromal tumors.

Out of the 12 neoplastic cases that were recorded, 9 were categorised as mixed germ cell tumor, 2 cases were reported as seminoma and 1 case of lymphoma.

The most common non-neoplastic testicular lesion was torsion testis (27.3%) followed by cryptorchidism (18.2%).

Maximum number of cases were seen on right side (48.1%) and left sided lesions were seen in 46.2% of cases.

The majority of patients presented with swelling (42.3%) and they presented within 6 months of presentation of symptoms.

In our study, we found that seminoma had raised LDH (S2 according to CAP) and germ cell tumors had raised LDH and raised AFP (S2 according to CAP).

Radiological diagnosis was available for 41(78.8%) cases out of 52. Twenty-seven (68.9%) cases had radiological agreement with histopathology and 14(34.1%) cases had disagreement in such cases histopathological evaluation played a major role in giving the final confirmatory diagnosis.

The grading and staging of all the testicular tumors were done solely based on the recorded histopathological findings with reference to the latest AJCC guidelines ..

3. Discussion

Testis is affected by both non-neoplastic and neoplastic lesions. The present study helped us understand the variety of testicular lesions in patients presenting to our hospital. This study was undertaken to study testicular lesions for a period of two years. Fifty-two cases were included in the study. These cases were evaluated with different variables like age, gender, site, clinical presentation, and histological type.

A literature review of 11 original studies was done to evaluate the distribution of testicular lesions according to the various clinical and pathological aspects.

3.1. Age wise distribution of cases

According to age distribution, majority of cases belonged to 31 to 40 years of age group (26.9%). Mostly the presentation was in young patients aged <40 years (67.3%). This was consistent with studies conducted by Gargade et al.,⁷ Mansi Sharma et al.,⁸ Hemavathi Reddy et al.⁹ and Sundari et al.,¹⁰ who suggested that the maximum number of cases in their study belonged to <40 years age group.

3.2. Serum tumor markers and associated testicular lesions

In our study, we found that seminoma had raised LDH (S2 according to CAP) and germ cell tumors had raised LDH and raised AFP (S2 according to CAP) which is in accordance with the International Germ Cell Consensus Classification.

3.3. Comparison of spectrum of lesions in testis

Out of 52 cases studied, 34 (65.4%) were non-neoplastic Testicular lesions.

31 to 40 years was the common age group presented with non-neoplastic Testicular lesions (23.5%). (Table 2)

Gargade et al.,⁷ Mansi Sharma et al.⁸ and Sheeja S. et al.¹¹ also reported that non-neoplastic lesions were more common than neoplastic ones and younger age presentation was also in agreement. However, in contrary to our study, Gaikwad et al.¹² and Tekumalla A. et al.¹³ reported older age presentation of non- neoplastic testicular lesions.

In our study, 31 to 40 years was the common age group for neoplastic testicular (50%). (Table 1) This was in agreement with various studies Gargade et al.⁷ Tekumalla et al.¹³ and Mansi Sharma et al.⁸

The most common neoplastic Testicular lesion studied in our study was mixed germ cell tumor (75%).(Table 3) This is consistent with the study conducted by Sheeja et al.¹¹ The most common neoplastic testicular lesion studied in other studies were mostly seminoma.^{7,8,12,13}

The most common non-neoplastic testicular lesion was torsion testis (27.3%) followed by cryptorchidism (18.2%).Table 3 This is consistent with studies conducted by Gargade et al.⁷ and Sheeja et al.¹¹ who also reported torsion of testis as commonest non-neoplastic lesion. Other non-neoplastic lesions reported by Tekumalla et al.,¹³ Gaikwad et al.¹² and Mansi Sharma et al.⁸ were epididymo-orchitis, testicular atrophy, undescended testis respectively. (Table 3)

3.4. Microscopic findings

The commonest non-neoplastic lesion was testicular torsion followed by cryptorchidism.

We reported 9 cases of mixed germ cell tumor which showed typical histo-morphological features (Figure 1), along with 2 cases of seminoma which displayed classical

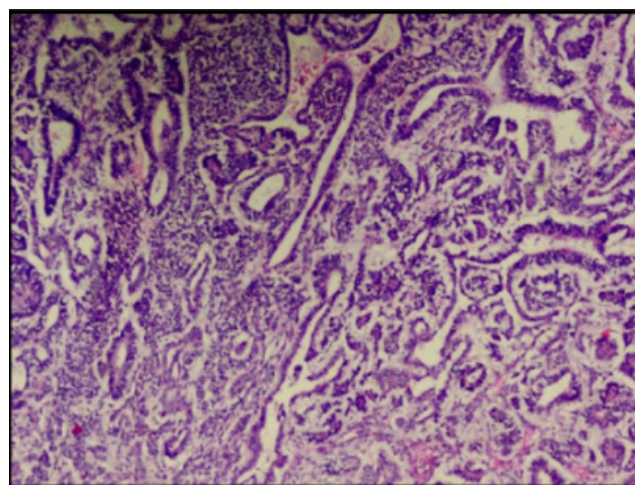


Fig. 1: (H&E 4X) Non seminomatous mixed germ cell tumor showing tumor cells arranged in glandular pattern.

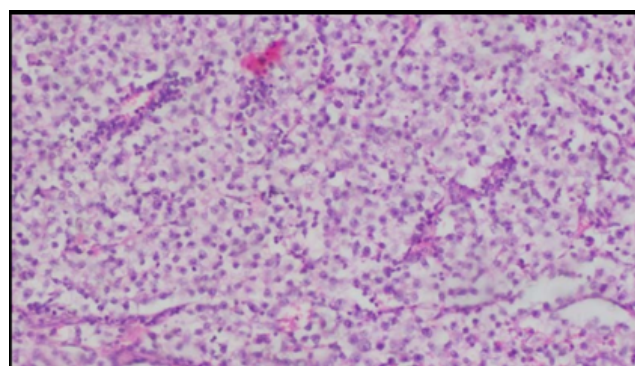


Fig. 2: (H & E 40x): Classical seminoma showing tumor cells with intervening fibrous septa and lymphocytic infiltrate.

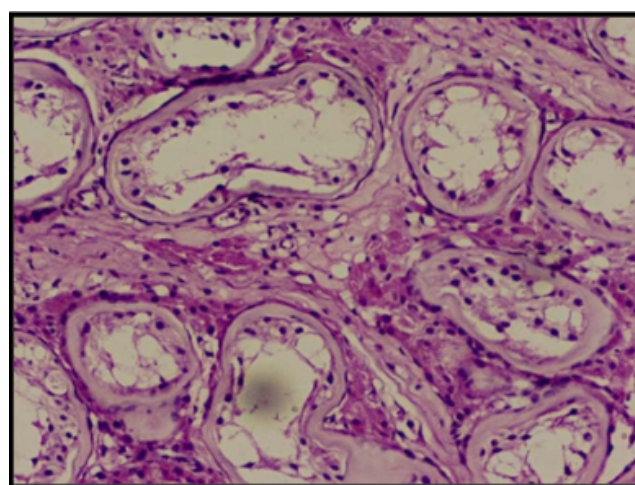


Fig. 3: (H & E 10x) Undescended testis showing peritubular fibrosis

Table 1: Common presenting age group for neoplastic testicular lesions observed in our study

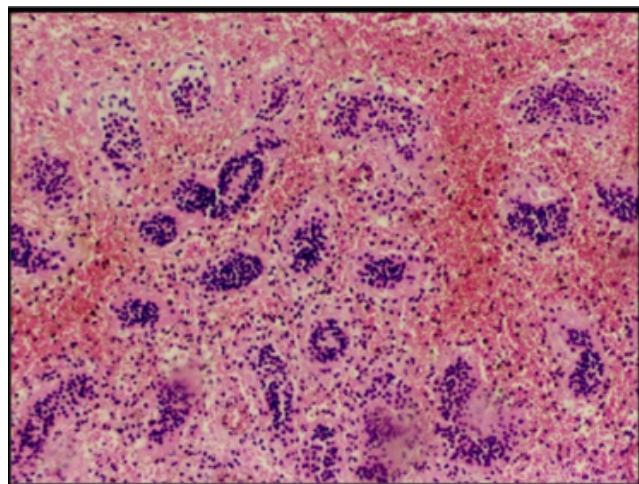
	Our Study (2021)
Neoplastic lesions	23.1%
Age group	31-40(50%)

Table 2: Common presenting age group for non-neoplastic testicular lesions observed in our study

	Our Study (2021)
Non-Neoplastic lesions	65.4%
Age group	31 to 40(23.5%)

Table 3: Most common Testicular lesions observed in our study

	Our Study (2021)
Most common non- neoplastic Testicular lesion	Torsion testis (27.3%)
Most common neoplastic Testicular lesion	Mixed germ cell tumor (75%)

**Fig. 4:** (H & E 4x) Testicular torsion with intratesticular hemorrhage.

histopathological features (Figure 2). Similarly, lesions like undescended testis (Figure 3) or testicular torsion (Figure 4) also showed characteristic features, confirming the clinical diagnosis.

4. Conclusion

Non-neoplastic testicular lesions were more common than neoplastic lesions.

The commonest non-neoplastic lesion was testicular torsion followed by cryptorchidism. The average age of presentation was in the age group of 31 to 40 years of age.

Scrotal swelling was the most common presenting complaint. Thus, non-neoplastic lesions appeared to be clinically mimicking neoplastic lesions.

Neoplastic testicular lesions formed a minority of all cases with Germ cell tumors forming the bulk of testicular tumors.

Histopathological evaluation plays a significant role in forming an accurate diagnosis and also contributes to the grading and staging of testicular tumors to help with the adequate treatment modality. In case of acute conditions like acute epididymo-orchitis and torsion testis, the accurate histopathological finding can help plan the patient management and predicting the prognosis.

In spite of the advances in the various investigative modalities including imaging studies and tumor marker assay, histopathological evaluation is the gold standard in confirming the clinical diagnosis and in grading and staging of testicular tumors. Testicular tumors show varied histological presentations thus, posing a challenge in forming a specific pathological diagnosis that holds paramount significance in the management of the patient.

5. Conflicts of Interest

The authors declare that there are no conflicts of interest regarding the publication of this paper.

6. Source of Funding

None.

References

1. Rosai J. Male Reproductive System in Rosai and Ackermans Surgical Pathology. 10th Edn. vol. 1. Elsevier; 2011. p. 1335–6.
2. Scott K. Testicular Cancer. *Am Family Physician*. 1999;59(9):2539–50.
3. Reddy H, Chawda H, Dombale VD. Histomorphological analysis of testicular lesions. *Indian J Pathol Oncol*. 2016;3(4):558–63.
4. Plataras C, Alexandrou I, Bourikis G, Bourikas D, Christianakis E. An extremely rare case of indirect hernia type co-existing with testicular ectopia. *Pan Afr Med J*. 2020;35:119. doi:10.11604/pamj.2020.35.119.21129.
5. Sharma M, Mahajan V, Suri J, Kaul K. Histopathological spectrum of testicular lesions- A retrospective study. *Indian J Pathol Oncol*. 2017;4(3):437–41.

6. Badmos KB. Tuberculous epididymo-orchitis mimicking a testicular tumour: a case report. *Afr Health Sci.* 2021;12(3):395–7. doi:10.4314/ahs.v12i3.26.
7. Gargade C, Deshpande A. Non-Neoplastic Testicular and Paratesticular Lesions Study from A Remote Indian Island. *Ann Pathol Lab Med.* 2020;7(4):186–93.
8. Sharma M, Mahajan V, Suri J, Kaul KK. Histopathological spectrum of testicular lesions-A retrospective study. *Indian J Pathol Oncol.* 2017;4(3):437–41.
9. Reddy H, Chawda H, Dombale VD. Histomorphological analysis of testicular lesions. *Indian J Pathol Oncol.* 2016;3(4):558–63.
10. Devi T, Nirmala BV, Srivani N, Kumar OS. Spectrum of orchidectomy lesions:5 year study. *J Evid Based Med Healthcare;*2015(2):3880–2.
11. Sheeja S. Histomorphological analysis of testicular and paratesticular lesions - 4 year study from a tertiary centre in South India. *J Med Sci Clin Res.* 2020;8(01). doi:10.18535/jmscr/v8i1.12.
12. Sheela LG, and PPS. Clinico-pathological study of testicular and paratesticular lesions. *Int J Contemp Med Res.* 2017;4(3):610–3.
13. Tekumalla A, Ragi S, Thota R. Histopathological analysis of testicular lesions- a three year experience in a tertiary care center Telangana. *Trop J Path Micro.* 2019;5(5):260–8.

Author biography

Surabhi Arun Vidhale, Senior Resident

Pragati Upasham, Professor

Cite this article: Vidhale SA, Upasham P. Surgico-pathological analysis of testicular lesions. *IP Arch Cytol Histopathology Res* 2021;6(4):250-254.