

Content available at: <https://www.ipinnovative.com/open-access-journals>

IP Archives of Cytology and Histopathology Research

Journal homepage: <https://www.achr.co.in/>

Case Report

Xanthomatous meningioma, a rare histological variant: Case report

Ninad R Patil¹, Manjul Tripathi¹, Sonikpreet Aulakh², Nirmalya Banerjee³, Aravind Sekar³, Aman Batish¹, Chiraj Kamal Ahuja⁴, Sandeep Mohindra^{1,*}

¹Dept. of Neurosurgery, Post Graduate Institute of Medical Education & Research, Chandigarh, India

²Dept. of Translational Neuro-Oncology, West Virginia University Cancer Institute, USA

³Dept. of Histopathology, Post Graduate Institute of Medical Education & Research, Chandigarh, India

⁴Dept. of Radiodiagnosis, Post Graduate Institute of Medical Education & Research, Chandigarh, India



ARTICLE INFO

Article history:

Received 23-07-2021

Accepted 20-08-2021

Available online 02-12-2021

Keywords:

Meningioma

Metaplasia

Radiology

ABSTRACT

Xanthomatous meningioma is a WHO grade I metaplastic meningioma where neoplastic cells contain lipid-filled vacuolated cytoplasm. The origin of xanthomatous meningiomas is believed to be from meningeothelial cells but diagnosis remains difficult because of their close resemblance with the histiocytes. Peculiar radiographic features may aid in diagnosis, however, definitive diagnosis requires immunohistochemical staining. We report a case of 43-year-old male with sphenoid wing meningioma revealing xanthomatous changes and received treatment as grade 1 meningioma. Though the exact pathophysiology remains unknown, we believe focal or gross metaplastic changes lead to transformation of tumor cells into the xanthomatous subtype. Authors discuss this interesting a rare histologic variant with discussion of the relevant literature.

This is an Open Access (OA) journal, and articles are distributed under the terms of the [Creative Commons Attribution-NonCommercial-ShareAlike 4.0 License](https://creativecommons.org/licenses/by-nc-sa/4.0/), which allows others to remix, tweak, and build upon the work non-commercially, as long as appropriate credit is given and the new creations are licensed under the identical terms.

For reprints contact: reprint@ipinnovative.com

1. Introduction

Meningiomas are the most common primary intracranial tumor comprising approximately 33.8% of all Cranial Nervous System (CNS) tumors.¹ Currently, 15 different histological subtypes are known, and been categorized into WHO grade I, II and III.² Grade I constitute approximately 65-85% of all meningiomas.³ Metaplastic meningioma is WHO grade I, which includes tumors containing different mesenchymal tissues i.e. osseous, cartilaginous, lipomatous, myxoid, or xanthomatous material.⁴ Metaplasia is defined as “reversible transformation of one cell type into another different mature cell type”. Xanthomatous meningioma is a rare variant of metaplastic meningioma, which shows predominant xanthomatous tumor cells having central nucleus with vacuolated cytoplasm distributed in focal or

diffuse pattern.

2. Case Report

A 43-year-old man presented with signs and symptoms of raised intracranial pressure. MRI brain was suggestive of 5.0 X 5.0 cm well circumscribed T1-hypo to isointense, T2-iso to hyperintense, heterogeneously contrast enhancing lesion with dural tail and attachment along the right sphenoid wing with mass effect. There was patchy T1 hyperintensity within the tumor. There were signs of raised intracranial pressure in the form of prominent perioptic CSF space, tortuosity of the optic nerve sheath and flattening of the optic nerve head (Figure 1A). There was tentorial thickening with tumor extension medially causing compression and distortion of the right cerebral peduncle and midbrain (Figure 1B). It was labeled as right sphenoid wing meningioma and underwent surgical excision.

* Corresponding author.

E-mail address: sandeepneuro@gmail.com (S. Mohindra).

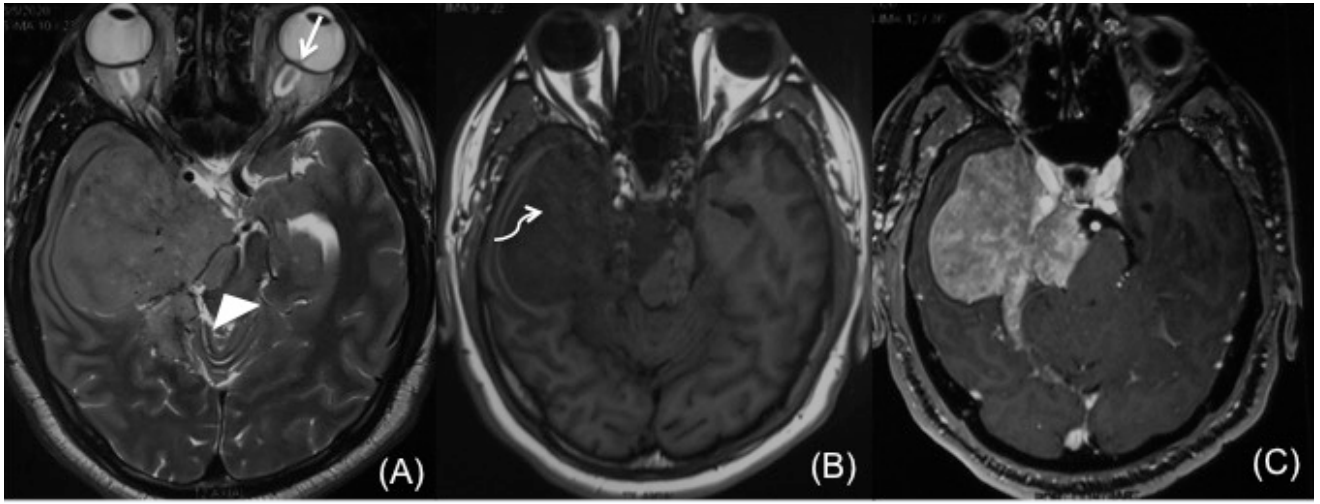


Fig. 1:

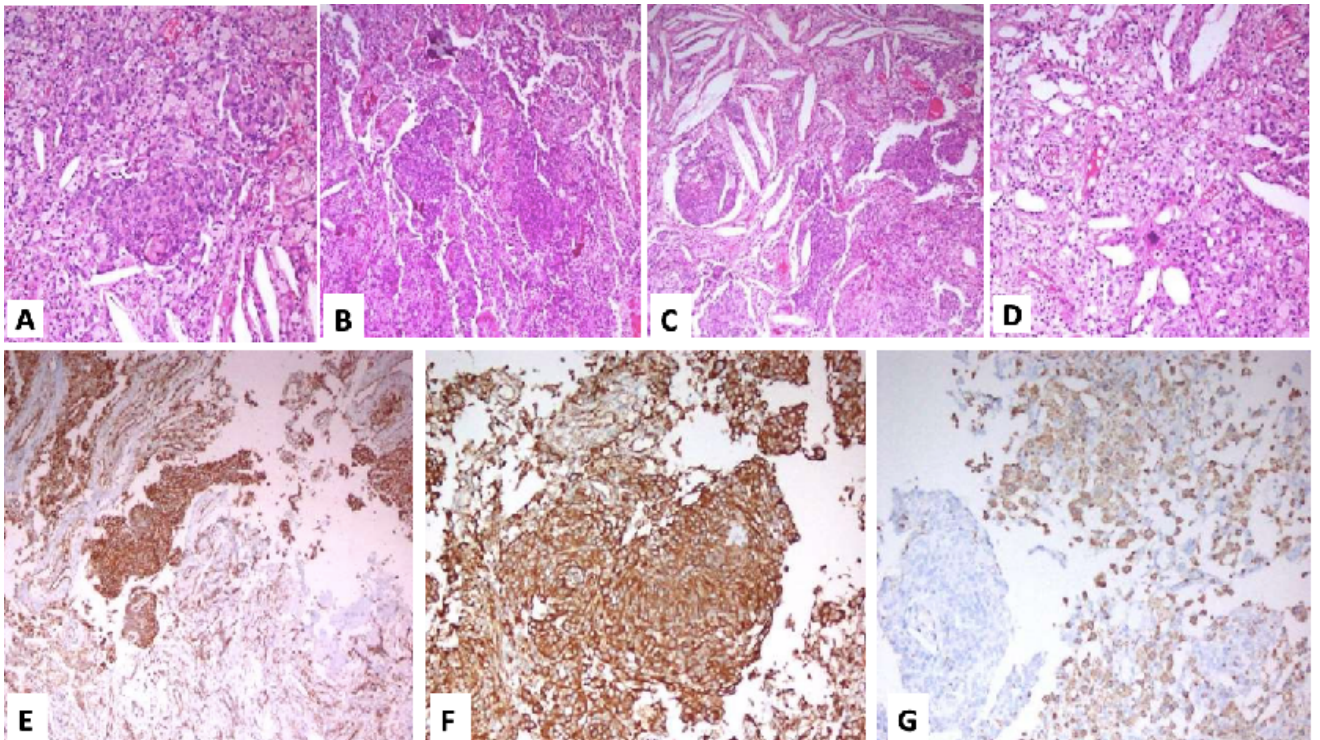


Fig. 2: A-G

Table 1: Literature review of Xanthomatous meningioma (CE, Contrast enhancement; EMA, Epithelial membrane antigen; GFAP, Glial fibrillary acidic protein; NA, not available; PAS, Periodic-Acid Schiff)

Author	Age (years)	Sex	Location	IHC	Radiological findings
Chougule et al. (2015) ⁵	24	Female	Supratentorial + infratentorial	EMA(+) PAS(-) Ki-67(3.2%)	Heterogeneously CE
Ersoz et al. (2019) ⁶	32	Male	supratentorial	EMA(+), adipophilin(+), CD68(+), Ki-67(3%), CEA(-), S-100(-), GFAP(-)	T1 isointense, T2 heterogenous, weakly CE, lobulated
Germanò et al. (1996) ⁷	2	Female	Infratentorial	EMA(+), VIMENTIN (+), PAS(-), GFAP(-), S-100(-)	Homogenously CE
Ikota et al. (2008) ⁴	61	Female	Supratentorial	EMA(+), vimentin(+), histiocytic markers(+), Ki-67(2.2%)	Weakly CE
Tang et al. (2012) ⁸	22	Male	Supratentorial	EMA(+), vimentin(+), GFAP(-), Ki-67 (< 1%)	NA
Tang et al. (2012) ⁸	68	Male	Supratentorial	EMA(+), vimentin(+), GFAP(-), Ki-67 (< 1%)	NA
Ishida et al. (2013) ⁹	76	Male	Supratentorial	EMA(+), CD68(+), vimentin(+), lysozyme(+), adipophilin(+), Ki-67 (2.1%)	NA
Kepes JJ (1994) ¹⁰	24	Male	Supratentorial	Vimentin(+), HAM-56(+), CD68(+)	NA
Ijiri et al. (2000) ¹¹	10	Male	Supratentorial	CD68(+), Sudan III(+), vimentin(+), Ki-67 (< 5%), GFAP(-), CAM 5.2(-)	NA
Liu et al. (2014) ¹²	55	Female	Supratentorial	EMA(+), CD68(+), S-100 (scattered +), Ki-67 (1.6%)	NA
Roncaroli et al. (2001) ¹³	58	Female	Supratentorial	EMA(+), vimentin(+), S-100(-), Ki-67 (< 5%)	NA

Continued on next page

<i>Table 1 continued</i>					
Roncaroli et al. (2001) ¹³	27	Female	Infratentorial	EMA(+), vimentin(+), S-100(-), Ki-67 (< 5%)	NA
Roncaroli et al. (2001) ¹³	59	Female	Supratentorial	EMA(+), vimentin(+), S-100(-), Ki-67 (< 5%)	NA
Roncaroli et al. (2001) ¹³	70	Female	Supratentorial	EMA(+), vimentin(+), S-100(-), Ki-67 (< 5%)	NA
Roncarol et al. (2001) ¹³	49	Female	Supratentorial	EMA(+), vimentin(+), S-100(-), Ki-67 (< 5%)	Plaque like appearance
Roncaroli et al. (2001) ¹³	12	Female	Supatentorial	EMA(+), vimentin(+), S-100(-), Ki-67 (< 5%)	NA
Wong et al. (2018) ²	83	Female	Supratentorial	EMA(+), PR(+), vimentin (+), S-100(+), CD68(+), CD11c(+), p53 (weak+), CK(-), CD34(-), Ki-67 (< 1%)	Isointense, heterogeneously contrast enhancing
Present case	43	Male	Supratentorial	EMA(+), CD68(+)	Well circumscribed T1-hypointense, T2-iso to hyperintense, heterogeneously contrast enhancing lesion with dural tail and attachment along the right sphenoid wing

Neurohistological examination showed two different cell lineages admixed with each other. It revealed nodules of classical meningothelial cells with round to oval nuclei, and bland chromatin (Figure 2A-C). There are variable sized nodules of tumor cells with syncytial pattern of arrangement. Typical whirling pattern is also noted (Figure 2 B). Intermixed among these nodules of tumor cells, second type of cells are noted. These are lipid filled foamy histiocytes or xanthomatous cells with interspersed needle shaped cholesterol cleft (Figure 2C). Xanthomatous cells show vacuolated cytoplasm with central nucleus. Occasional multinucleated giant cells were also present along with the histiocytes (Figure 2D). On immunohistochemistry analysis, meningothelial cells show strong Epithelial Membrane Antigen (EMA) positivity. Xanthomatous cells also show focal positive reactivity for EMA in the background. CD68 immunoreactivity is only shown by xanthomatous cells while meningothelial cells remain nonreactive (Figure 2E).

3. Discussion

In 1994, Kepes described the first case of Xanthomatous meningioma.¹⁰ The tumor is reported in a wide range of age group from children to elderly patients and can be localized in supratentorial or infratentorial regions without any specific predilection (6) (Table 1).²⁻¹³

On MRIs of the brain, these metaplastic meningiomas are usually iso- to hypointense on T1 and iso- to hyperintense on T2 weighted MRI. Katayama et al reported evidence of hyperintense lobules on both T1 and T2 weighted MRI images, and hypodensity on CT of the brain in xanthomatous meningiomas. These findings suggest high lipid content in the tumor.¹ Metaplastic meningiomas typically inculcate histopathological features of their transformed tumor subtype.¹⁴ Xanthomatous changes may also occur as primary xanthomatosis in hypercholesterolemia or as secondary xanthomatosis in neoplasm or inflammatory conditions (Figure 2A, B). Xanthomatous meningiomas show focal or diffuse xanthomatous changes in them along with meningothelial tumor cells. Meningothelial and transitional variants often show fat accumulation whereas neoplastic cells in xanthomatous meningiomas are filled up with lipids appearing as foamy cell with cholesterol clefts (Figure 2C).² Macrophages surround these neoplastic transformed cells, hence it is essential to carefully establish the origin of these xanthomatous cells. Xanthomatous meningioma does not show inflammation and is different from xanthogranulomatous inflammatory changes.⁴

Immunohistochemistry may help in differentiating xanthomatous cells from macrophages. Xanthomatous cells resemble macrophages but show EMA staining, suggesting meningothelial origin. EMA negative cells are believed to be macrophages that have migrated due to tumor

degeneration (Fig 2E,F).⁶ High CD68 expression could also be a characteristic feature due to abundant intracytoplasmic lysosomes in these malignant cells (Fig 2G).⁴ Furthermore, desmosomal and hemidesmosomal junctions, which create a “jigsaw puzzle” between adjacent neoplastic cells is highly suggestive of meningothelial origin of xanthomatous cells.^{2,15} In these tumors, xanthomatous areas stain negative for glial fibrillary acidic protein (GFAP) and stain positive for adipophilin, an antibody suggesting the presence of cytoplasmic lipid granules.⁹

Although exact pathophysiology behind these tumor is not known, Ishida et al. suggested metabolic abnormality in tumor cells resulting in xanthomatous changes.⁹ Ijiri et al reported radiation associated xanthomatous meningioma in a 10-year-old-boy who received radiation for intracranial ependymoma at the age of 2 years.¹¹ Taraszewska et al reported rare xanthomatous phenomenon in atypical and anaplastic meningiomas.¹⁵ Wong et al suggested that instead of actual histiocytic metaplasia, degenerative processes in tumors itself result in these xanthomatous changes.²

The differential diagnosis of xanthomatous meningioma include lipomatous meningioma, microcystic meningioma, and clear cell meningiomas. Lipomatous meningioma show mature adipocytes juxtaposed to neoplastic cells. Microcystic meningiomas can be differentiated by abundant cystic spaces formed by meningothelial cells. Clear cell meningioma show stromal and perivascular collagen unlike xanthomatous meningiomas.^{2,6}

4. Conclusion

Xanthomatous cells originate from meningothelial cells as shown by the immunohistochemical profile of the cells. It suggests true metaplasia of neoplastic cells into xanthomatous cells. Macrophage migration into tumor is due to the degenerative/inflammatory process within tumor cells, and its distinction from xanthomatous cells is crucial for the correct diagnosis and timely management.

5. Conflicts of Interest

The authors declare that there are no conflicts of interest regarding the publication of this paper.

6. Source of Funding

None.

References

1. Katayama Y, Tsubokawa T, Tanaka A, Koshinaga M, Nemoto N. Magnetic resonance imaging of xanthomatous meningioma. *Neuroradiology*. 1993;35(3):187–9.
2. Wong YP, Tan GC, Kumar R. Xanthomatous meningioma: A metaplastic or degenerative phenomenon? . *Neuropathology*. 2018;38(6):619–23.

3. Rogers L, Barani I, Chamberlain M, Kaley TJ, Mcdermott M, Raizer J, et al. Meningiomas: knowledge base, treatment outcomes, and uncertainties. A RANO review. *J Neurosurg*. 2015;122(1):4–23.
4. Ikota H, Nakazato Y. A case of metaplastic meningioma with extensive xanthomatous change. *Neuropathology*. 2008;28(4):422–6.
5. Chougule M, Pawar V, Chivte S, Jagtap S. Xanthomatous meningioma - a rare case report. *Int J Health Sci Res*. 2015;5(3):445–8.
6. Ersoz S, Yilmaz S, Eyuboglu Z, Yazar I, U. Xanthomatous meningioma: a case report. *Turkish Neurosurg*. 2016;doi:10.5137/1019-5149.JTN.19561-16.1.
7. Germanò A, Galatioto S, Rosa GL, Caffo M, Cardia E. Xanthomatous posterior pyramid meningioma in a 2-year-old girl. *Child's Nervous System*. 1997;13(7):406–11.
8. Tang H, Sun H, Chen H, Gong Y, Mao Y, Xie Q, et al. Clinicopathological analysis of metaplastic meningioma: report of 15 cases in Huashan Hospital. *Chin J Cancer Res*. 2013;25(1):112–8.
9. Ishida M, Fukami T, Nitta N, Iwai M, Yoshida K, Kagotani A, et al. Xanthomatous meningioma: a case report with review of the literature. *Int J Clin Exp Pathol*. 2013;6(10):2242–6.
10. Kepes JJ. Lipidized Meningothelial Tumor Cells in “Xanthomatous” Meningioma Express Macrophage Antigen. *J Neuropathol Exp Neurol*. 1994;53(4):384–8.
11. Ijiri R, Tanaka Y, Hara M, Sekido K. Radiation-associated xanthomatous meningioma in a child. *Child's Nervous Syst*. 2000;16(5):304–8.
12. Liu L, Stone J, Hoffpauir JT, Xiong Z. Histiocytic meningioma: A distinctive subtype of meningioma? *Intractable Rare Dis Res*. 2014;3(2):57–9.
13. Roncaroli F, Scheithauer BW, Laeng RH, Cenacchi G, Abell-Aleff P, Moschopoulos M, et al. Lipomatous Meningioma: A Clinicopathologic Study of 18 Cases With Special Reference to the Issue of Metaplasia. *Am J Surg Pathol*. 2001;25(6):769–75.
14. Choi YH, Choi CY, Lee CH, Koo HW, Chang SH. Metaplastic Meningioma Overspreading the Cerebral Convexity. *Brain Tumor Res Treat*. 2018;6(2):97–100. doi:10.14791/btrt.2018.6.e17.
15. Taraszewska A, Matyja E, Bogucki J. Xanthomatous changes in atypical and anaplastic meningiomas. Light and electron microscopic investigations. *Folia Neuropathol*. 2000;38(3):125–34.

Author biography

Ninad R Patil, Senior Resident

Manjul Tripathi, Associate Professor

Sonikpreet Aulakh, Assistant Professor

Nirmalya Banerjee, Senior Resident

Aravind Sekar, Assistant Professor

Aman Batish, Senior Resident Fellow

Chiraj Kamal Ahuja, Assistant Professor

Sandeep Mohindra, Additional Professor

Cite this article: Patil NR, Tripathi M, Aulakh S, Banerjee N, Sekar A, Batish A, Ahuja CK, Mohindra S. Xanthomatous meningioma, a rare histological variant: Case report. *IP Arch Cytol Histopathology Res* 2021;6(4):305-310.