



Original Research Article

Varied presentation of post Covid mucormycosis in a tertiary care centre in Northern India

Neda Ahsan¹, Mazhar Fahim¹, Fatma Lubna¹, Zohra Nahid Hashmi¹, Saquib Anwer¹, Kafil Akhtar^{1,*}

¹Dept. of Pathology, Jawaharlal Nehru Medical College, AMU, Aligarh, Uttar Pradesh, India



ARTICLE INFO

Article history:

Received 29-01-2022

Accepted 01-02-2022

Available online 04-03-2022

Keywords:

Covid19

Mucormycosis

Post covid treatment

SARSCoV2 Infection

ABSTRACT

Aims and Objectives: To study the cytomorphological presentation of post covid mucormycosis.

Materials and Methods: A retrospective observational study was conducted at a tertiary care center in Northern India for a period of six months, in patients with post covid mucormycosis.

Results: The study included 50 cases with post covid mucormycosis. Males with 28 cases (56.0%) were more commonly affected than females. Nose comprising of 36 cases (72.0%) was the most commonly affected area, with nasal cavity showing 24 cases (48.0%) being most common site within the nose. 36 cases (72.0%) were positive exclusively for Mucormycosis. 10.0% cases of mucor showed superadded bacterial infection. Candida was seen in 03 cases (6.0%) and aspergillosis in 02 cases (4.0%). There were 6.0% cases of mucormycosis with associated chronic osteomyelitis. All the patients had a history of steroid use throughout their coronavirus treatment.

Conclusions: A rare but fatal fungal infection (mucormycosis) has a strong association with covid-19 infection, in active as well as recovered patients, particularly in those with co-morbid medical conditions and treated with high doses of corticosteroids.

This is an Open Access (OA) journal, and articles are distributed under the terms of the [Creative Commons Attribution-NonCommercial-ShareAlike 4.0 License](https://creativecommons.org/licenses/by-nc-sa/4.0/), which allows others to remix, tweak, and build upon the work non-commercially, as long as appropriate credit is given and the new creations are licensed under the identical terms.

For reprints contact: reprint@ipinnovative.com

1. Introduction

Coronavirus disease 2019 (Covid-19) is an infection caused by severe acute respiratory syndrome (SARS-CoV-2). The Covid-19 symptom have increased since the initial days of the disease's presentation, to begin with it included only dry cough and high grade fever, however it now includes varied multisystemic problems as well. It has also been associated with a wide range of opportunistic bacterial and fungal infections.¹

Several cases of Covid related mucormycosis have been emerging world-wide, particularly from India. The primary reason thought to be facilitating Mucorales spores to germinate in covid patients is an ideal environment of

high glucose (diabetes, new-onset hyperglycaemia, steroid-induced hyperglycaemia), low oxygen, increased levels of ferritin, acidic medium (metabolic acidosis, diabetic ketoacidosis), and decreased phagocytic activity of white blood cells due to immunosuppression combined with considerable other shared risk factors including prolonged hospitalization with or without mechanical ventilators.²

Mucormycosis is a rare yet fatal fungal infection affecting patients with weakened immunity. Patients include those with uncontrolled diabetes mellitus, acquired immunodeficiency syndrome, iatrogenic immunosuppression and haematological malignancies, and those who have undergone organ transplantation.³

Rhizopus Oryzae, a filamentous microfungus, belonging to the family Mucoraceae, is known to be the most common type, accountable for approximately 60.0% of

* Corresponding author.

E-mail address: drkafilakhtar@gmail.com (K. Akhtar).

mucormycosis cases in humans and is also responsible for 90.0% of the Rhino-orbital-cerebral (ROCM) form.⁴ Here the mode of contamination occurs through inhalation of fungal spores.

The characteristic features of mucormycosis includes the presence of hyphal invasion of sinus tissue and a duration of less than four weeks.^{5,6} Clinically, it can present with few atypical signs and symptoms like complicated sinusitis with crusting and nasal blockade, proptosis, ptosis, facial pain and oedema, ophthalmoplegia with fever, headache and other neurological signs and symptoms if intracranial extension is present.^{7,8} A black eschar may be seen in the nasal cavity or over the hard palate region, but is not characteristic.⁹

A rapid progression of the disease is seen without prompt intervention. Sometimes, even after swift diagnosis, treatment, aggressive medical and surgical intervention, management is often ineffective, resulting in an extension of the infection and ultimately death.¹⁰ Here, we present our recent experience of 50 cases of mucormycosis seen over a time period of just six months in Covid-19 positive cases.

2. Materials and Methods

A retrospective observational study was undertaken at Jawaharlal Nehru Medical College, AMU, Aligarh, India, over a period of six months, from May to November 2021 in 50 clinically suspected cases of rhino-orbital mucormycosis received in the Department of Pathology.

The samples were received in normal saline and crush/imprint smears were prepared and stained with H&E, PAP and PAS stains for rapid evaluation. The patient's presentation details, imaging findings, co-morbidities, management details and follow-up information were obtained, recorded and analysed.

3. Results

Our study included a total of 50 cases of Mucormycosis. The most common age group of presentation was bimodal between 31–40 and 51–60 years, with 15 cases (30.0%) in each decade. Males comprised 28 cases (56.0%) and 22 cases (44.0%) were females (Tables 1 and 2).

Table 1: Age wise distribution of cases

Age Group	Number of Cases	Percentage
10 – 20 years	0	0
21 – 30 years	02	4.0
31 – 40 years	15	30.0
41 – 50 years	09	18.0
51 – 60 years	15	30.0
61 – 70 years	07	14.0
71 – 80 years	02	4.0

Nose seemed to be the most common site for the development of Mucormycosis, comprising of 36 cases (72.0%), followed by maxilla with 06 cases (12.0%). Within

Table 2: Gender-wise distribution of cases

Gender	Number of Cases	Percentage
Male	28	56.0
Female	22	44.0

Table 3: Site of occurrence of infection

Site	Number of Cases	Percentage
Axillary Sinus	01	2.0
Maxilla	06	12.0
Bone	01	2.0
Eye	04	8.0
Nose	36	72.0
Jaw	01	2.0
Teeth and Gums	01	2.0

Table 4: Most common site of occurrence within the Nose

Site in the Nose	Number of Cases	Percentage
Nasal Cavity	24	48.0
Anterior Turbinate	06	12.0
Middle Turbinate	12	24.0
Inferior Turbinate	08	16.0

the Nose, Nasal cavity showed the maximum number of cases with 24 (48.0%), while the anterior turbinate was least favourable with only 06 cases (12.0%) (Tables 3 and 4).

Table 5: Cytomorphological findings

Cytomorphological findings	Number of Cases	Percentage
Mucormycosis	36	72.0
Mucormycosis with superadded bacterial infection	05	10.0
Mucormycosis with Candida	03	6.0
Mucormycosis with Aspergillosis	02	4.0
Mucormycosis with Chronic Osteomyelitis	03	6.0

On Cytology, of all the patients showing positivity, 36 cases (72.0%) were positive exclusively for Mucormycosis, with thick broad aseptate hyphae and spores (Figure 1).

Candida was seen in 03 cases (6.0%) and aspergillosis in 02 cases (4.0%), with acute angle septate thin hyphae (Figure 2).

Three (6.0%) cases showed association with a superadded bacterial infection (Figure 3).

There were also 6.0% cases which were associated with chronic osteomyelitis (Table 5).

4. Discussion

The Covid-19 infection has been associated with a wide range of disease patterns, ranging from mild cough to life-threatening pneumonia.¹¹ Although, the chances of healthy individuals contracting mucormycosis is extremely rare, a

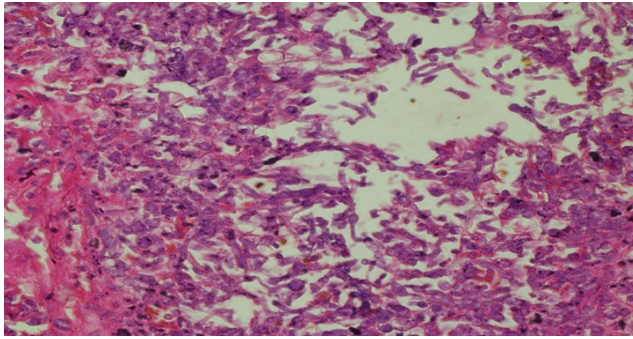


Fig. 1: Tissue section shows Mucormycosis, with thick broad aseptate hyphae and spores. Haematoxylin and Eosin x40X.

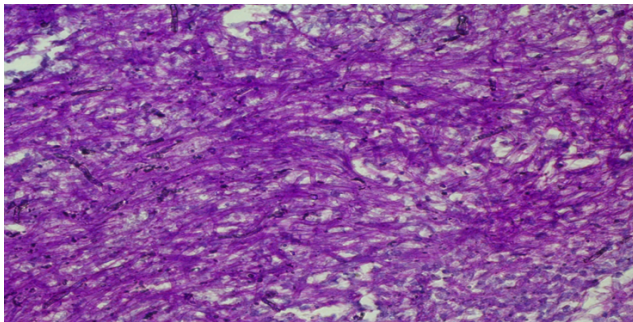


Fig. 2: Section shows aspergillosis infection, with acute angle branching septate thin hyphae. PAS x40X.

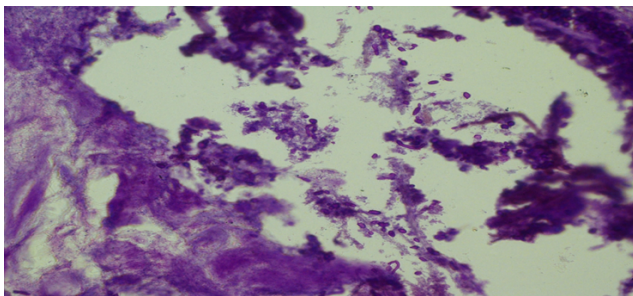


Fig. 3: Smear shows mucor with hyphae and spores with superadded bacterial infection. PAS x40X.

complex interplay of factors such as diabetes mellitus, use of immunosuppressive therapy, previous respiratory disorders risk of hospital-acquired infection can lead to secondary infections.¹²

The sites favoured by mucormycosis may includes nose, sinuses, orbit, CNS, GIT, lung, jaw, heart and mediastinum, however ROCM is considered to be the most common variety seen world-wide.¹³ Here, ROCM refers to the entire spectrum ranging from limited sino-nasal disease (tissue invasion), limited rhino-orbital disease (progression to orbits) to rhino-orbital-cerebral disease (CNS involvement).¹³

On microbiological examination, mucormycosis hyphae can be differentiated from other fungal infections based on the diameter, branching angle (right or acute branching), presence or absence of septa and pigmentation. Smith and Krichner¹⁴ in 1950 laid out the criteria for clinical diagnosis of mucormycosis including: (i) Blood-tinged nasal discharge and facial pain, both on the same side, (ii) Black, necrotic turbinate's easily mistaken for dried, crusted blood, (iii) Ptosis of the eyelid, proptosis of the eyeball and complete ophthalmoplegia (iv) Soft peri-orbital or peri-nasal swelling with discoloration and induration and (v) Multiple cranial nerve palsies unrelated to documented lesions.

Patel et al conducted a study in June 2021 with 465 cases of Mucormycosis without covid-19 and showed that rhino-orbital presentation was most commonly seen (67.7%), followed by pulmonary presentation (13.3%) and cutaneous type (10.5%). Among Indians, diabetes mellitus (73.5%), malignancy (9.0%) and organ transplantation (7.7%) were the most common predisposing factors for the development of disease.¹⁵

Song et al. conducted a study in April 2020 where the association between Covid-19 and invasive fungal sinusitis was examined which led to the conclusion that a large number of patients affected by or recovered from Covid-19 are at an increased risk of developing invasive fungal diseases.¹⁶ Another study conducted by White et al. comprising of 135 adults with Covid-19 infection, reported an incidence of 26.7% for invasive fungal infections.¹⁷ In a recent review, 8.0% of coronavirus-positive or recovered patients had secondary bacterial or fungal infections during hospital admission, with widespread use of broad-spectrum antibiotics and steroids.^{18,19}

Ideally, surgical debridement of the infected area should be performed as soon as possible once the diagnosis is confirmed. Although surgery alone is reported not to be curative, an aggressive surgical approach has been shown to improve survival.²⁰ Amphotericin-B deoxycholate remains the anti-fungal treatment of choice to start, with its liposomal preparations preferred because of decreased nephrotoxicity. Prognosis remains poor even with aggressive surgery and intravenous anti-fungal therapy, with reported mortality rates of 33.3–80 per cent, going up to 100 per cent in disseminated infections.²¹

5. Conclusions

Covid-19 is associated with a significant incidence of secondary infections both bacterial and fungal due to weakened/altered immunity. Additionally, the rampant use of corticosteroids and high prevalence of diabetes in India are two of the main factors aggravating the illness. If infected, early surgical intervention and intravenous anti-fungal treatment is the current mainstay for management, with a good prognosis and less severe disease course in

cases of post-coronavirus mucormycosis.

6. Conflict of Interest

The authors declare that there is no conflict of interest.

7. Source of Funding

None.

References

- Sharma S, Grover M, Bhargava S, Samdani S, Kataria T. Post coronavirus disease mucormycosis: a deadly addition to the pandemic spectrum. *J Laryngol Otol.* 2021;135(5):442–7.
- Singh AK, Singh R, Joshi SR, Misra A. Mucormycosis in COVID-19: A systematic review of cases reported worldwide and in India. *Diabetes Metab Syndr.* 2021;15(4):102146. doi:10.1016/j.dsx.2021.05.019.
- Seppanen EJ, Thornton RB, Corscadden KJ, Granland CM, Hibbert J, Fuery A, et al. High concentrations of middle ear antimicrobial peptides and proteins and proinflammatory cytokines are associated with detection of middle ear pathogens in children with recurrent acute otitis media. *PLoS One.* 2019;14(12):e0227080. doi:10.1371/journal.pone.0227080.
- Ferguson BJ. Definitions of fungal rhinosinusitis. *Otolaryngol Clin North Am.* 2000;33(2):227–35. doi:10.1016/s0030-6665(00)80002-x.
- Chakrabarti A, Denning DW, Ferguson BJ, Ponikau J, Buzina W, Kita H, et al. Fungal rhinosinusitis. *Laryngoscope.* 2009;119(9):1809–18.
- Scheckenbach K, Cornely O, Hoffmann TK, Engers R, Bier H, Chaker A, et al. Emerging therapeutic options in fulminant invasive rhinocerebral mucormycosis. *Auris Nasus Larynx.* 2010;37(3):322–8.
- Vairaktaris E, Moschos MM, Vassiliou S, Baltatzis S, Kalimeras E, Avgoustidis D, et al. Orbital cellulitis, orbital subperiosteal and intraorbital abscess. *J Cranio-Maxillofac Surg.* 2009;37(3):132–6.
- Mohindra S, Mohindra S, Gupta R, Bakshi J, Gupta SK. Rhinocerebral mucormycosis: the disease spectrum in 27 patients. *Mycoses.* 2007;50(4):290–6.
- Gillespie MB, O'malley B. An algorithmic approach to the diagnosis and management of invasive fungal rhinosinusitis in the immunocompromised patient. *J Otolaryngol.* 2000;33(2):323–34.
- Mehta S, Pandey A. Rhino-orbital mucormycosis associated with covid-19. *Cureus.* 2020;12(9):e10726. doi:10.7759/cureus.10726.
- Chen N, Zhou M, Dong X, Qu J, Gong F, Han Y, et al. Epidemiological and clinical characteristics of 99 cases of 2019 novel coronavirus pneumonia in Wuhan, China: a descriptive study. *Lancet.* 2020;395(10223):507–13. doi:10.1016/S0140-6736(20)30211-7.
- Sugar AM. Mucormycosis. *Clin Infect Dis.* 1992;14(1):S126–9. doi:10.1093/clinids/14.supplement_1.s126.
- Peterson KL, Wang M, Canalis RF, Abemayor E. Rhinocerebral Mucormycosis: Evolution of the Disease and Treatment Options. *Laryngoscope.* 1997;107(7):855–62.
- Smith HW, Kirchner JA. Cerebral Mucormycosis: A Report of Three Cases. *Arch Otolaryngol.* 1958;68(6):715–26.
- Patel A, Kaur H, Xess I, Michael JS, Savio J, Rudramurthy S. A multicentre observational study on the epidemiology, risk factors, management and outcomes of mucormycosis in India. *Clin Microbiol Infect.* 2021;26(7):9–15.
- Song G, Liang G, Liu W. Fungal Co-infections Associated with Global COVID-19 Pandemic: A Clinical and Diagnostic Perspective from China. *Mycopathologia.* 2021;185(4):599–606.
- White PL, Dhillon R, Cordey A, Hughes H, Faggian F, Soni S, et al. A National Strategy to Diagnose Coronavirus Disease 2019-Associated Invasive Fungal Disease in the Intensive Care Unit. *Clin Infect Dis.* 2020;73(7):e1634–44. doi:10.1093/cid/ciaa1298.
- Rawson TM, Moore L, Zhu N, Ranganathan N, Skolimowska K, Gilchrist M, et al. Bacterial and Fungal Coinfection in Individuals with Coronavirus: A Rapid Review to Support COVID-19 Antimicrobial Prescribing. *Clin Dis.* 2020;71(9):12–8.
- Elinav H, Zimhony O, Cohen MJ, Marcovich AL, Benenson S. Rhinocerebral mucormycosis in patients without predisposing medical conditions: a review of the literature. *Clin Microbiol Infect.* 2009;15(7):693–7.
- Spellberg B, Walsh TJ, Kontoyiannis DP, Edwards JJ, Ibrahim AS. Recent Advances in the Management of Mucormycosis: From Bench to Bedside. *Clin Infect Dis.* 2009;48(12):1743–51.
- Jung SH, Kim SW, Park CS, Song CE, Cho JH, Lee JH. Rhinocerebral Mucormycosis: Consideration of prognostic factors and treatment modality. *Auris Nasus Larynx.* 2009;36(3):274–9.

Author biography

Neda Ahsan, Junior Resident

Mazhar Fahim, Junior Resident

Fatma Lubna, Junior Resident

Zohra Nahid Hashmi, Junior Resident

Saqib Anwer, Junior Resident

Kafil Akhtar, Professor  <https://orcid.org/0000-0002-3482-1195>

Cite this article: Ahsan N, Fahim M, Lubna F, Hashmi ZN, Anwer S, Akhtar K. Varied presentation of post Covid mucormycosis in a tertiary care centre in Northern India. *IP Arch Cytol Histopathology Res* 2022;7(1):16-19.