

Content available at: <https://www.ipinnovative.com/open-access-journals>

IP Archives of Cytology and Histopathology Research

Journal homepage: <https://www.achr.co.in/>

Letter to Editor

Proliferative myositis

Samira Kumar Behera¹, Shushruta Mohanty¹, Lipika Behera¹,
Meenakshi Mohapatra^{1,*}

¹Dept. of Pathology, M.K.C.G Medical College, Behampur, Odisha, India



ARTICLE INFO

Article history:

Received 24-01-2022

Accepted 28-01-2022

Available online 04-03-2022

This is an Open Access (OA) journal, and articles are distributed under the terms of the [Creative Commons Attribution-NonCommercial-ShareAlike 4.0 License](#), which allows others to remix, tweak, and build upon the work non-commercially, as long as appropriate credit is given and the new creations are licensed under the identical terms.

For reprints contact: reprint@ipinnovative.com

Dear Sir,

Proliferative myositis is a benign reactive rapidly growing pseudosarcomatous lesion that infiltrates skeletal muscle in diffuse manner.¹ It is characterised by fibroblastic proliferation with atypical giant cells mimicking ganglion cells. It is skeletal muscle counterpart of proliferative fasciitis which arises from superficial fascia and is relatively superficial in location, however both these entities resembles histologically with each other. It most commonly affects age group over 45yrs of age but also known to occur in childrens too.² Most common sites of predilection are skeletal muscles of shoulder, thorax and thigh but is also known to be reported at unusual sites such as tongue and oral cavity.³⁻⁵ Histopathology is gold standard in confirming the diagnosis as clinical findings are non specific.

A 42yrs. male presented with an irregular, slow growing, painless swelling measuring 3x2 cms in the lateral aspect of the thigh since 3 months. The skin over the swelling was normal. There was no history of trauma. FNAC from the swelling showed a cellular smear comprising of good number of spindle cell clusters admixed with myofibroblasts and few giant cells resembling ganglion cells (Figure 1a-c). A provisional diagnosis of proliferative myositis was rendered with an advise for biopsy. The lesion

was excised and was send to our lab for histopathological analysis. Grossly we received multiple grey white fragments altogether measured 2.5 x2 cm. Histopathology showed a poorly circumscribed lesion comprising of plump fibroblast and myofibroblasts surrounding individual muscle fibres creating a checker board pattern (proliferative fibroblasts alternating with atrophic muscle) along with bizzare giant cells resembling ganglion cells that have abundant amphophilic to basophilic cytoplasm vesicular nuclei and prominent nucleoli. Stroma is collagenous to myxoid (Figure 2a-c). Variable mitotic figures may be seen. Final diagnosis of proliferative myositis was given.

Proliferative Myositis (PM) was first described by Kern in the year 1960.¹ Proliferative myositis should be considered in the differential diagnosis of a rapidly growing soft tissue (in particular intramuscular) mass. It's a benign pseudo sarcomatous inflammatory process that may clinically mimic malignancy. Various theories are postulated regarding etiology of PM but a history of recent trauma was noticed in some cases.⁶ Other potential causes that were also proposed includes ischemia, vasculitis, and chromosomal abnormalities.⁶ Two classical features of proliferative myositis that are seen in histopathology: firstly a) infiltration of the muscle with large eosinophilic giant cells that resemble ganglion cells and secondly b) proliferative fibroblasts-like primarily affecting the interfascicular connective tissue. It is this pattern of normal muscle fascicles interspersed with infiltrating fibrous

* Corresponding author.

E-mail address: drmeenakshi1988@gmail.com (M. Mohapatra).

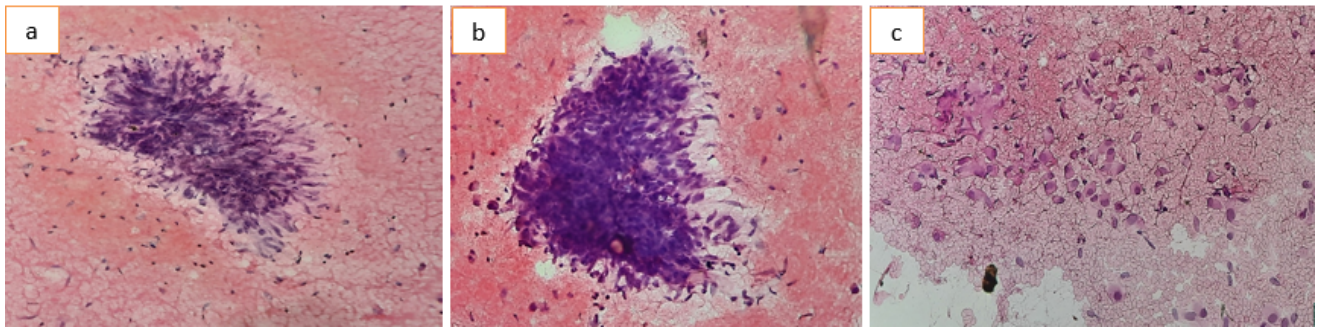


Fig. 1: **a:** LP 100x FNAC; **a-b:** LP 100x FNAC – good number of spindle cells admixed with myofibroblasts; **c:** FNAC 100x–showing presence of ganglion cells.

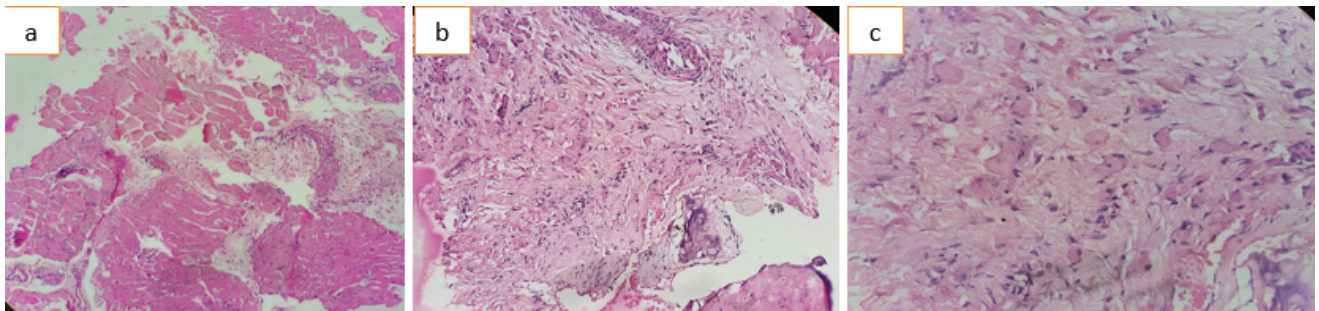


Fig. 2: **a:** Histopathology LP 100x- Plump fibroblast and myofibroblast surrounding and splitting the individual muscle fibre forming “Checker board pattern”; **b:** Histopathology Scanner view 40x showing ganglion cells in collagenous stroma; **c:** Histopathology LP 100x –showing ganglion cells(black arrow) with abundant amphophilic to basophilic cytoplasm, vesicular nuclei and prominent nucleoli.

tissue that leads to the classic “checkerboard” pattern of proliferative myositis.⁶

IHC profile of proliferative myositis is similar to that of nodular fasciitis and proliferative fasciitis. Fibroblasts are mostly positive for vimentin and SMA but negative for desmin suggesting its myofibroblastic nature. Ganglion like cells are negative or focally positive for SMA.⁷⁻⁹ The important differential diagnosis includes a large category of benign sarcomatous lesions that includes Nodular fasciitis and proliferative fasciitis. Ganglioneuroblastoma and Rhabdomyosarcoma are other differentials that need to be mentioned. Nodular fasciitis completely obliterates muscle when extends deeper than fascia and is histologically characterized by areas abundant in myxoid stroma with inflammatory infiltration but with absence of ganglion cells. Proliferative fasciitis is almost identical to proliferative myositis except that it is subcutaneous rather than intramuscular in location. Ganglioneuroblastoma shows IHC positivity to S100 but was ruled out in view of lack of fibrillary background and SMA negative ganglion cells.⁷ Sudden onset and rapid growth rate of proliferative myositis brings Rhabdomyosarcoma as one of the differentials, which on IHC is usually desmin and myogenin positive. The rhabdomyoblast of Rhabdomyosarcoma have some

resemblance to that of ganglion cells of Proliferative myositis, however the ganglion cells of proliferative myositis lack cross striations and are more basophilic than rhabdomyoblasts. Sometimes presence of metaplastic bone in histopathology may mimic myositis ossificans. However myositis ossificans exhibit characteristics ossification in the lesion that can be picked up in imaging MRI enhancement and peripheral calcification in the subacute stage.

Due to its benign nature and potential for spontaneous resolution a wait and watch strategy is preferred for Proliferative Myositis. The mass is known to grow rapidly in initial phase where it closely mimicks a sarcoma but however stabilises after a few weeks. No evidence of malignancy or metastasis has been reported till date.¹⁰ Wide local excision is reserved in those cases where it causes compression symptoms or affects patients day to day life.

Conflict of Interest

The authors declare that there is no conflict of interest.

Source of Funding

None.

References

1. Kern WH. Proliferative myositis: a pseudosarcomatous reaction to injury. *Arch Pathol.* 1960;69:209–16.
2. Meis JM, Enzinger FM. Proliferative fasciitis and myositis of childhood. *Am J Surg Pathol.* 1992;16(4):364–72. doi:10.1097/00000478-199204000-00005.
3. Enzinger FM, Dulcey F. Proliferative myositis: Report of 33 cases. *Cancer.* 1967;20(12):2213–23. doi:10.1002/1097-0142(196712)20:12<2213::aid-cnrcr2820201223>3.0.co;2-1.
4. Dent CD, Deboom GW, Hamlin ML. Report of a case and review of the literature. *Oral Surg Oral Med Oral Pathol.* 1994;78(3):354–8. doi:10.1016/0030-4220(94)90068-x.
5. Brooks JK, Scheper MA, Kramer RE, Papadimtriou JC, Sauk JJ, Nikitakis NG, et al. Intraoral proliferative myositis: Case report and review of literature. *Head Neck.* 2007;29(4):416–20. doi:10.1002/hed.20530.
6. Shi J, Lewis M, Walsworth MK, Modaresi S, Masih S, Chow K, et al. Proliferative myositis. *Appl Radiol.* 2018;47(1):43–5.
7. Brook JS. Immunohistochemistry of proliferative myositis. *Arch Pathol Lab Med.* 1981;105(12):682.
8. Weiss SW, Goldblum JR. Weiss and Enzinger Soft tissue tumors. 5th Edn. USA: Mosby; 2008. p. 192–3.
9. El-Jabbour JN, Bennett MH, Burke MM, Lessels A, O'halloran A. Proliferative myositis- an immunohistochemical and ultrastructural study. *Am J Surg Pathol.* 1991;15(7):654–9. doi:10.1097/00000478-199107000-00006.
10. Fauser C, Hrig J, Niedermeyer HP, W A. Proliferative myositis a rare pseudomalignant tumor of the head and neck. *Arch Otolaryngol Head Neck Surg.* 2008;134(4):437–40. doi:10.1001/archotol.134.4.437.

Author biography

Samira Kumar Behera, Associate Professor

Shushruta Mohanty, Assistant Professor

Lipika Behera, Assistant Professor

Meenakshi Mohapatra, Assistant Professor

Cite this article: Kumar Behera S, Mohanty S, Behera L, Mohapatra M. Proliferative myositis. *IP Arch Cytol Histopathology Res* 2021;7(1):78-80.