

Content available at: <https://www.ipinnovative.com/open-access-journals>

IP Archives of Cytology and Histopathology Research

Journal homepage: <https://www.achr.co.in/>

## Original Research Article

# Diagnosis of invasive Mucormycosis on Histopathological examination at a tertiary referral hospital

Laxmi Pravalika<sup>1</sup>, Pavani Marapaka<sup>1,\*</sup><sup>1</sup>Dept. of Pathology, Kamineni Academy of Medical Sciences and Research and Centre, Hyderabad, Telangana, India

## ARTICLE INFO

## Article history:

Received 12-01-2022

Accepted 21-01-2022

Available online 29-06-2022

## Keywords:

Post covid status

Mucormycosis

Early diagnosis

Histopathological examination

## ABSTRACT

**Background and Objective:** This study is conducted with an aim to Diagnosis of invasive Mucormycosis on Histopathological examination at a tertiary referral hospital. Rhino cerebral Mucormycosis is the current life-threatening infection commonly affecting immunocompromised patients especially post COVID-19 within 6 weeks having poor glycemc control, Intravenous drug users, ICU patients, post chemotherapy, iron overload, persistent neutropenia and follow-up cases of hematological malignancies. It affects the nasal and paranasal sinuses by air-borne spores producing the infection. A prospective case series conducted at the department of pathology, KAMSRC 'between' May 1<sup>st</sup> to September 30th 2021 with a study population of 27 cases. Variables included age, gender, and history of covid, duration and development of symptoms, Clinical presentation, clinical diagnosis, co-morbidities, histopathological examination and microbiological correlation. The most prevalent isolated agent is Mucor (48.1%) followed by Rhizopus (18.5%), Aspergillus (11.1%) and mixed mucor with aspergillus (11.1%).

**Materials and Methods:** A prospective case series conducted at the department of pathology, KAMSRC, reported 27 cases of post covid-19 Mucormycosis aged 30-68 years. Clinical features at presentation included unilateral facial pain with proptosis (80%), loss of vision, headache, nasal crusting, Cough with dyspnea and mild fever. All cases were admitted in ICU with severity in symptoms with 7 deaths recorded during treatment (25.9%).

**Results:** Immunofluorescence with Robin blue/Calcofluor white stain for fungal elements was also combined to highlight Mucor species. Fungal cultures were diagnostic for fungal elements obtained after 48hrs on Sabouraud's/Potato dextrose agar (SDA/PDA). Three cases were negative for fungal elements with only dense mixed inflammatory infiltrate admixed necrosis. Correlation with KOH mount & fungal culture on SDA/PDA showed 13 cases of mucor, 5 cases of rhizopus, 3 cases of aspergillus & 2 cases of mucor with aspergillus growth, 3 cases were negative with no fungal growth. Also correlated with the microbiology department where nasal crusting and nasal tissue was obtained for fungal elements for KOH wet mount and fungal culture. KOH wet mount microscopy revealed Broad aseptate hyphae with wide angle branching suggestive of Mucormycosis. Simultaneous analytical study of CBP showed raised total WBC counts in 4 individuals (19,620-24,670 cumm) with others having normal CBC. CRP was in the range of 32-68mg/dl with ESR 35-98 mm/hr.

**Conclusion:** Understanding the mechanism of host innate immunity and specific preventive strategies are important for favorable prognosis. Histopathological examination aids in early diagnosis of Mucormycosis.

This is an Open Access (OA) journal, and articles are distributed under the terms of the [Creative Commons Attribution-NonCommercial-ShareAlike 4.0 License](https://creativecommons.org/licenses/by-nc-sa/4.0/), which allows others to remix, tweak, and build upon the work non-commercially, as long as appropriate credit is given and the new creations are licensed under the identical terms.

For reprints contact: [reprint@ipinnovative.com](mailto:reprint@ipinnovative.com)

## 1. Introduction

Mucor is the most common genus causing human mucormycetes in most cases followed by rhizopus &

\* Corresponding author.

E-mail address: [drpravalika.1990@gmail.com](mailto:drpravalika.1990@gmail.com) (P. Marapaka).

lichtheimia. It is associated with significant lymphopenia, long-term neutropenia, malnutrition, intravenous drug use and non-judicious use of corticosteroids.<sup>1</sup>

Zygomycosis referred to as Mucormycosis is caused by class phycomycetes. Mucormycosis commonly affects the nasal and paranasal sinuses, upper respiratory tract, lungs, angio-invasion and brain. Usually air-borne spores contaminate food and lab specimens producing infections. Mucor species include Mucor, Rhizopus, Rhizomucor, Lichtheimia, Cunninghamella.

Mucorales hyphae are non-septate or pauci-septate with a variable width of 6-16microns. To confirm the diagnosis tissue sections are stained with Hematoxylin & Eosin (H & E), PAS and GMS stain.<sup>1</sup> Patients present with clinical features of Periorbital edema, blurring of vision, nasal/paranasal congestion, crusting, dyspnea, cough, mild fever.<sup>2</sup> There are reports of cases in literature with mucormycosis in poorly controlled diabetes mellitus while post covid invasive mucormycosis is the subject of interest due to its aggressive invasiveness & rapid mortality.<sup>3</sup> Increase in the fungal biomass due to implanted fungal spores in the oral & nasal mucosa is the probable mode of infection thus influencing PMNs damage.<sup>4</sup>

Early clinical and lab diagnosis is the need of the hour with rational use of antifungal and broad spectrum antimicrobial treatment. Poor prognosis is indicated in cases with Iron overload & persistent neutropenia.<sup>5</sup> Mortality accounts to 30-70% due to angioinvasion with complete cut off of blood supply, thrombosis, tissue infarction & extensive necrosis.<sup>3,5</sup>

Imaging findings on MRI with contrast gadolinium scan shows hyperdense foci within left ethmoid and sphenoid sinuses with orbital extension.<sup>6</sup> Microscopic examination shows respiratory epithelial lining with stroma showing fungal elements in the form of broad aseptate hyphae with wide angle branching, fungal granulomas, foreign-body giant cells dense mixed inflammatory infiltrate with predominant eosinophils and neutrophils admixed areas of necrotic tissue. Gomori's silver methenamine stain highlights black pigmented Broad aseptate hyphae. Additional confirmatory method by Immunofluorescence with Robin blue/Calcofluor white stain for fungal elements also reveals Mucor species.

Fungal cultures are diagnostic for fungal elements obtained after 48hrs on Sabouraud's/Potato dextrose agar.

The present study aims to Evaluate histopathological diagnosis and microbiological evidence in clinically diagnosed mucormycosis in post covid patients.

## 2. Materials and Methods

A prospective case series conducted at the department of pathology, KAMSRC between May 1<sup>st</sup> to September 30th, 2021 reported 27 cases of post covid-19 Mucormycosis aged 30-68 years. Clinical features at presentation included

unilateral facial pain with proptosis (80%), loss of vision, headache, nasal crusting, Cough with dyspnea and mild fever. All cases were admitted in ICU with severity in symptoms with 7 deaths recorded during treatment (25.9%).

### 2.1. Data collection

Initial data regarding the patient details- Age, gender, clinical presentation, history of covid, duration and development of symptoms, diagnosis, other comorbidities, imaging findings, microbiological culture report and histopathological examination & correlation were collected.

### 2.2. Statistical data

Qualitative variables were described in numbers and percentages and Quantitative variables as mean and standard deviation.

## 3. Results

The age range was 30-68 years with a mean age of 49 years. In the current study, Male: Female ratio was 7:2 that is males were 21(77.7%) and females were 6 (22.2%) (Table 1).

Before mucormycosis was identified history of COVID was seen in all the 27 cases and history of diabetes was present in 17 (62.9%) with 6 young patients (22.2%) developing denovo DM. 15 patients (55.5%) were on oral/IV steroids with hyperbaric oxygen therapy.

The most common clinical presentation was unilateral facial pain with proptosis (80%) followed by loss of vision, headache and nasal crusting.

**Table 1:** Characteristics of data collected

Gender	n
Male	21
Female	6
Age (in years)	
30-39	6
40-49	13
50-59	5
60-69	3

The minimum time interval between post COVID and clinical presentation of symptoms of mucormycosis is 2-3 weeks. Maximum number of cases were noted in the 3-4 weeks. No cases were recorded immediately after COVID recovery (Figure 2).

On Imaging, 18 cases showed non-enhancement of (avascular) left half of medial & superior nasal turbinates with mucosal thickening. Four cases showed left cavernous sinus involvement with bony erosions & enlarged masticatory muscles [Figure 1].

The most prevalent factors were poorly controlled diabetes mellitus, oral/intravenous steroids, raised serum ferritin, IV drugs in ICU patients, Steroid therapy and

**Table 2:** Time interval of development of mucormycosis post COVID

	Time interval of mucormycosis Post covid	No. of cases
1	Immediately	0
2	2-3 weeks	4
3	3-4 weeks	21
4	>4 weeks	2

neutropenia (Table 3). Most cases had a history of type 2 diabetes mellitus while very few cases (n= 2/27) had neutropenia.

**Table 3:** Comorbidities causing immunocompromised state

S.No.	Comorbidities	No. of cases
1	Poorly controlled T2DM	23
2	IV drug therapy	15
3	Raised serum ferritin	15
4	History of ICU admission during COVID	27
5	Neutropenia	2
6	Steroid therapy	15

Commonest site for biopsy was from the nasal cavity followed by maxillary sinuses and ethmoid sinuses.

Grossly we received multiple grey white to brown soft tissue bits measuring 2x1 cm along with bony fragments (mostly from ethmoid sinus). All embedded in 2 tissue cassettes. Out of 27 cases sent for histopathology diagnosis, 13 cases (50%) showed broad aseptate and branching hyphae consistent with mucormycosis on H & E and GMS stain.

Histopathological examination (HPE) on hematoxylin and eosin stained (H & E) tissue sections showed broad, aseptate hyphae with irregular wide angle branching in 13 cases (48.1%) positive for invasive mucormycosis involving the ethmoid bone followed by 5(18.5%) positive for rhizopus, 3(11.1%) mixed mucor with aspergillus and 3(11.1%) of aspergillus. Also seen were dense inflammatory infiltrates composed of eosinophils, neutrophils, histiocytes, lymphocytes, Fungal granulomas and dense foci of necrosis [Figure 2].

**Table 4:** Microscopic results on histopathological evaluation with H & E stain

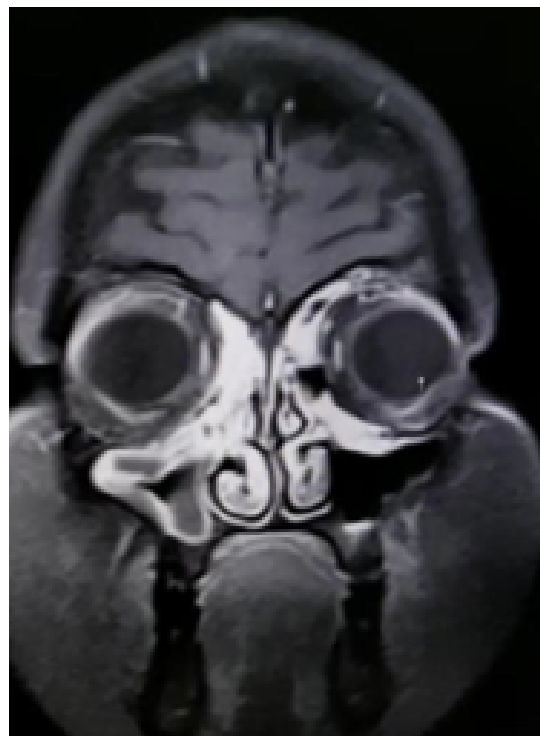S.No.	Impression	No. of cases
1	Mucor	13
2	Rhizopus	5
3	Mixed mucor and aspergillus	3
4	Aspergillus	3
5	Negative with only inflammation	3

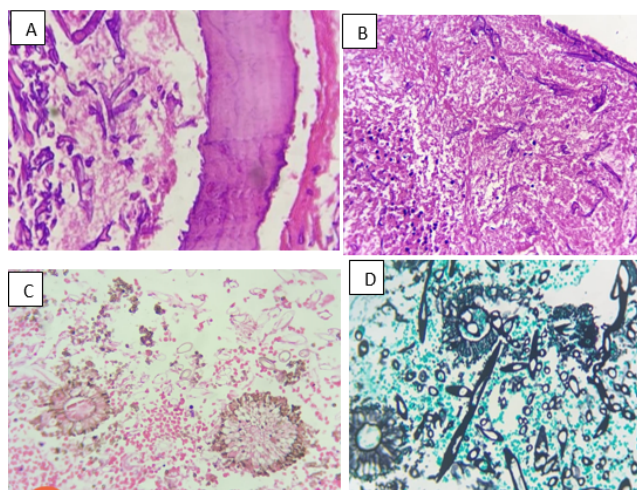
Table 4 shows Mucor is the most common etiological agent. KOH Wet mount study also correlated with HPE.

On Gomori's silver methenamine stain characteristic black pigmented broad aseptate hyphae few broken hyphae with wide angle branching were seen[Figure 3].

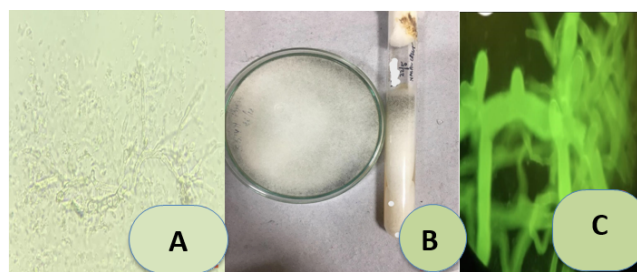
Immunofluorescence with Robin blue/Calcofluor white stain for fungal elements was also combined to highlight Mucor species. Fungal cultures were diagnostic for fungal elements obtained after 48hrs on Sabouraud's/Potato dextrose agar (SDA/PDA). Three cases were negative for fungal elements with only dense mixed inflammatory infiltrate admixed necrosis. Correlation with KOH mount & fungal culture on SDA/PDA showed 13 cases of mucor, 5 cases of rhizopus, 3 cases of aspergillus & 2 cases of mucor with aspergillus growth, 3 cases were negative with no fungal growth.

Also correlated with the microbiology department where nasal crusting and nasal tissue was obtained for fungal elements for KOH wet mount and fungal culture. KOH wet mount microscopy revealed Broad aseptate hyphae with wide angle branching suggestive of Mucormycosis. Simultaneous analytical study of CBP showed raised total WBC counts in 4 individuals (19,620-24,670 cumm) with others having normal CBC.CRP was in the range of 32-68mg/dl with ESR 35-98 mm/hr.

**Fig. 1:** MRI with contrast gadolinium showing hyper dense lesion in ethmoid & sphenoid sinuses with orbital extension.



**Fig. 2:** **A:** H & E (40X) shows broken broad aseptate hyphae invading the ethmoid bone; **B:** Fungal hyphae admixed inflammation & necrosis; **C & D:** Mixed mucor and aspergillus on H & E and GMS stains.



**Fig. 3:** **A:** Wet KOH mount shows Mucor; **B:** Fungal culture shows black fungal growth; **C:** Immunofluorescence shows fluorescent broad aseptate hyphae.

#### 4. Discussion

The global burden of mucormycosis is highest in India. Although it is extremely rare in healthy individuals but severely immunocompromised conditions predispose it. Rhino-orbital cerebral mucormycosis is an opportunistic fulminant invasive fungal infection with risk of angioinvasion leading to vascular thrombosis & tissue necrosis. Diabetes is the most common comorbidity in mucormycosis accounting to 73.5% in India.<sup>7</sup>

Most common presentation in our study was unilateral facial pain with proptosis in 80% patients. In the Badie et al study, the most common presentation was hematological disorders (57.2%) followed by diabetes (21.4%).<sup>4</sup>

In our study diabetes was associated with 85.1% (69.5% T2DM and 22.2% denovo DM). Our patients developed symptoms within 3-4 weeks of covid-19 positivity. Six young adults aged 30-37 years were diagnosed with denovo diabetes.

In Nashibi et al study (85%) and in Hammond et al (36%), diabetes mellitus was the most frequent underlying

disease.<sup>4</sup>

Mode of infection is the implantation of fungal spores in middle turbinate in persons with defective mucociliary transport which cause increase in fungal biomass. The host immune system and portal of fungal entry is responsible for the type of presentation. Recent studies have observed that COVID-19 infected patients who are treated with widespread broad spectrum antibiotics and steroid therapy recovered after secondary bacterial or fungal infections in 8%.<sup>7,8</sup>

The most common etiological agent in our study was mucor followed by rhizopus and aspergillus. The commonest fungi isolated in Prakash H et al was rhizopus (51.9%) followed by mucormycosis.<sup>9</sup>

MRI with contrast gadolinium allows better visualisation depending on the signal intensity due to uptake of iron, zinc and manganese by the fungal elements. Fungal hyphae involving nerves & vessel wall lead to extensive perineural & cavernous sinus invasion.<sup>6,10</sup> In our imaging study 18 cases showed non-enhancement of (avascular) half of medial & superior nasal turbinates with mucosal thickening.

Pathological hallmark of mucormycosis on HPE are the aseptate broad right or wide angle branching hyphae admixed eosinophilic necrosis, foreign body giant cells, invasion into adjacent bony fragments and angioinvasion.<sup>8,11</sup>

Increase in Mucormycosis in the Indian context appears to be due to the intersection of diabetes, rampant use of corticosteroids and covid-19 (Cytokine storm, lymphopenia endothelial damage).<sup>12,13</sup>

Microbiological evaluation with KOH Wet mount and Fungal cultures were done for all the cases. But culture is time consuming and needs 3-5 days for identification of isolated fungi and may be negative for few specimens. In a review of 929 cases on mucormycosis only 15% had positive culture results. In our study fungal cultures were negative in 3/27 cases (11.1%) and were delayed upto 5 days in 6/27 (22.2). Immunofluorescence study also correlated with HPE results.

Mortality rate in the current study was 25.9% (n=7/27) in a study period of 5 months. In a study conducted by Mishra et al, the mortality rate was 12.5% (n=4/32).<sup>9</sup> In review of literature the overall mortality of rhino cerebral mucormycosis in patients with DM was 40-50%.<sup>10,14,15</sup>

In Bhat et al in all the cases studied WBC count was increased but in our study only 4 showed increased WBC count.<sup>16</sup>

New strain of COVID is associated with increased mucormycosis due to poor glycemic control, probably due to ACE-2 receptor inhibition in pancreas and raised serum ferritin levels. Gold standard for diagnosis are Isolates of sterile samples sent for fungal culture & histopathology.<sup>11,17</sup> All mucorales grow rapidly 3-5 days on either Sabouraud or potato dextrose agar incubated

at 25–30 degrees centigrade.<sup>13,18</sup> A study by Jain et al reported a unique presentation of invasive gastrointestinal mesenteric mucormycosis resulting in mesenteric ischemia with bowel gangrene.<sup>19</sup> Our cases did not report any mesenteric ischemia or mucor. In a study by Salehi M et al, Formalin fixed samples have Sensitivity of 56% and specificity of 100%.<sup>20</sup>

## 5. Conclusion

Overall prognosis is poor if predisposing underlying disease cannot improve as surgical interventions are not feasible. Understanding the mechanisms of innate host response is important for favourable outcome. Preventative strategies need to be reinforced. ICMR recommended multidisciplinary team approach for early diagnosis and management is highlighted. No proven mucormycosis in asthmatics on inhaled corticosteroids. Although immunogenicity is attenuated, Vaccination is recommended for immunocompromised individuals. Histopathological examination and fungal culture are the gold standard tests for early diagnosis of mucormycosis.

## 6. Acknowledgements

I would like to express my special thanks to Dr. Vivekanand sir and Dr. Jakkula Vijay Rao garu for their valuable expert supervision, review and editing.

## 7. Conflict of Interest

The authors declare no relevant conflicts of interest.

## 8. Source of Funding

None.

## References

1. Sen M, Lahane S, Lahane TP, Parekh R, Honavar S. Mucor in a viral land: A tale of two pathogens. *Indian J Ophthalmol.* 2021;69(2):244–52. doi:10.4103/ijo.IJO\_3774\_20.
2. Sarkar S, Gokhale T, Choudhary SS, Deb AK. COVID-19 and orbital mucormycosis. *Indian J Ophthalmol.* 2021;69(4):1002–4. doi:10.4103/ijo.IJO\_3763\_20.
3. Mehta S, Pandey A. Rhino-orbital mucormycosis associated with covid-19. *Cureus.* 2020;12(9):10726. doi:10.7759/cureus.10726.
4. Badiie P, Jafarian H, Ghasemi F. Molecular epidemiology of zygomycosis and their related factors in tertiary referral centres in southern Iran. *J Infect Dev Ctries.* 2020;14(12):1424–30. doi:0.3855/jidc.12997.
5. Gangneux JP, Bougnoux ME, Dannanoui E, Cornet M, Zahar JR. Invasive fungal diseases during COVID-19: we should be prepared. *J Mycol Med.* 2020;30(2):100971. doi:10.1016/j.mycmed.2020.100971.

6. Lone PA, Wani NA, Jehangir M. Rhino-orbital-cerebral mucormycosis: Magnetic resonance imaging. *Indian J Otol.* 2015;21(3):215–8.
7. Mekonnen ZK, Ashraf DC, Jankowski T, Grob SR, Vagefi MR, Kersten RC, et al. Acute invasive rhino-orbital mucormycosis in a patient with COVID-19 associated acute respiratory distress syndrome. *Ophthalmic Plast Reconstr Surg.* 2020;37(2):e40–80. doi:10.1097/IOP.0000000000001889.
8. Rawson TM, Moore LSP, Zhu N, Ranganathan N, Skolimowska K, Gilchrist M, et al. Bacterial and fungal co-infections in individuals with coronavirus-A rapid review to support COVID-19. *J Clin Infect Dis.* 2020;71(9):2459–68. doi:10.1093/cid/ciaa530.
9. Prakash H, Ghosh AK, Rudramurthy SM, Singh P, Xess I, Savio J, et al. A prospective multicentre study on mucormycosis in India. *Med Mycol.* 2018;57(4):395–402. doi:10.1093/mmy/myy060.
10. Bhavani PN, Shivanand V, Satish D. Imaging findings of Rhino-Orbital-cerebral mucormycosis in a COVID-19 patient. *Eurorad.* 2021; Available from: <https://www.eurorad.org/case/17205>. doi:10.35100/eurorad/case.17205.
11. Spellberg B. Mucormycosis pathogenesis: beyond rhizopus. 2017;8(8):1481–2. doi:10.1080/21505594.2017.1364335.
12. Singh A, Singh R, Joshi SR. Mucormycosis in COVID-19 :A systematic review of cases reported worldwide and in India. *Clin Res Rev.* 2021;15(4):102146. doi:10.1016/j.dsx.2021.05.019.
13. Lackner M, Caramalho R, Lass-Flörl C. Laboratory diagnosis of mucormycosis: current status and future perspectives. *Future Microbiol.* 2014;9(5):683–95. doi:10.2217/fmb.14.23.
14. Ambrosioni J, Bouchuiguir-Wada, Garbino J. Emerging invasive mucormycosis in a tertiary care center. *Int J Infect Dis.* 2010;14(3):100–3.
15. Gupta A, Sharma A, Chakrabarti A. The emergence of post COVID-19 mucormycosis in India. *Indian J Ophthalmol.* 2021;69(7):1645–7.
16. Bhat A. Mucormycosis: the clinical spectrum. *Int J Adv Med.* 2018;5(6):1364–68.
17. Venkatesh D, Dandagi S, Chandrappa PR, Hema KN. Mucormycosis in immunocompetent patients resulting in extensive maxillary sequestration. *J Oral Maxillofac Pathol.* 2018;22(1):112–6. doi:10.4103/jomfp.JOMFP\_163\_17.
18. Rawson TM, Moore LS, Zhu N, Ranganathan N, Skolimowska K, Gilchrist M, et al. Bacterial and fungal co-infections in individuals with coronavirus-A rapid review to support COVID-19. *J Clin Infect Dis.* 2020;71(9):2459–68. doi:10.1093/cid/ciaa530.
19. Jain M, Tyagi R, Jain G, Tyagi R. Post COVID-19 Gastrointestinal invasive mucormycosis. *Indian J Surg.* 2022;84(3):545–7. doi:10.1007/s12262-021-03007-6.
20. Salehi M, Ahmadikia K, Badali H, Khodavaisy S. Opportunistic fungal infections in epidemic areas of COVID-19: A clinical and diagnostic perspective from Iran. *Mycopathologia.* 2020;185(4):607–11. doi:10.1007/s11046-020-00472-7.

## Author biography

**Laxmi Pravalika**, Final Year Pathology, Post Graduate

**Pavani Marapaka**, Student

**Cite this article:** Pravalika L, Marapaka P. Diagnosis of invasive Mucormycosis on Histopathological examination at a tertiary referral hospital. *IP Arch Cytol Histopathology Res* 2022;7(2):85–89.