

Content available at: <https://www.ipinnovative.com/open-access-journals>

IP Archives of Cytology and Histopathology Research

Journal homepage: <https://www.achr.co.in/>

## Case Report

# Cystic hygroma: Case report

Sapna S Deshpande<sup>1,\*</sup>, Vishrabdha Pawar<sup>1</sup>, AN Kurane<sup>2</sup>, Anushree Modi<sup>1</sup>

<sup>1</sup>Dept. of Pathology, D.Y. Patil Medical College, Kasba Bawda, Kolhapur, Maharashtra, India

<sup>2</sup>Dept. of Pediatrics, D.Y. Patil Medical College, Kasba Bawda, Kolhapur, Maharashtra, India



### ARTICLE INFO

#### Article history:

Received 21-02-2022

Accepted 07-05-2022

Available online 29-06-2022

#### Keywords:

Cystic hygroma

Cystic spaces

Bleomycin

Complications

### ABSTRACT

Cystic hygromas are the most common, cystic variety of lymphangioma, present at birth or period of infancy. Its common locations being cervico-facial regions and axilla. Respiratory distress, recurrent infections or cosmetic reasons are the main indications of the treatment. The ideal treatment is complete surgical excision; however, there is a gradual conversion towards sclerosant therapy.

This is an Open Access (OA) journal, and articles are distributed under the terms of the [Creative Commons Attribution-NonCommercial-ShareAlike 4.0 License](https://creativecommons.org/licenses/by-nc-sa/4.0/), which allows others to remix, tweak, and build upon the work non-commercially, as long as appropriate credit is given and the new creations are licensed under the identical terms.

For reprints contact: [reprint@ipinnovative.com](mailto:reprint@ipinnovative.com)

## 1. Introduction

Hygroma means water-containing tumour in Greek. It occurs due to congenital malformations of lymphatic system which account for 6% of all benign tumors of infancy and childhood. 50% of the cystic hygromas are present since birth and most of the remaining 50% appear by the age of 2-5 years.<sup>1</sup> Commonest site for cystic hygromas is the neck and lower part of the face, other sites are axilla, superior mediastinum, retroperitoneum, mesentery pelvis, and lower limbs.<sup>2</sup> Depending on anatomical site, they may cause dysphagia or airway obstruction and respiratory distress. Patient with cystic hygroma are frequently misdiagnosed as branchial cleft cysts.

Lymphangiomas are of three types, these are capillary, cavernous or cystic lymphangiomas. Cystic hygroma occurs more frequently and may compose of single or multiple macrocystic lesions having scarce communication with normal lymphatic channels.<sup>3</sup> On the basis of size of the cysts contained they are also classified as, as microcystic, macrocystic and mixed lymphangiomas.

Microcystic lymphangioma consists of cysts measuring less than 2 cm in size, whereas the size of cysts in case of macrocystic lymphangioma is more than 2 cm. The mixed lymphangioma is characterized by cysts of variable sizes, i.e. some cysts are more than 2 cm in size and others are less than 2cm.<sup>4,5</sup>

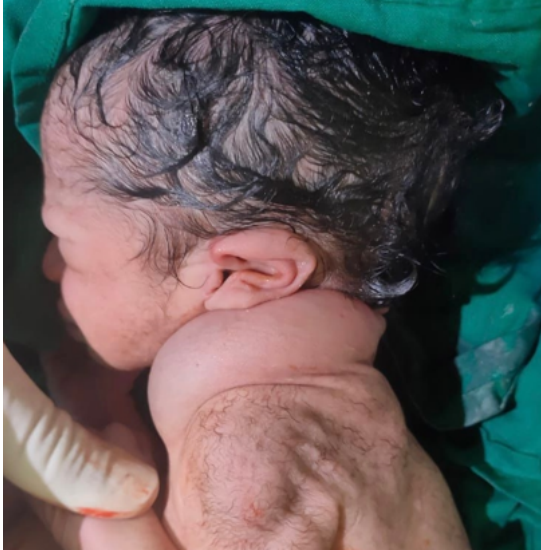## 2. Case Report

A male new born was born with left sided soft neck swelling. He was then referred to the paediatric department. On examination, the swelling was present over the region extending from carotid region to anterior mediastinum on the left side (Figure 1). The swelling was soft on palpation, with poorly defined margins, nontender and when subjected to light test was brilliantly translucent. On USG a large ill-defined superficial multicystic and multiseptate soft tissue lesion was identified on left side of neck which was extending from preauricular parotid region down to supraclavicular region as well as lower anterior midline neck suspecting large lymphangioma or cystic hygroma on the left side with midline intrathoracic extension along anterior mediastinum. He was operated at the age of 6 months. Surgeon removed the mass and sent the specimen

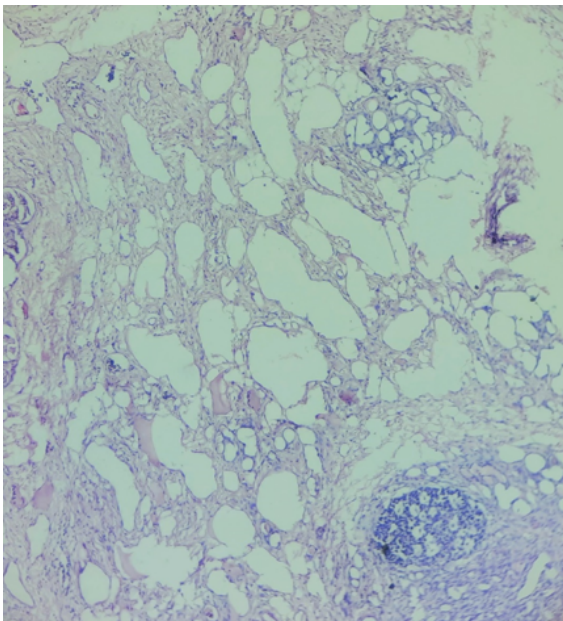
\* Corresponding author.

E-mail address: [drsapna.deshpande23@gmail.com](mailto:drsapna.deshpande23@gmail.com) (S. S. Deshpande).

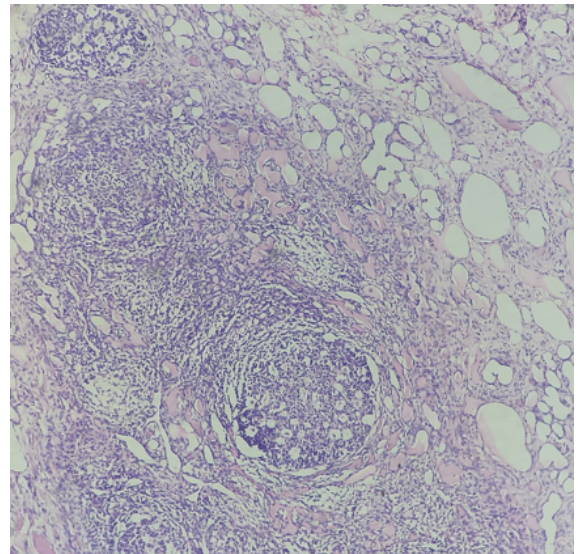
to histopathology. Gross finding of the mass showed two irregular soft tissue bits. External surfaces of both tissues were greyish brown, congested and with focal areas of hemorrhage. Microscopic findings were tissue composed of collection of cystic spaces lined by flattened epithelium. The stroma was loose connective tissues with collection of numerous lymphocytes. Adjacent tissue showed skeletal muscle fibers, lymphoid follicles and few seromucinous glands. (Figures 2, 3 and 4)



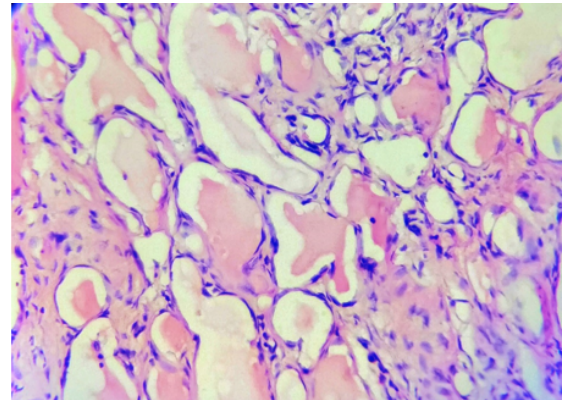
**Fig. 1:** Cystic swelling over left side of neck



**Fig. 2:** 10X H & E-Cystically dilated spaces lined by flattened epithelium. Loose connective tissue stroma shows few collection of lymphocytes.



**Fig. 3:** 10 X H & E- Dilated lymph spaces with collections of lymphocytes in adjacent edematous connective tissue



**Fig. 4:** 40X H & E-Cystically dilated spaces lined by flattened epithelium. Cystic spaces shows lymph and sparse lymphocytes. Connective tissue stroma shows collection of lymphocytes.

### 3. Discussion

Lymphangioma is congenital lymphatic malformations. Mostly all Lymphangiomas are detected before the age of two years. Histologically these lesions are composed of dilated lymphatic channels with one or two endothelial layers, with or without an adventitial layer. These dilated lymphatics can vary in size, depending upon the location and surrounding tissues.<sup>6</sup> The capillary variant is composed of small capillary sized lymphatics lined by endothelium, whereas cavernous type is made up of larger lymphatic channels with adventitial coats. Cystic types are multilocular masses, consist of large microscopic lymphatic spaces filled with clear or yellow lymph fluid. Cystic hygromas are deeply seated in areas of areola or loose connective tissues. They appear early in life as large soft

tissue masses on the axilla, neck or groin. They are soft and vary in size and shape.<sup>6</sup> Multilocular Cystic hygromas are inherited autosomal recessive disorders without any gender predominance. It's association with Turner syndrome, Noonan syndrome, chromosomal aneuploidy, trisomies, fetal alcohol syndrome, cardiac anomalies and fetal hydrops has been noted.<sup>7</sup> Lymphangioma can be diagnosed based on clinical symptoms, USG, MRI and biopsy (FNAC).<sup>8</sup> Few cases of congenital cystic hygroma were treated with intrauterine treatment without any complication of chromosomal abnormalities. Experimental OK-430 injection and sclerotherapy using special agents like bleomycin and doxycyclin are used to shrink the growth although it may require several injections.<sup>9</sup> Various studies suggest postnatal treatment of choice is complete excision with an extremely low mortality rate. Similar modality of treatment has been used in our case. After surgical excision there are few complications like recurrence, infection, wound seroma and nerve damage occur in 30% of cases. Recurrence rate is depends on the complexity of the lesion and the completeness of the excision. Sometimes when the cystic hygromas is in Head and Neck area, proximity with vital structures such as parotid gland, facial nerve, carotid sheath, complete excision is challenging. There are difficulties in surgical management.

#### 4. Conclusion

Cystic hygroma is a manageable lesion in paediatric population. Depending upon its size, location its treatment differs. Line of management can be surgery alone, sclerotherapy alone or combined use of both. Higher centres are trying with treatment modalities such as laser and radio frequency can also be used in selected patients.

#### 5. Conflict of Interest

The authors declare no relevant conflicts of interest.


#### 6. Source of Funding

None.

#### References

1. Emery PJ, Bailey CM, Evans J. Cystic hygroma of the head and neck. A review of 37 cases. *J Laryngol Otol.* 1984;98(6):613–9. doi:10.1017/s0022215100147176.
2. Pandit SK, Rattan KN, Budhiraja S, Solanki RS. Cystic lymphangioma with special reference to rare sites. *Indian J Pediatr.* 2000;67(5):339–41. doi:10.1007/BF02820682.
3. Manikoth P, Mangalore GP, Megha V. Axillary cystic hygroma. *J Postgrad Med.* 2004;50(3):215–6.
4. Fonkalsrud EW. Lymphatic disorders. In: Jr GOJ, Coran A, Fonkalsrud E, Caldamone A, editors. *Pediatric surgery.* 6th Edn. Chicago: Mosby Elsevier; 2006. p. 2137–45.
5. Sanlihalp I, Karnak I, Tanyel FC, Senocak ME, Buyukpamukcu N. Sclerotherapy for lymphangioma in children. *Int J Pediatr Otorhinolaryngol.* 2003;67(7):795–800. doi:10.1016/s0165-5876(03)00123-x.
6. Grasso DL, Pelizzo G, Zocconi E, Schlee J. Lymphangiomas of the head and neck in children. *Acta Otorhinolaryngol Ital.* 2008;28(1):17–20.
7. Sannoh S, Quezada E, Merer DM. Cystic hygroma and potential airway obstruction in a newborn: a case report and review of the literature. *Cases J.* 2009;2:48. doi:10.1186/1757-1626-2-48.
8. Kamath BS, Chatterjee AS, Chandorkar I, Bhanushali H. Giant recurrent cystic hygroma: a case report. *J West Afr Coll Surg.* 2014;4(2):100–11.
9. Acevedo JL, Shah RK, Brietzke SE. Nonsurgical therapies for lymphangiomas: a systematic review. *Otolaryngol Head Neck Surg.* 2008;138(4):418–24.

#### Author biography

**Sapna S Deshpande**, Assistant Professor  <https://orcid.org/0000-0002-8304-3246>

**Vishrabdha Pawar**, Professor

**AN Kurane**, Professor and Head

**Anushree Modi**, Resident

**Cite this article:** Deshpande SS, Pawar V, Kurane AN, Modi A. Cystic hygroma: Case report. *IP Arch Cytol Histopathology Res* 2022;7(2):129-131.