

Content available at: <https://www.ipinnovative.com/open-access-journals>

IP Archives of Cytology and Histopathology Research

Journal homepage: <https://www.achr.co.in/>

Case Report

Microfilaria detected in a female breast nodule- A rare incidental finding in FNAC

Khushboo^{1,*}, Bikash Kumar¹

¹Dept. of Pathology, Medanta Hospital, Ranchi, Jharkhand, India



ARTICLE INFO

Article history:

Received 21-02-2022

Accepted 16-03-2022

Available online 29-06-2022

Keywords:

Microfilaria

FNAC

Nodule

ABSTRACT

Background: Microfilaria is a major public health problem in tropical countries like India. It is most commonly diagnosed in peripheral blood smears, but detection of microfilaria in FNAC of breast is a rare finding.

Case presentation: We are reporting a case of 35 year old female who presented with a painless nodule in left breast. Fine-needle aspiration cytology from the nodule was done, aspiration showed many sheathed motile microfilaria likely *Wuchereria bancrofti* and the patient was put on anti-filarial treatment with Diethyl carbamazine citrate.

Conclusion: In endemic areas, it should be considered as one of the differential diagnoses of a superficial swelling. Despite its high prevalence, filariasis in female breast is a rare finding and careful screening of nodules help in detecting microfilaria even in asymptomatic patients and thus plays a significant role in recognition of the disease and institution of specific treatment.

This is an Open Access (OA) journal, and articles are distributed under the terms of the [Creative Commons Attribution-NonCommercial-ShareAlike 4.0 License](https://creativecommons.org/licenses/by-nc-sa/4.0/), which allows others to remix, tweak, and build upon the work non-commercially, as long as appropriate credit is given and the new creations are licensed under the identical terms.

For reprints contact: reprint@ipinnovative.com

1. Background

Filariasis has been a major public health problem in India next only to malaria. The discovery of microfilariae (mf) in the peripheral blood was made first by Lewis in 1872 in Calcutta (Kolkata). The persons having circulating microfilariae are outwardly healthy but transmit the infection to others through mosquitoes.

The persons with chronic filarial swellings suffer severely from the disease but no longer transmit the infection. In India, 99.4% of the cases are caused by the species - *Wuchereria bancrofti* whereas *Brugia malayi* is responsible for 0.6% of the problem.

2. Case Report

A 35 year old female presented with painless swelling measuring 2 cm in left breast since 3 weeks. On palpation,

cystic to firm, nontender nodule measuring 2 cm felt in upper outer quadrant of left breast. The overlying skin was normal. There was no history of nipple discharge and axillary lymph node were not palpable. Other physical and medical examination were unremarkable. USG showed well defined hypoechoic cystic lesion with septations at 2 O' clock position. Fine needle aspiration of the breast nodule was performed using 23 gauge needle. Straw coloured aspirate was smeared, air dried and stained with May- Grunwald- giemsa stain. Microscopic picture showed adult gravid female filarial worm, un coiled form with hyaline sheath, a large cephalic space and presence of nuclei which appeared as granules. The tail tip was free of nuclei (Figure 1). There were scattered inflammatory cells comprising of eosinophils, polymorps, lymphocytes and few histiocytes along with occasional benign ductal epithelial cells of breast. Right breast was unremarkable. Peripheral smear did not show presence of microfilariae. After diagnosis was made, patient was given DEC 100 mg

* Corresponding author.

E-mail address: hellokhushi21@gmail.com (Khushboo).

thrice daily for 14 days and was followed. After that patients was followed and showed decrease in size of nodule.

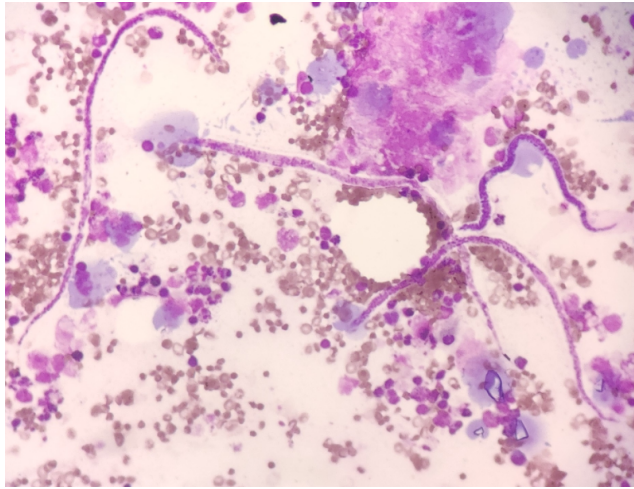


Fig. 1: Adult gravid female filarial worm, uncoiled form with hyaline sheath, a large cephalic space and granular nuclei, tail tip showed absence of nuclei.

3. Discussion

Filariasis is a major health problem which is faced in tropical countries such as India, China, West Indies, Japan and parts of Africa. The disease is endemic all over India, especially in states like Bihar, Jharkhand, Uttar Pradesh, Andhra Pradesh, Orissa, Tamil Nadu, Kerala and Gujarat.¹ *Wuchereria bancrofti* has a worldwide distribution and it nearly accounts for 90% of the filariasis cases, which is more prominent than *Brugia malayi* and *Brugia timori*.² Among the eight species of filarial parasites, lymphatic systems of the lower limbs, spermatic cord and epididymis and retroperitoneal tissue were the most common site of filarial infection.³

Female breast is an unusual site for filarial worms presenting as painless nodule.^{2,4-6} *W. bancrofti* presenting as a nodule is a very rare presentation. Subcutaneous filariasis is most commonly caused by *Loa loa*, *Onchocerca volvulus* and *Mansonella*.⁷ Among the reported cases, filarial breast nodules were commonly found at the upper outer quadrant of the breast,⁸ which is similar in our case as patient presented with nodule in upper outer quadrant of left breast. Diagnosis of filarial lesions depends on the demonstration of microfilaria in the blood, body fluids or tissue aspirates. Species identification is possible on the basis of microfilarial morphology as it is difficult in case of adult worm.^{3,6} The microfilariae of *W. bancrofti* often demonstrate periodicity so blood samples must be taken at night, preferably between 10 P.M and 2 A.M.² FNAC is widely accepted, well established, easily accessible method of diagnosing benign and malignant lesions of breast.⁹ Cytomorphology of the

nodule showed numerous microfilarial worms along with mixed inflammatory infiltrates (eosinophils, neutrophils, lymphocytes, few histiocytes) and benign looking ductal epithelial cells.^{8,9}

Humans are exclusive and definitive hosts for *W. bancrofti*. The major vectors are *Culex* mosquitoes (urban areas) and *Anopheles* mosquitoes (rural areas). Adult worms reside in lymphatic channels and the larval forms (microfilariae) may circulate in the peripheral blood.

Microfilariae may present in an unusual fashion, so careful screening of all the cytology smears, where filariasis is suspected must be done. As in this case, patient had no history of nipple discharge, no other complaints other than a nodule, so it is important medically for diagnosis and for treatment of the patients, especially in endemic areas.¹⁰ Our case was unique presentation of breast nodule mimicking malignant lump. FNAC leads to accurate and early diagnosis of microfilaria, thus avoiding surgery. Patient was given DEC 100 mg thrice daily for 14 days and responded well.

4. Conclusion

Breast filariasis is rare diagnosis in a patient presenting with nodule. FNAC is an effective, safe, easy and early procedure in diagnosis of microfilaria even when not diagnosed in peripheral smears, and thus avoiding unnecessary surgery. It should be kept as one of the differential diagnosis of subcutaneous cystic swelling of breast especially in endemic countries like India.

5. Conflicts of Interest

There are no conflicts of interest.

6. Source of Funding

None.


References

1. Singh AK, Gupta P, Yadav S, Pahawa HS. Incidental Detection Microfilaria in Subcutaneous Breast Nodule of Lactating Female Fnac: A Rare Case Report. *J Clin Diagn Res: JCDR*. 2014;8(6):FD03–4. doi:10.7860/JCDR/2014/7494.4418.
2. Lau M, Tauchi P, Kim M, Liu F, Namiki T. Filariasis of the breast in a pregnant woman diagnosed by fine-needle aspiration cytology: A case report. *Infect Dis Obstet Gynecol*. 1995;3(6):245–7. doi:10.1155/S106474499500072X.
3. Kaur R, Phillip KJ, Masih K, Kapoor R, Johnny C. Filariasis of the breast mimicking inflammatory carcinoma. *Lab Med*. 2009;40(11):683–5.
4. Singh NG, Chatterjee L. Filariasis of the breast, diagnosed by fine needle aspiration cytology. *Ann Saudi Med*. 2009;29(5):414–5.
5. Rukmangadha N, Shanthi V, Kiran CM, Kumari NP, Bai SJ. Breast filariasis diagnosed by fine needle aspiration cytology—a case report. *Indian J Pathol Microbiol*. 2006;49(2):243–4.
6. Bhardwaj S, Mahajan D, Attri MR. Filariasis of the breast. *JK Sci*. 2007;9(2):98–9.
7. Valand AG, Pandya BS, Patil YV, Patel LG. Subcutaneous filariasis: An unusual case report. *Indian J Dermatol*. 2007;52(1):48–9.

doi:10.4103/0019-5154.31925.

8. Dayal A, Selvaraju K. Filariasis of the breast. *Med J Armed Forces India*. 2015;71(1):S240–1. doi:10.1016/j.mjafi.2014.05.002.
9. Pal S, Bose K. Microfilaria in fine needle aspiration cytology of breast lump: An unusual finding. *J Health Spec*. 2015;3:235–7.
10. Singh P, Chand N, Singal R, Madan M, Bala J. Filariasis presenting as multiple subcutaneous nodules: a rare case report. *Acta Medica Indonesiana*. 2011;43(4):249–51.

Author biography

Khushboo, Attending Lecturer  <https://orcid.org/0000-0002-9999-7116>

Bikash Kumar, Senior Consultant

Cite this article: Khushboo, Kumar B. Microfilaria detected in a female breast nodule- A rare incidental finding in FNAC. *IP Arch Cytol Histopathology Res* 2022;7(2):136-138.