

Content available at: <https://www.ipinnovative.com/open-access-journals>

IP Archives of Cytology and Histopathology Research

Journal homepage: <https://www.achr.co.in/>

## Case Report

# Atypical presentation of a Sinus histiocytosis with massive lymphadenopathy (Rosai Dorfman disease) with granulomas - Post COVID-19 infection

Sheba S K Jacob <sup>1,\*</sup><sup>1</sup>Dept. of Pathology, Apollo Hospitals, Chennai, Tamil Nadu, India

## ARTICLE INFO

### Article history:

Received 05-05-2022

Accepted 10-05-2022

Available online 29-06-2022

### Keywords:

COVID19

Rosai Dorfman disease

Hemophagocytosis

## ABSTRACT

A 51-year-old gentleman developed a rapidly progressing inguinal mass three months post corona virus disease (covid-19) infection. On examination, there was generalized lymphadenopathy confirmed by CT scans and a lymphoma was suspected. On light microscopy there were features of Rosai Dorfman disease with associated necrotizing granulomas amidst the large cells in the sinusoids, which have not been described before in Rosai Dorfman disease. Gene x-pert for tuberculosis, bacterial, fungal and acid fast bacilli cultures were negative. We present this case report for documenting this presentation post COVID-19 infection with review of literature.

This is an Open Access (OA) journal, and articles are distributed under the terms of the [Creative Commons Attribution-NonCommercial-ShareAlike 4.0 License](https://creativecommons.org/licenses/by-nc-sa/4.0/), which allows others to remix, tweak, and build upon the work non-commercially, as long as appropriate credit is given and the new creations are licensed under the identical terms.

For reprints contact: [reprint@ipinnovative.com](mailto:reprint@ipinnovative.com)

## 1. Introduction

Severe acute respiratory syndrome (SARS) COVID-19 infection has caused a pandemic with varied immunological response and clinical presentation in different people, causing increased morbidity and mortality. It varies from mild or no illness to acute and chronic respiratory failure and severe thrombotic complications due to hyperinflammatory response. This heterogeneity of presentation and the complex pathogenesis behind it is still not completely understood. One of the interesting immunological response observed in a patient is presented in this case report.

## 2. Case Study

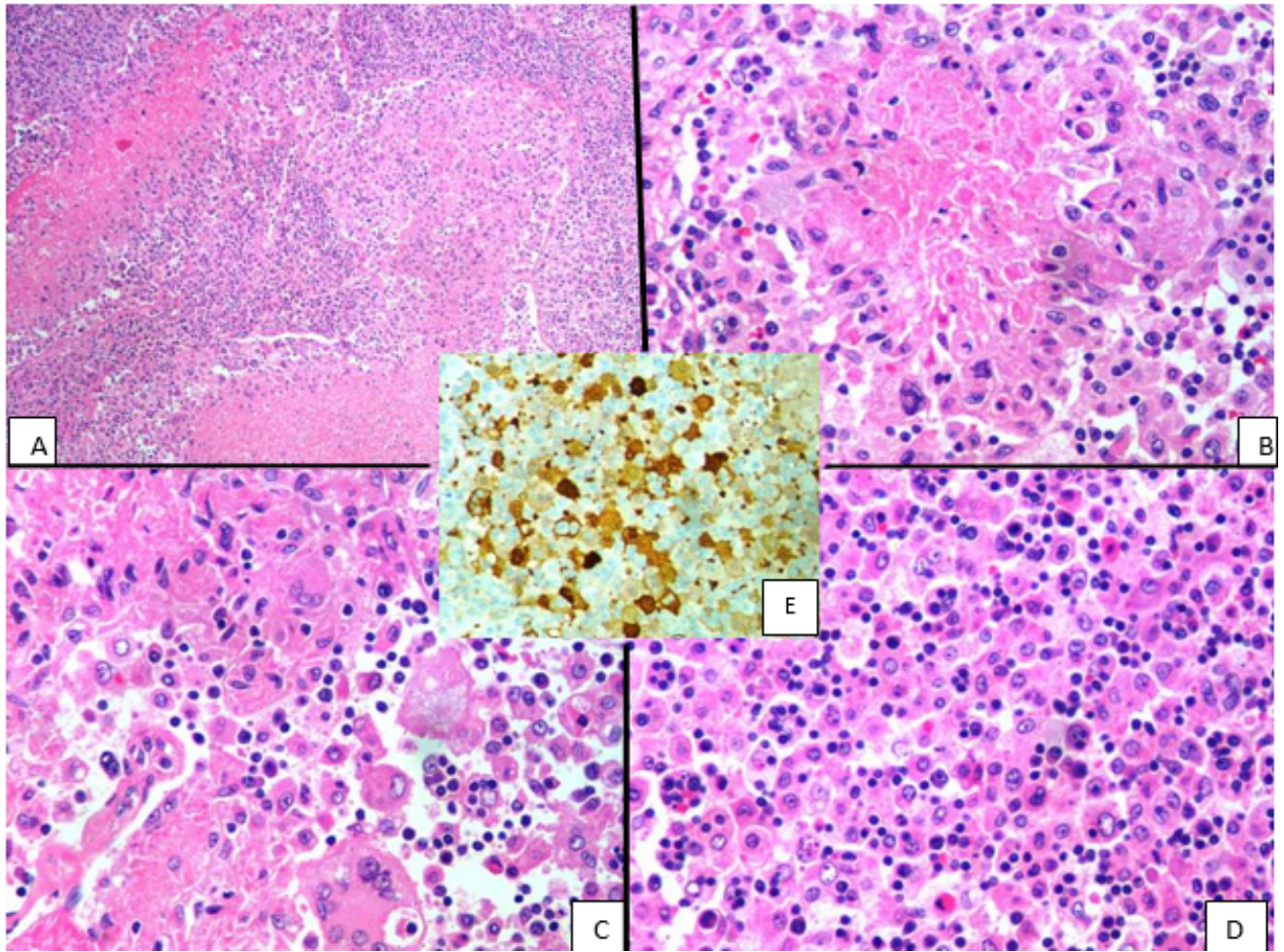
A 51 year old gentleman presented with swelling in the groin which was increasing in size for the past three months. He had recovered from RT-PCR positive COVID-19 with moderate symptoms during the first wave. He has no co-morbidities. On examination there was generalized lymphadenopathy with inguinal lymph node being the

largest. It was excised and sent for histopathology. Grossly the lymph node was 7x2.5x2cm. Cut surface was grayish white and soft in consistency. On light microscopy, there was effacement of normal nodal architecture due to dilated sinusoids, expanded due to large cells with vesicular nuclei, prominent nucleoli and emperipolesis was noted. Also amidst these were foci of necrosis surrounded by epithelioid histiocytes. Hemophagocytosis was also noted. Most of the follicles were atretic and sheets of plasma cells were noted in the interfollicular region. Stains for acid fast bacilli and fungi and gene XPERT for tuberculosis were negative. Cultures for bacteria, fungi and acid fast bacilli were also negative. The large cells were positive for S100, CD68 and negative for CD1a.

The pathogenesis of complications due to COVID is not completely understood. Few autopsy examinations have focused mainly on the changes in the lung which is diffuse alveolar damage with hyaline membranes, alveolar fibrinous material, edema and type II alveolar hyperplasia. Also thrombi have been reported in the smaller and larger blood vessels. Severely ill patients have increased serum ferritin and altered pattern of inflammatory

\* Corresponding author.

E-mail address: [shebajacob25@gmail.com](mailto:shebajacob25@gmail.com) (S. S. K. Jacob).



**Fig. 1:** **A:** x100 magnification of hematoxylin and eosin stained image of lymph node with focus of necrosis surrounded by epithelioid histiocytes and large cells with emperipolesis. Lymphocytes and plasma cells are noted in the background; **B:** x400 magnification of hematoxylin and eosin stained image of focus of necrosis surrounded by epithelioid histiocytes and large cells with emperipolesis; **C:** x400 magnification of hematoxylin and eosin stained image of epithelioid histiocytes and giant cells with emperipolesis; **D:** x400 magnification of emperipolesis; **E:** Immunohistochemistry:S100 positivity in large cells with emperipolesis.

cytokines and chemokines as a sign of high systemic inflammatory response - cytokine storm.<sup>1</sup> Histiocytic hyperplasia with hemophagocytosis was observed in an autopsy study of severe cases of COVID. A study of the lymph nodes from six patients show lymphoid depletion, hemophagocytosis and extended interfollicular plasmacytosis.<sup>2</sup> A dysregulation of interferon (IFN) - mediated signal transduction appears to be central to the immunopathology of COVID-19.<sup>3</sup> The granulomatous reaction found in our patient may be due to dysregulation of interferon. Florid polyclonal immunoblastic proliferation was observed in an intubated COVID patient.<sup>4</sup> A review article analyzing data from various articles on COVID showed absent germinal centres, reactive plasmablasts in the interfollicular zone, hemophagocytosis and a rare case with necrotizing granulomatous inflammation.<sup>5</sup> In our case we had a clear history of enlarging lymph node

post COVID and the lymph node showed large cells with emperipolesis, hemophagocytosis, foci of necrosis surrounded by epithelioid histiocytes and interfollicular plasmacytosis.

Sinus histiocytosis with massive lymphadenopathy (SHML) is a disorder of unknown etiology but immune dysregulation or aberrant immune response to a pathogen has been proposed. It has been reported in nodal and extra-nodal sites. It has been associated with autoimmune disorders.<sup>6-9</sup> One of the frequent clinical presentations is painless lymphadenopathy involving cervical, axillary, or abdominal regions accompanied by B symptoms, but a few patients may have painful or tender lymph nodes. Our patient had painless enlargement of lymph nodes and had no symptoms post resection of the lymph node when followed for a few months. The available treatment modalities include surgical resection, radiotherapy, chemotherapy,

immunomodulatory drugs and observation.<sup>10</sup>

The altered immune response leading to sinus histiocytosis with massive lymphadenopathy along with dysregulation of interferon described in COVID infection might have caused formation of granulomas in our patient. Our patient was observed after resection since his cultures were also negative and is well few months follow up.

### 3. Conclusion

This case report is to document a varied morphological presentation of SHML in a post COVID -19 infection scenario with the presence of necrosis and epithelioid histiocytes possibly due to immune dysregulation due to COVID-19 infection.

### 4. Conflict of Interest

The authors declare no relevant conflicts of interest.

### 5. Source of Funding

None.

### References

- Chilosi M, Poletti V, Ravaglia C, Rossi G, Dubini A, Piciucchi S, et al. The pathogenic role of epithelial and endothelial cells in early-phase COVID-19 pneumonia: victims and partners in crime. *Modern Pathol.* 2021;34(8):1444–55.
- Núñez-Torrón C, Ferrer-Gómez A, Moreno EM, Pérez-Mies B, Villarrubia J, Chamorro S, et al. Secondary haemophagocytic lymphohistiocytosis in COVID-19: correlation of the autopsy findings of bone marrow haemophagocytosis with HScore. *J Clin Pathol.* 2021;p. 207337. doi:10.1136/jclinpath-2020-207337.
- Haslbauer JD, Matter MS, Stalder AK, Tzankov A. Histomorphological patterns of regional lymph nodes in COVID-19 lungs. *Der Pathol.* 2021;42(1):89–97. doi:10.1007/s00292-021-00945-6.
- Tucker CM, Uppal GK. Things are not always what they seem: Histopathology of Covid-19 lymphadenopathy. *eJHaem.* 2021;2(2):309–10. doi:10.1002/jha2.156.
- Caramaschi S, Kapp ME, Miller SE, Eisenberg R, Johnson J, Epperly G, et al. Histopathological findings and clinicopathologic correlation in COVID-19: a systematic review. *Mod Pathol.* 2021;34(9):1614–33.
- Ghosh J, Ghosh J. Sinus Histiocytosis with Massive Lymphadenopathy - Its Rare Immunological Complication. *J Cancer Sci Ther.* 2015;7(1):1–2. doi:10.4172/1948-5956.1000317.
- Maric I, Pittaluga S, Dale JK, Niemela JE, Delsol G, Diment J, et al. Histologic features of sinus histiocytosis with massive lymphadenopathy in patients with autoimmune lymphoproliferative syndrome. *Am J Surg Pathol.* 2005;29(7):903–11.
- Alkuwaity KW, Alosaimi MH, Alsahlawi KT, Alomair MA, Battyour MA, Alkuwaity DW, et al. Unusual presentation of Rosai-Dorfman disease: report of a rare case. *Am J Case Rep.* 2019;20:91–6. doi:10.12659/AJCR.912423.
- Maia RC, De Meis E, Romano S, Dobbin JA, Klumb CE. Rosai-Dorfman disease: a report of eight cases in a tertiary care center and a review of the literature. *Braz J Med Biol Res.* 2014;48(1):6–12. doi:10.1590/1414-431X20144110.
- Abla O, Jacobsen E, Picarsic J, Krenova Z, Jaffe R, Emile JF, et al. Consensus recommendations for the diagnosis and clinical management of Rosai-Dorfman-Destombes disease. *Blood.* 2018;131(26):2877–90.

### Author biography

**Sheba S K Jacob**, Senior Consultant  <https://orcid.org/0000-0002-6515-0697>

**Cite this article:** Jacob SSK. Atypical presentation of a Sinus histiocytosis with massive lymphadenopathy (Rosai Dorfman disease) with granulomas - Post COVID-19 infection. *IP Arch Cytol Histopathology Res* 2022;7(2):139-141.