

Content available at: <https://www.ipinnovative.com/open-access-journals>

IP Archives of Cytology and Histopathology Research

Journal homepage: <https://www.achr.co.in/>

Case Series

Unveiling the journey of diagnosing cutaneous lymphomas- A case series

Samridhi Hegde¹, Sandhya Ilanthodi^{1,*}, Prithal G¹, Reba T Phillipose¹, Girish P N²

¹Dept. of Pathology, A J Institute of Medical Sciences and Research Centre, Mangalore, Karnataka, India

²Dept. of Dermatology, A J Institute of Medical Sciences and Research Centre, Mangalore, Karnataka, India



ARTICLE INFO

Article history:

Received 14-05-2022

Accepted 08-06-2022

Available online 29-06-2022

Keywords:

Mycosis Fungoides

Angioimmunoblastic T cell lymphoma

Cutaneous Tcell lymphoma

ABSTRACT

Cutaneous manifestation of Non-Hodgkin lymphoma can histologically and clinically manifest as Mycosis fungoides or Vasculitis. Histopathologic features of cutaneous lymphoma show dense tumor with a “bottom heavy” configuration. Tumor comprises either large lymphoid cells or sheets of monotonous small lymphoid cells with plasmacytoid configuration. A detailed work up is mandatory to conclude the diagnosis and provide definitive treatment in cutaneous lymphomas. In our case series, we present and describe 5 cases of Non-Hodgkin lymphoma with cutaneous manifestations. Two cases of Angioimmunoblastic T Cell Lymphoma with clinical and histological presentation as vasculitis, 2 cases of Mycosis fungoides concluded as Human T-cell Lymphotropic Virus (HTLV) positive Adult T Cell Lymphomas on evaluation, 1 case which was lost to follow up are discussed. Thus, this case series emphasizes on the need to do complete work up of cutaneous lymphomas.

This is an Open Access (OA) journal, and articles are distributed under the terms of the [Creative Commons Attribution-NonCommercial-ShareAlike 4.0 License](https://creativecommons.org/licenses/by-nc-sa/4.0/), which allows others to remix, tweak, and build upon the work non-commercially, as long as appropriate credit is given and the new creations are licensed under the identical terms.

For reprints contact: reprint@ipinnovative.com

1. Introduction

Cutaneous T cell lymphomas (CTCLs) are a heterogeneous group of extranodal Non-Hodgkin's lymphomas that are characterized by a cutaneous infiltration of malignant monoclonal T lymphocytes. They typically afflict adults with a median age of 55 to 60 years. Mycosis fungoides, Sézary syndrome, and primary cutaneous peripheral T cell lymphomas not otherwise specified, Angioimmunoblastic T-cell lymphoma are the most important subtypes of CTCL. CTCL is a complicated concept in terms of etiopathogenesis, diagnosis, therapy, and prognosis.¹

Mycosis Fungoides is the most common cutaneous T-cell lymphoma.² Angioimmunoblastic T Cell Lymphoma represents 15-20% of all peripheral T cell lymphomas and 1-2% of all Non-Hodgkin lymphomas. Patients in the sixth and seventh decades are affected with slightly

male predominance. Involvement of cutaneous vessels can present clinically as vasculitis.³

In the recent revised WHO classification 2017 and the updated WHO-EORTC classification for Cutaneous Lymphoma 2018, primary cutaneous CD8+ acral T-cell lymphoma has been introduced as a new still provisional entity. It displays characteristic clinical, histological and phenotypic features and exhibits an prognosis. Aggressive CTCL present with rapid onset of necrotic or ulcerated plaques and tumors which include primary cutaneous aggressive epidermotropic CD-8 positive T-cell lymphoma and cutaneous gamma/ delta T-cell lymphoma.⁴

We describe histological features of 5 patients with CTCL presented at a tertiary care hospital, Mangalore.

2. Case 1

A 45-years- old female presented with 8 months history of lesions all over the body predominant over less sun

* Corresponding author.

E-mail address: drsandhyaigirish@gmail.com (S. Ilanthodi).

exposed areas like neck, trunk, back, both hands and legs associated with itching. On physical examination, multiple well to ill defined hyperpigmented to skin colored scaly plaques with exfoliation of the skin appreciated all over the body predominantly over neck, bilateral upper limbs, trunk and bilateral thighs. Palms and soles were not involved. Complete blood count showed elevated total count of $18.1 \times 10^3 \mu\text{L}$, LFT showed a serum protein level of 6.1g/dl. The skin punch biopsy showed lamellated orthokeratosis of the epidermis with mild acanthosis and patchy collection of lymphoid cells with epidermotropism forming Pautrier's micro-abscesses. These lymphoid cells had convoluted nuclei and indistinct nucleoli. IHC markers showed CD3, CD4, CD5 positive with CD30 focal positivity. CD8 was negative. Bone marrow aspirate showed 36% abnormal lymphoid cells. Flow cytometry confirmed Adult T-cell leukemia / lymphoma (ATLL). Serum was positive for HTLV I and II antibodies. Thus the final diagnosis of "HTLV positive cutaneous T cell lymphoma". (Figures 1 and 2)

3. Case 2

A 71-years- old female presented with 6 months history of flat reddish patches over the trunk and bilateral upper extremities associated with pruritis. Her treatment regimen included oral steroid medication. The skin punch biopsy revealed epidermis with spongiosis and focal infiltration by lymphoid cells composed of round nuclei, indented nuclear contour and distinct nucleoli. Based on the histomorphology, diagnosis of folliculotropic mycosis fungoides was considered. IHC markers CD4 / CD8/ CD7 was recommended. Further on examining the peripheral smear, >10% of lymphoid cells were identified with 40% of abnormal lymphoid cells in the bone marrow aspirate. The case was concluded as Adult T-cell lymphoma with the available laboratory investigations. The patient was lost to follow up.

4. Case 3

A 40-years-old male presented with 5months history of scaly patches over the trunk associated with pruritis and hypopigmented patches over the upper extremities. The skin punch biopsy showed thinned out epidermis exhibiting lamellated orthokeratosis with focal epidermotrophism. Perivascular infiltrate with predominantly monomorphic convoluted lymphocytes noted. A diagnosis of Mycosis fungoides-patch stage was made.

Further evaluation was not done as patient was lost to follow up.

5. Case 4

A 46-years-old female presented with 3 months history of painless swelling in the right axillary lymph node

with 12 days history of cutaneous lesions over the lower extremities consistent with vasculitis. Histomorphological features of right axillary lymph node biopsy showed diffuse effacement of architecture with capsular infiltration and patent subcapsular sinusoidal spaces, marked proliferation of high endothelial venules with expansion of follicular dendritic cells in the interfollicular zone. Granulomas composed of epithelioid histiocytes admixed with few residual intact follicles noted. The skin punch biopsy showed dermal perivascular lymphoid infiltrate composed of oval and cleaved nuclei, extravasated RBCs, fibrinoid necrosis and leucocytoclasia. IHC markers CD20 showed strong membranous positivity in follicles with residual germinal centres and expansion of paracortical T-cell zones. CD3, CD4 showed diffuse strong membranous positivity in T-cell zone with expansion of paracortical T-cell zone. CD21 showed strong membranous positivity in follicular dendritic cells in follicles with irregular germinal centres and T-cell zones. Follicular dendritic cell proliferation noted to envelope around high endothelial venules. CD10 showed membranous positivity at T-cell zone. Ki67 was 40% positive in tumor cells.

Based on histomorphological and IHC markers, diagnosis of "angioimmunoblastic T cell lymphoma with cutaneous infiltration" was made.

6. Case 5

A 65-years-old male presented with 2 months history of loss of appetite and 10 day history of cutaneous lesions over the lower abdomen, lower and upper extremities. Lymphadenopathy of bilateral inguinal, cervical and supraclavicular nodes noted. The skin punch biopsy showed lamellated keratosis of epidermis with perivascular lymphoid infiltrate composed of oval and cleaved nuclei along with extravasated RBCs noted. The cervical lymph node biopsy showed marked proliferation of high endothelial venules with expansion of follicular dendritic cells in the interfollicular zone along with diffuse effacement of architecture and capsular infiltration. Correlating both the histomorphological features, a diagnosis of "angioimmunoblastic T cell lymphoma with cutaneous infiltration" was made. (Figure 3)

7. Discussion

Primary cutaneous lymphomas (CL) are the second most common group of extranodal lymphomas. Cutaneous T-cell lymphomas (CTCL) represent the majority, accounting for approximately 65%–75% of all CL. All other CTCL forms are rare with each entity accounting for less than 1% of all CTCL. Primary CL present in the skin without extracutaneous disease at the time of diagnosis and often remain limited to the skin over long periods of disease evolution. Progression with extracutaneous spread occurs

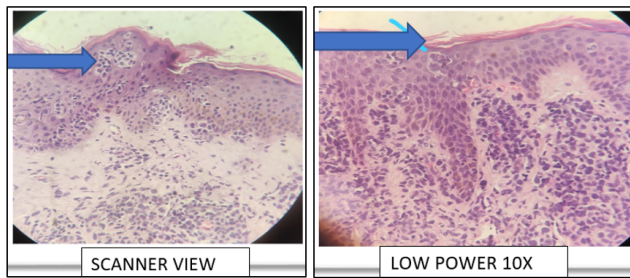


Fig. 1: Histomorphological findings in mycosis fungoides: Epidermotropism and bandlike lymphoid infiltrate with convoluted nuclei in the papillary dermis.

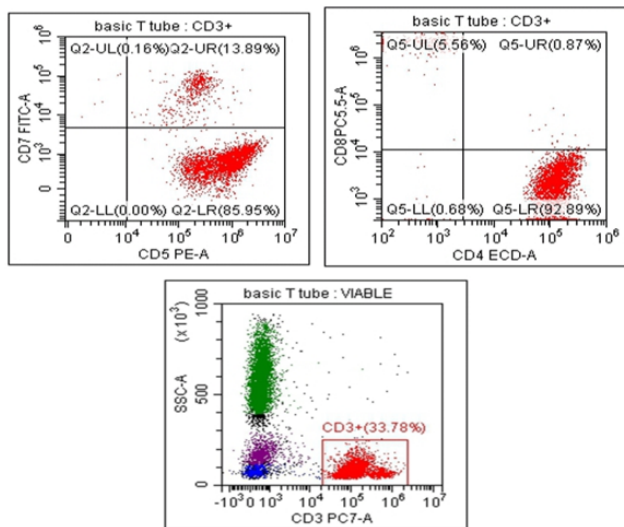


Fig. 2: Flow cytometry in adult t-cell leukemia / lymphoma. CD-3 Positive gated abnormal lymphoid cells are bright CD 45+ and have bright expression: CD3, CD5, CD4, negative expression: CD26, CD7, CD8.

usually in advanced late stages.⁴

We studied 5 cases of Non-Hodgkin Lymphoma with primary cutaneous manifestations. Case-1 was initially diagnosed as mycosis fungoides which on further evaluation was diagnosed as HTLV positive cutaneous T cell lymphoma.

The histomorphological features of skin biopsy was similar to mycosis fungoides with classical features. This mandates a detailed workup of cases with cutaneous manifestation. Skin biopsy alone does not conclude the diagnosis as it can be cutaneous manifestation of Non-Hodgkin lymphoma.

Mycosis fungoides may clinically and histologically mimic benign skin conditions, posing a diagnostic challenge to the dermatologist was inferred in a study done by Sarah I Jawed et al.⁵

Histopathology of mycosis fungoides varies with stage of the disease. Patch stage, Plaque stage and Tumor

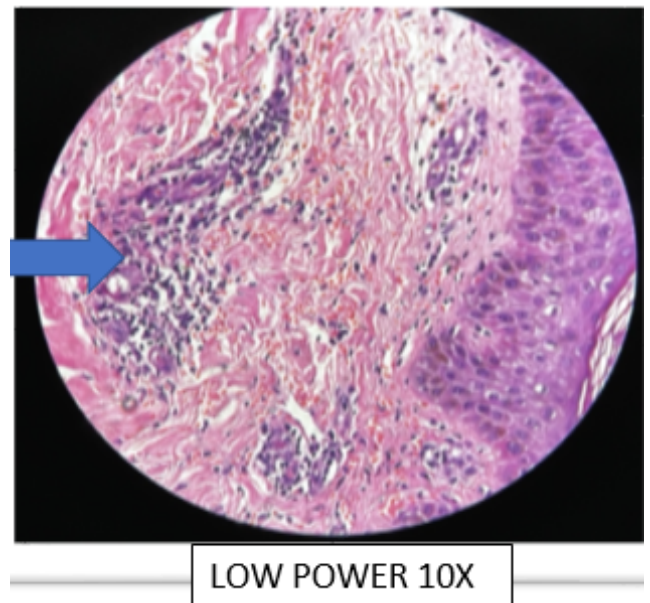


Fig. 3: Histomorphological findings in angioimmunoblastic t cell lymphoma with cutaneous infiltration. Perivascular abnormal lymphocytic infiltrate composed of oval and cleaved nuclei with extravasated RBCs.

stage- are the various stages of the disease. Superficial lymphoid infiltrate, epidermotropism with absent or rare spongiosis, and lymphoid atypia are the characteristic histological features of mycosis fungoides.²⁻⁴

Precise clinicopathologic correlation is necessary to support a diagnosis, especially in the early stages of disease. In addition to the identification of histopathologic criteria, ancillary studies, including the identification of CD4(+) T cells with aberrant immunophenotypes and T-cell receptor gene rearrangements within skin lesions and peripheral blood are used to support the diagnosis. Recent studies evaluating the pathogenesis of MF have found that the skin microenvironment, including immune cells, such as dendritic cells and reactive cytotoxic and regulatory T cells, plays a crucial supporting role in MF.⁶ The skin-homing ability of malignant T cells is the result of chemokines, cytokines, adhesion molecules, and defective apoptosis, and is believed to play a role in disease pathogenesis and progression. In addition, recent studies have also suggested that MF arise from distinct memory T cell subsets and advanced/erythrodermic MF may be distinguished by identification of certain molecules, including Programmed-Death-1.⁶

Cutaneous manifestations in both case 4 and case 5 were presenting clinically as vasculitis with necrotic papules and purpuric rashes. Histopathological features of cutaneous lesions also showed vasculitis like features with leucocytoclasia and RBC extravasation. Both these cases underwent lymph node biopsy, histomorphology

supplemented with immunohistochemistry (neoplastic population positive for CD20, CD3, CD4, CD21, CD10, Ki67) helped in reaching a diagnosis of angioimmunoblastic T cell lymphoma.

Histomorphological features in Angioimmunoblastic T cell Lymphoma show three patterns with partial or complete architectural effacement and polymorphous inflammatory background.

The three patterns are

1. Pattern I: architecture partially preserved and hyperplastic follicles with tingible body macrophages and indistinct mantle zones.
2. Pattern II: architecture mostly preserved with residual follicles.
3. Pattern III: architecture completely effaced without residual follicles.⁷

Complete follow up and correlation of histomorphology, peripheral smear and bone marrow aspirate findings, flow cytometry, IHC markers is crucial to arrive at the diagnosis.⁷

In study done by Loghavi et al,⁸ angioimmunoblastic T-cell lymphoma often shows systemic symptoms related to immune dysregulation and cytokine production. Biopsy usually harbors few malignant cells in an abundant reactive background, which can be diagnostically challenging in cases with small biopsies. This study was performed to assess the value of flow cytometry (FC) and to determine the immunophenotypic alterations in 155 samples from 38 patients with AITL. FC detected an aberrant T-cell population in 97 of 155 samples that represented 0.5-90% of lymphocytes. Blood was involved in 11 of 16 patients. The most frequent immunophenotypic aberrancies included loss of CD3; altered T-cell receptor expression and aberrant CD10 expression. Altered CD3 expression was more frequently seen in peripheral blood (PB) and bone marrow (BM), whereas aberrant CD10 expression was more common in lymph node (LN). AITL cells often exhibit abnormal CD4⁺ immunophenotype with diminished or absent CD3 and variable CD10 expression. Multiparameter FC is an effective tool for supporting the diagnosis of AITL in any fluid and various tissue specimens types.⁵

In Cutaneous T-Cell Lymphomas, therapy is stage-adapted with skin-directed therapies such as UV-light therapies and corticosteroids in early disease stage of MF (i.e., patch and limited plaque stage) and systemic therapies (retinoids, interferon, mono chemotherapy, targeted therapy) and/or radiation therapy (local or total skin beam electron) in advanced stages. Novel therapies include targeted therapy such as mogamulizumab (anti-CCR4) or brentuximab vedotin (anti-CD30) and histone deacetylase inhibitors. Considering the impact of targeted therapies, biomarkers such as CD30 are not only crucial for the diagnosis and correct classification of an individual

lymphoma case, but also for therapy as they may represent therapeutic targets.⁴

8. Conclusion

Cutaneous lymphomas can present with subtle clinical presentation. Skin biopsy with mycosis fungoides feature needs further evaluation to conclude a definitive diagnosis. A clinical presentation of vasculitis with generalised lymphadenopathy need a complete evaluation with lymph node biopsy along with skin biopsy for a conclusive diagnosis aiding in appropriate treatment.

9. Acknowledgement

I, hereby thank Dr. Sridevi H. B, Professor in KMC Mangalore for her unconditional support and co-operation in providing details of flowcytometry findings and report.

10. Conflict of Interest

None.

11. Source of Funding

None.

References

1. Bagherani N, Smoller BR. An overview of cutaneous T cell lymphomas. *F1000Res*. 2016;5:F1000 Faculty Rev-882. doi:10.12688/f1000research.8829.1.
2. Hossain C, Jennings T, Duffy R, Knoblauch K, Gochoco A, Chervoneva I, et al. The histological prevalence and clinical implications of folliculotropism and syringotropism in mycosis fungoides. *Chin Clin Oncol*. 2019;8(1):6. doi:10.21037/cco.2018.10.02.
3. Yamashita T, Abbade LP, Marques ME, Marques SA. Mycosis fungoides and Sézary syndrome: clinical, histopathological and immunohistochemical review and update. *An Bras Dermatol*. 2012;87(6):817–28. doi:10.1590/s0365-05962012000600001.
4. Kempf W, Mitteldorf C. Cutaneous T-cell lymphomas-An update 2021. *Hematological Oncol*. 2021;39:46–51. doi:10.1002/hon.2850.
5. Jawed SI, Myskowski PL, Horwitz S, Moskowitz A, Querfeld C. Primary cutaneous T-cell lymphoma (mycosis fungoides and Sézary syndrome): part I. Diagnosis: clinical and histopathologic features and new molecular and biologic markers. *J Am Acad Dermatol*. 2014;70(2):205.e1–16. doi:10.1016/j.jaad.2013.07.049.
6. Rodriguez-Justo M, Attygalle AD, Munson P, Roncador G, Marafioti T, Piris MA, et al. Angioimmunoblastic T-cell lymphoma with hyperplastic germinal centres: a neoplasia with origin in the outer zone of the germinal centre? Clinicopathological and immunohistochemical study of 10 cases with follicular T-cell markers. *Mod Pathol*. 2009;22(6):753–61. doi:10.1038/modpathol.2009.12.
7. Pimpinelli N, Olsen EA, Santucci M, Vonderheid E, Haeflner AC, Stevens S, et al. International Society for Cutaneous Lymphoma. Defining early mycosis fungoides. *J Am Acad Dermatol*. 2005;53(6):1053–63. doi:10.1016/j.jaad.2005.08.057.
8. Loghavi S, Wang SA, Medeiros LJ, Jorgensen JL, Li X, et al. Immunophenotypic and diagnostic characterization of angioimmunoblastic T-cell lymphoma by advanced flow cytometric technology. *Leuk Lymphoma*. 2016;57(12):2804–12. doi:10.3109/10428194.2016.1170827.

Author biography**Samridhi Hegde**, Post Graduate**Sandhya Ilanthodi**, Professor**Prithal G**, Assistant Professor**Reba T Phillipose**, Professor and HOD**Girish P N**, Professor and HOD

Cite this article: Hegde S, Ilanthodi S, Prithal G, Phillipose RT, Girish P N. Unveiling the journey of diagnosing cutaneous lymphomas- A case series. *IP Arch Cytol Histopathology Res* 2022;7(2):142-146.