

Content available at: <https://www.ipinnovative.com/open-access-journals>

IP Archives of Cytology and Histopathology Research

Journal homepage: <https://www.achr.co.in/>

Case Report

Surgical management in a classical haemophilia patient – A rare case report

Siva Rama Krishna Boddu^{1,*}, Monish Ram S.D¹, Suresh Hanagavadi¹

¹Dept. of Pathology, Jaya Jagadguru Murugarajendra Medical College, Davanagere, Karnataka, India



ARTICLE INFO

Article history:

Received 09-07-2022

Accepted 02-08-2022

Available online 23-09-2022

Keywords:

AHF

Inherited bleeding disorders

Surgical management and

Haemophilia

ABSTRACT

A young man presented with complaints of right upper quadrant pain for 6 months, past history revealed he is a known case of Haemophilia A, which is a challenge for surgeons and anaesthetist to manage intraoperative and postoperative bleeding, henceforth referred to Haematology, department of pathology. Soon after taking clinical history patient was subjected for haemostatic screening tests such as PT, APTT, mixing studies, inhibitors screening and factor VIII assay revealed patient is a case of several haemophilic with negative for inhibitors and elevated APTT values. Patient is prepared for surgery only after giving Anti haemophilic factor replacement and preoperatively achieving 100% haemostasis by raising Factor VIII assay to 100%. Intra and post operatively patient is constantly monitored for bleeding. Post operatively every 12hrs patient was infused with anti-haemophilic factor variable levels and tapering doses to maintain constant haemostasis as the factor VIII half-life is less than 12 hours. Patient was haemodynamically stable when discharged that is 7th day post-surgery. Thus, we presenting a case how to manage haemophiliacs in a simple way for any kind of surgery with availability of antihemophilic factors and expertise in maintaining the haemostasis as build up confidence among surgeons.

This is an Open Access (OA) journal, and articles are distributed under the terms of the [Creative Commons Attribution-NonCommercial-ShareAlike 4.0 License](https://creativecommons.org/licenses/by-nc-sa/4.0/), which allows others to remix, tweak, and build upon the work non-commercially, as long as appropriate credit is given and the new creations are licensed under the identical terms.

For reprints contact: reprint@ipinnovative.com

1. Presentation of Case

A case of cholelithiasis in a patient with Haemophilia A which is very intriguing to show the comorbidity. The patient is a 31-year-old male a known case of type 1 haemophilia diagnosed at the age of 21 years. The patient underwent elective laparoscopic cholecystectomy. Chronic inflammatory changes and adhesions were obvious during surgery.

2. Introduction

Haemophilia is a bleeding disorder that occurs due to congenital plasma deficiency clotting protein. Haemophilia A is caused by: Factor VIII deficiency whereas haemophilia B is due to factor IX deficiency and both forms have

X-linked recessive inheritance. So, haemophilia A and B affects only men while women will be a carrier. Affected males have abnormal alleles present on the X chromosome and there is no corresponding allele on the Y chromosome. Their daughters will be obligatory carrier as female carriers have one normal allele, and they usually don't bleed. Over 800 unique Factor VIII mutations genes with point mutations, deletions and insertions have been reported. Deletions and nonsense Mutations are often severe because there is no form of factor VIII is generated.^{1,2}

Gallstones are the primary health issue in developing countries. Gallstones ordinarily arise in women as compared to men in world. Increasing age is a likewise effect on gallstones formation. In contrast among older and more youthful person, gallstones are 10 instances greater common in older than more youthful person. Obesity additionally triggers the formation of gall stones. In symptomatic

* Corresponding author.

E-mail address: sivaram468@gmail.com (S. R. K. Boddu).

gallstones, the maximum clinical manifestation consisting of recurrent right upper quadrant pain which is likewise referred to as epigastric pain. It can be because of consumption of fatty meals and ordinarily arise at night time. And ache can be associated with nausea and vomiting. Fever may also manifest because of infection. Other signs and symptoms mainly jaundice which can also present because of obstruction in bile. There are three types of gallstones - Mixed gallstones, pigment gallstones and cholesterol gallstones. Most common Gallstones in adults are mixed gallstones, whereas in children Pigment stones are more common. Bilirubin can also settle in the gallbladder and forms bilirubin stones referred as cholesterol stones.^{3,4}

3. Background

A 31-year-old male patient referred to department of Pathology haematology section in J.J.M Medical College, Davanagere with the chief complaints of right upper quadrant pain for 6 months. Past history revealed that the patient is a known case of severe haemophilia A diagnosed at the age of 21 years at Karnataka haemophilia society, Davanagere with factor 8 assay of 0.5 and managed conservatively with the help of analgesics and antibiotics and send to Bapuji hospital affiliated to J.J.M Medical College. Investigations revealed mild gallbladder wall thickening with biliary sludge and grade one fatty liver change in ultrasound of abdomen. CECT abdomen and pelvis study revealed cholelithiasis with the features of chronic cholecystitis.

3.1. Preparation for surgery

1. Preoperative evaluation consists of basic coagulation profile which includes APTT, Factor 8 assay, Inhibitor screening and routine investigations such as complete blood count, liver function tests, renal function test and Virals were done.
2. Anti-Haemophilic-Factor (AHF) replacement therapy to achieve normal haemostasis and to maintain haemostatic level.
3. Monitoring of haemostasis - by serial investigations of APTT, factor VIII assay.
4. Patient was counselled and posted for surgery after collaborative discussion among the team consisting of Dept of surgery and Dept of Anaesthesia.

Surgery to be considered only after Negative inhibitors screening test and availability of sufficient AHF concentrates in view of haemophilia 'A'.

1. AHF - 3500 International units (IU) slow IV was infused one hour before to raise haemostatic level of 100%.
2. APTT and Factor VIII assay was done to ensure normal haemostasis activity.

3. AHF - 2000 IU was given 12th hourly for 3 days post procedure to maintain haemostatic activity between 80 - 100%.
4. AHF - 1000 IU was given 12th hourly from day 4 to day 6 post surgery to maintain haemostatic activity between 60-80%.

Table 1: Preliminary investigations

Test	Values	
HB	13g/dl	12-16g/dl
HCT	40.9%	40-48%
TLC	6,800cells/cumm	4000-11000cells/cumm
RBC	4.19million/cumm	4.5-5.0 million/cumm
Platelet count	1.99lakh cells/cu m	1.5-4.5 lakh cells/cu m
MCV	98.0fl	80-99fl
MCH	31.1pg	26-32pg
HBV & HCV	NR	-
HIV	NR	-
Blood urea	14	-
Creatinine	0.7	-
APTT (Control)	34.2 sec	-
APTT (Patient)	71.9 sec	-

Table 2: Mixing studies and factor viii essay

Immediate mix	39.7
Incubated mix (2HRS)	47.1

Table 3: Screening tests for inhibitors - Negative

Test	Post AHF replacement	48hrs Post surgery	5days Post surgery	7 days Post surgery
APTT	33.5 sec	30.5 sec	31.5 sec	38.5 sec
Factor VIII Assay	110 %	79 %	68 %	42 %

3.2. Histopathology examination

3.2.1. Gross

Received a cholecystectomy specimen measuring 7x4x3cms, External surface grey white, congested and cut surface shows bilestained velvety mucosa. Retrieved one black crushable gall stone presenting at neck of gallbladder.

3.2.2. Microscopy

Sections studied from (A, B, C) shows structure of gall bladder with intact mucosa. There is transmural infiltration of chronic inflammatory cell infiltrate comprising of

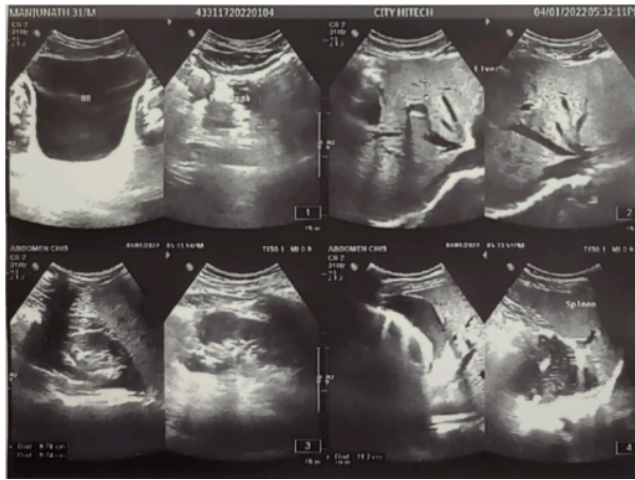


Fig. 1: Ultrasonography of patient revealing Mild Gall bladder wall thickening with biliary sludge

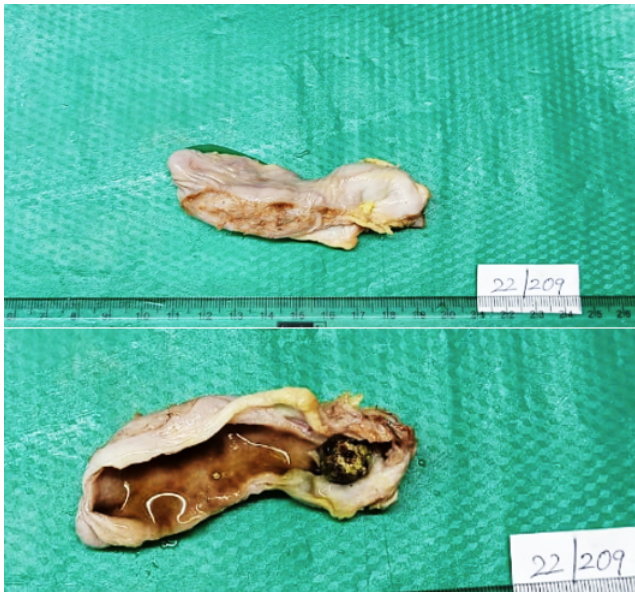

Fig. 2: External and cut surface of resected gall bladder specimen.

lymphocytes. No granuloma/malignancy seen in the sections studied.

3.2.3. Impression

Features are suggestive of chronic calculous cholecystitis.

4. Discussion

A 31-year-old male patient with a known case of haemophilia A diagnosed of chronic cholecystitis posted for laparoscopic cholecystectomy. As the patient was having inherited bleeding disorder, deficient factor is replaced pre-

operatively and haemostasis was maintained postoperatively until 1 week till the wound heals. The main objective of presenting this case is to discuss about the management of surgery in patients with inherited bleeding disorders. As earlier surgeons were hesitant to take up surgeries on known patients with bleeding disorders. But nowadays, availability of antihemophilic factors and expertise in maintaining the haemostasis as build up confidence among surgeons.⁵

5. Conclusion

Inherited bleeding disorders can be managed in Institutions where multidisciplinary specialists are available and the required surgical procedures can be undertaken with coordination and comprehensive approach.

6. Conflict of Interest

The authors declare no relevant conflicts of interest.

7. Source of Funding

None.

References

1. Priyanka M, Saidatta CH, Ramesh S. Case report on haemophilia. *Int J Sci Healthcare Res.* 2018;3(3):118–21.
2. Mistry T, Dogra N, Chauhan K, Shahani J. Perioperative Considerations in a Patient with Hemophilia A: A Case Report and Review of Literature. *Anesth Essays Res.* 2017;11(1):243–5. doi:10.4103/0259-1162.181432.
3. Okamoto A, Yamamoto K, Eguchi G, Kanai Y, Yamaguchi T, Maeda Y, et al. Perioperative management of hemophilia a using recombinant factor VIII in patients undergoing major or minor surgery. *Hemophilia - Recent Advances;* 2019. p. 5.
4. Hellmann AR, Hać S, Kostro J, Śledziński Z, Mital A. Severe complication of acquired hemophilia: active bleeding into the gallbladder resulting in cholecystitis requiring surgery. *Pol Arch Med Wewn.* 2015;125(4):299–300. doi:10.20452/pamw.2792.
5. Andersen MF, Holme PA, Tjønnfjord GE. Kirurgiske inngrep hos pasienter med alvorlig blødersykdom. *Tidsskr Nor Laegeforen.* 1997;139(8). doi:10.4045/tidsskr.18.0592.

Author biography

Siva Rama Krishna Boddu, Post Graduate Resident
<https://orcid.org/0000-0002-5667-9572>

Monish Ram S.D, Post Graduate

Suresh Hanagavadi, Professor

Cite this article: Boddu SRK, Monish Ram S.D, Hanagavadi S. Surgical management in a classical haemophilia patient – A rare case report. *IP Arch Cytol Histopathology Res* 2022;7(3):186-188.