

Content available at: <https://www.ipinnovative.com/open-access-journals>

IP Archives of Cytology and Histopathology Research

Journal homepage: <https://www.achr.co.in/>

## Original Research Article

## Rhabdoid tumor of cheek in an adult patient: A rare case report

Priyanka Verma<sup>1,\*</sup>, Noorin Zaidi<sup>1</sup>, De. Sumaiya Irfan<sup>1</sup>, Andleeb Zehra<sup>1</sup>, Nirupma Lal<sup>1</sup><sup>1</sup>Dept. of Pathology, ERA's Lucknow Medical College & Hospital, Lucknow, Uttar Pradesh, India

## ARTICLE INFO

## Article history:

Received 29-07-2022

Accepted 09-08-2022

Available online 23-09-2022

## Keywords:

H & E – Hematoxylin and Eosin  
 CD99- Cluster of differentiation 99  
 CD 56- Cluster of differentiation 56  
 SALL 4- Spalt Like sal-like

## ABSTRACT

**Introduction:** Rhabdoid tumor is relatively rare highly malignant tumor in adult older than 40 years, therefore treatment regimens often throwing from pediatric age group. It is characterized by extremely aggressive behavior, rapid metastasis to other organ, low survival rate and no targeted therapy. So, early diagnosis is necessary for better treatment and reduce mortality outcome.

**Case Report:** A 42 years male suffering from a right side cheek mass of 5x3cm associated with tongue displacement to left side and difficulty in swallowing. After complete removal of lesion for histopathological examination, revealed grossly the tumor is well defined gray-white, round, lobulated 5x3cm in size having infiltrating borders. Cut surface shows gray-white to gray-brown, solid areas. Microscopically H&E stained section revealed, sheets of tightly packed large, discohesive, polygonal cells having abundant eosinophilic cytoplasm with eccentrically placed round nuclei showing distinct prominent vesicular nucleoli separated by thin fibrous septae with blood vessels. These cells lie in myxoid background. These tumor cells have deeply acidophilic having finely granular abundant cytoplasm with small, peripherally placed nuclei and abundant intra-cytoplasmic vacuoles along with nuclear pleomorphic, no mitotic figure seen.

**Discussion:** Histologically, the adult type tumor proliferating as sheet of tightly packed large, discohesive, polygonal cells having abundant eosinophilic cytoplasm with eccentrically placed round nuclei showing distinct prominent vesicular nucleoli separated by thin fibrous septae with blood vessels lie in fibromyxoid background. These tumor cells have deeply acidophilic, finely granular cytoplasm with small, peripherally placed nuclei with occasional intra-cytoplasmic vacuoles along with cross striations, no mitotic figures seen.

**Conclusion:** Study concludes that adult type Rhabdoid tumors have extremely aggressive behavior, rapid metastasis spread to other organs, low survival rate and no targeted therapy. Usually males older than 40years of age are affected. It is crucial to make a rapid correct diagnosis and early treatment may improve the outcome.

This is an Open Access (OA) journal, and articles are distributed under the terms of the [Creative Commons Attribution-NonCommercial-ShareAlike 4.0 License](https://creativecommons.org/licenses/by-nc-sa/4.0/), which allows others to remix, tweak, and build upon the work non-commercially, as long as appropriate credit is given and the new creations are licensed under the identical terms.

For reprints contact: [reprint@ipinnovative.com](mailto:reprint@ipinnovative.com)

## 1. Introduction

The adult type Rhabdoid tumor is a rare soft tissue tumor and morphologically characteristic tumor.<sup>1</sup> Most cases of Rhabdoid tumor occur in pediatric age group, with few lesions arising in adult older than 40 years. In adult

type Rhabdoid tumor, principal site of involvement is the neck, where the tumor seems to arise from the brachial musculature of the third or fourth brachial plexus. It is found more frequently in the region of the pharynx, oral cavity including the floor of mouth, base of tongue and the larynx. It may also involve the soft palate, vulva usually as an extension of the pharyngeal rhabdomyoma and somatic

\* Corresponding author.

E-mail address: [priyankaverma700756@gmail.com](mailto:priyankaverma700756@gmail.com) (P. Verma).

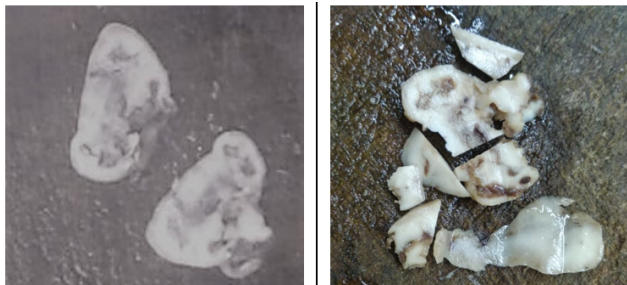muscles of the lateral neck, the lower lip and cheek. Rarely seen in stomach, esophagus and mediastinum.<sup>2</sup>

## 2. Case Report

A 45 years old male patient presented to us with a 2 months history of painless solitary round cheek mass associated with tongue displacement and difficulty in swallowing. His medical history was not significant. The patient was suffering from round cheek mass, progressive, increasing in nature, therefore he visited the hospital. His blood tests including CBC, LFT, KFT, Chest X Ray, Clotting factors were all normal. Oropharyngeal examination revealed a 5x3 cm mass located in the right side cheek area of oral cavity, which was painless associated with displacement of tongue to the left side. Cervical (Upper chain) lymphadenopathy was also present. No metastasis in the lung, brain or other visceral organ was detected in the CT Scans. Biopsy of the Oral Cavity tumor was taken. After that complete removal of oral lesion was done under general anesthesia.

### 2.1. Pathological findings

In the biopsy taken, areas of small cells that form arrays that encircled the surrounding blood vessels are seen. After complete removal of lesion for histological examination, grossly the tumor is well defined, round, multilobulated of 5x3cm in size. Cut surface shows gray-white to gray-brown appearance, solid areas.



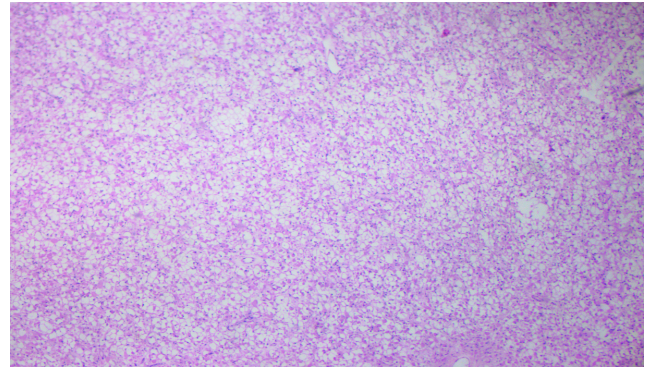
**Fig. 1:** Grossly, the tumor is gray-white to gray-brown, multilobulated of size 5x3 cm. Cut section shows gray-white to gray-brown solid areas.

Microscopically, Hematoxylin & eosin stained section revealed sheets of tightly packed large, discohesive, polygonal cells having abundant eosinophilic cytoplasm with eccentrically placed round nuclei showing distinct prominent vesicular nucleoli separated by thin fibrous septae with blood vessels.<sup>1</sup> The cells lie in myxoid background.<sup>1</sup> These tumor cells have deeply acidophilic, finely granular cytoplasm with small, peripherally placed nuclei with occasional intra-cytoplasmic vacuoles. There are no mitotic figures.<sup>1</sup>

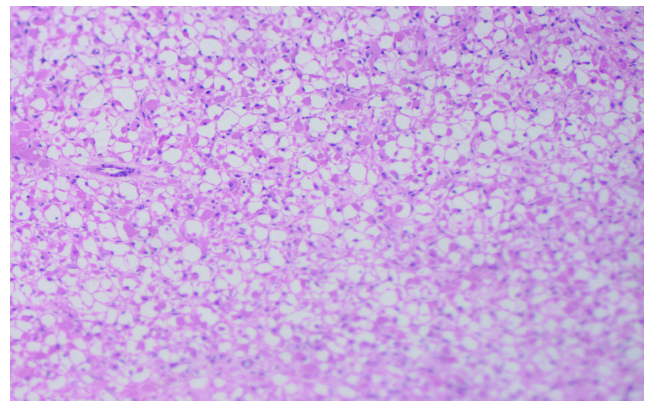
Subsequently, the tumor with a histologic appearance similar to that of tumors arising in the kidney have been

described the skin, soft tissue, gastrointestinal tract, liver, thymus, urogenital tract, thymus and mostly the Central nervous system among others.<sup>3</sup>

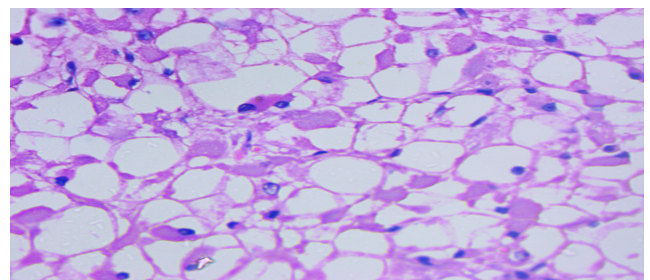
Oil red stain is positive for glycogen vacuoles. Cross-striations can be seen in some cases.<sup>1</sup>



**Fig. 2:** H & E 4X. View of adult Rhabdoid



**Fig. 3:** H & E 10x. view of adult Rhabdoid tumor



**Fig. 4:** H & E 40x. view of adult Rhabdoid tumor

Figure 4 Shows polygonal cells having abundant eosinophilic cytoplasm with eccentrically placed round nuclei showing distinct prominent vesicular nucleoli separated by thin fibrous septae with blood vessels lying in a myxoid background.<sup>1</sup>

### 3. Discussion

Genuine Rhabdoid tumors exclusively belong to the pediatric age group (mean age <1year) and very rarely in adult person. But adult type Rhabdoid tumor occurs approximately in more than 40 years of age (median age- 60 years). Most commonly it occurs due to mutation of 22q11.2, which causes homozygously inactivation of SWI/SNF Related, Matrix Associated, Actin Dependent Regulator of Chromatin, Subfamily B-Member 1 (SMARCB-1) tumor suppressor gene.<sup>4</sup> Less commonly can also occur due to mutation of SWI/SNF Related, Matrix Associated, Actin Dependent Regulator of Chromatin, Subfamily B- Member 4 (SMARCB-4) tumor suppressor gene mutation.<sup>5</sup> Their mutation results in loss of INI 1 expression.<sup>6,7</sup> It most commonly affects kidney and brain but in adult type Rhabdoid tumor principal site of involvement are the skin, soft tissue, neck, pharynx, oral cavity, and larynx. Isolated example has been encountered in the somatic muscle of lateral neck, the lower lip and cheek. As a rule adult type Rhabdoid tumor is well defined, rounded multinodular sessile / pedunculated or coarsely loculated and ranges from 0.5 to 10cm.<sup>1</sup> Adult type Rhabdoid phenotype itself is a poor prognostic factor. Advanced stage and presentation at < 1year of age is associated with poor survival. Extra renal adult type rhabdoid tumor as it pertains of soft tumor with prominent rhabdoid morphology and in which no other clear line of differentiation documented.<sup>3</sup> Clinically extra renal adult type rhabdoid tumor often occur over a much broader age group range than those found in the kidney, although these lesion are far most often in children, occasionally arising as congenital lesions.<sup>3</sup> Extra renal adult type rhabdoid tumor most commonly metastasizes to lung, lymph node, liver in there are stage of disease.<sup>3</sup> The cytoplasmic inclusion most commonly appears eosinophilic in Giemsa and pale gray on Papanicolau stain.<sup>1</sup> Immunohistochemically, these tumor cells of adult type rhabdoid tumor are immunoreactive to EMA (Epithelial membrane antigen), CD99, CD56, SALL-4 and Glypican-3. Are frequently positive.<sup>1</sup> These cells also show loss of nuclear IN1 (most diagnostic), S-100, Desmin, Myogenin (skeletal differentiation marker).<sup>1</sup> As it is severely aggressive tumor, 5 years survival rate is less than 15% - 20% unconcern of the type of therapy.<sup>3</sup>

### 4. Conclusion

Adult Rhabdoid tumors are extremely aggressive tumors that can occur at multiple anatomical locations and usually occur in males older than 40 years.<sup>8</sup> It is crucial to make a rapid correct diagnosis and early treatment may improve the outcome and reduce mortality.

### 5. Conflict of Interest

The authors declare no relevant conflicts of interest.

### 6. Source of Funding

None.


### References

1. Goldblum J, Weiss S, Folpe AL. Enzinger and Weiss's soft tissue tumors. 7th Edn. Philadelphia PA, USA: Elsevier; 2020. p. 1304.
2. Wu WW, Bi WL, Kang YJ, Ramkissoon SH, Prasad S, Shih HA, et al. Adult atypical teratoid/rhabdoid tumors. *World Neurosurgery*. 2016;85:197–204. doi:10.1016/j.wneu.2015.08.076.
3. Yang X, Xi C, Jin J, Zhou L, Su J, Liu L, et al. Adult renal cell carcinoma with rhabdoid differentiation: incidence and clinicopathologic features in Chinese patients. *Ann Diagn Pathol*. 2015;19(2):57–63. doi:10.1016/j.anndiagpath.2015.01.006.
4. Holdhof D, Johann PD, Spohn M, Bockmayr M, Safaei S, Joshi P, et al. Atypical teratoid/rhabdoid tumors (ATRTs) with SMARCA4 mutation are molecularly distinct from SMARCB1-deficient cases. *Acta Neuropathologica*. 2021;141(2):291–301. doi:10.1007/s00401-020-02250-7.
5. Chan V, Marro A, Findlay JM, Schmitt LM, Das S. A systematic review of atypical teratoid rhabdoid tumor in adults. *Front Oncol*. 2018;8:567. doi:10.3389/fonc.2018.00567.
6. Parker NA, Al-Obaidi A, Deutsch JM. SMARCB1/INI1-deficient tumors of adulthood. *F1000Res*. 2020;9:662. doi:10.12688/f1000research.24808.2.
7. Lutterbach J, Liegibel J, Koch D, Madlinger A, Frommhold H, Pagenstecher A, et al. Atypical Teratoid/rhabdoid Tumors in Adult Patients: Case Report and Review of the Literature. *J Neuro-Oncol*. 2001;52(1):49–56. doi:10.1023/A:1010683416555.
8. Heck JE, Lombardi CA, Cockburn M, Meyers TJ, Wilhelm M, Ritz B, et al. Epidemiology of rhabdoid tumors of early childhood. *Pediatr Blood Cancer*. 2013;60(1):77–85. doi:10.1002/pbc.24141.

### Author biography

**Priyanka Verma**, Junior Resident  <https://orcid.org/0000-0003-2238-2962>

**Noorin Zaidi**, Assistant Professor  <https://orcid.org/0000-0003-3182-4777>

**De. Sumaiya Irfan**, Assistant Professor  <https://orcid.org/0000-0001-7994-4132>

**Andleeb Zehra**, Assistant Professor

**Nirupma Lal**, Professor and HOD

**Cite this article:** Verma P, Zaidi N, Irfan DS, Zehra A, Lal N. Rhabdoid tumor of cheek in an adult patient: A rare case report. *IP Arch Cytol Histopathology Res* 2022;7(3):189-191.