

Content available at: <https://www.ipinnovative.com/open-access-journals>

IP Archives of Cytology and Histopathology Research

Journal homepage: <https://www.achr.co.in/>

## Case Report

# Diagnostic surprise on IHC: A rare case of intramuscular DLBCL in thigh region mimicking sarcoma

Shabana A. Ansari<sup>1</sup>, Tanu Agrawal<sup>1,\*</sup>, Swarneet Bhamra<sup>1</sup>

<sup>1</sup>Dept. of Pathology, Shri Ram Murti Smarak Institute of Medical Sciences, Bareilly, Uttar Pradesh, India



### ARTICLE INFO

#### Article history:

Received 22-07-2022

Accepted 03-08-2022

Available online 23-09-2022

#### Keywords:

Soft tissue sarcoma

Diffuse large B cell lymphoma

(DLBCL)

Immunohistochemistry

### ABSTRACT

Soft tissue sarcomas are broad group of malignant tumours that arise in tissues like fat, muscle, nerves, fibrous tissue and blood vessels. A variety of non mesenchymal neoplasms like sarcomatoid carcinomas, melanomas and extranodal lymphomas may also mimic soft tissue sarcoma. Diffuse Large BCell Lymphoma is the most common type of Non HodgkinsLymphoma accounting for around 30-40% of cases. DLBCL involving skeletal muscle is extremely rare accounting approximately <1% of the cases with most of the cases reported in the lower extremity involving calf and thigh region. Here we report a case of DLBCL of the left thigh mass in 60 years old male which was initially thought to be a sarcoma based on clinical findings and imaging, but was later diagnosed to be DLBCL after surgical excision of the mass with the help of histopathology and immunohistochemistry.

This is an Open Access (OA) journal, and articles are distributed under the terms of the [Creative Commons Attribution-NonCommercial-ShareAlike 4.0 License](https://creativecommons.org/licenses/by-nc-sa/4.0/), which allows others to remix, tweak, and build upon the work non-commercially, as long as appropriate credit is given and the new creations are licensed under the identical terms.

For reprints contact: [reprint@ipinnovative.com](mailto:reprint@ipinnovative.com)

## 1. Introduction

Diffuse Large B Cell Lymphoma is the most common type of Non Hodgkins Lymphoma accounting for around 30-40% of cases.<sup>1</sup> The primary site for DLBCL is lymph node, however extra nodal involvement has been seen in many cases with gastrointestinal tract is the most common site.<sup>2</sup> Other sites are skin, soft tissue, bone, central nervous system and genitourinary system. It affects all ages but incidence is higher in elderly people around sixth to seventh decade of life. Soft tissue sarcomas are broad group of malignant tumours that arise in tissues like fat, muscle, nerves, fibrous tissue and blood vessels. A variety of non mesenchymal neoplasms like sarcomatoid carcinomas, melanomas and extranodal lymphomas may also mimic soft tissue sarcoma. DLBCL involving skeletal muscle is extremely rare accounting approximately <1% of the cases with most of the cases reported in the lower extremity

involving calf and thigh region.<sup>1,3,4</sup> Here we report a case of DLBCL of the left thigh mass in 60 years old male which was initially thought to be a sarcoma based on clinical findings and imaging, but was later diagnosed to be DLBCL after surgical excision of the mass with the help of histopathology and immunohistochemistry.

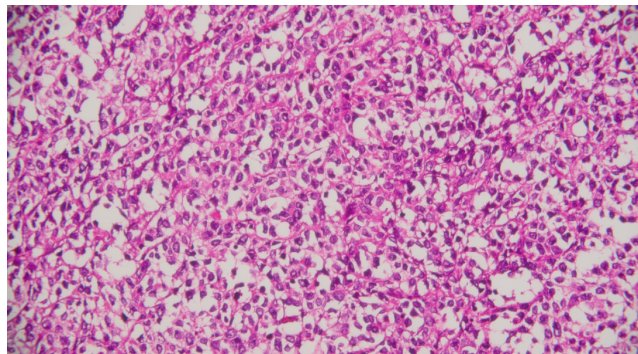
## 2. Case Report

60 years old male patient presented with left thigh mass which was slow growing and painless. MRI revealed heterogeneously enhancing intramuscular neoplasm in the posterior compartment of left lower thigh. FNAC was suggestive of highly suspicious of malignancy. Patient was underwent wide local excision. Grossly the tumour was fleshy and tan white measuring 11.5x8.5x7.5 cms in size. Microscopic examination revealed diffuse proliferation of medium to large sized lymphoid cells having round to oval hyperchromatic nuclei with irregular nuclear membrane, vesicular chromatin and conspicuous

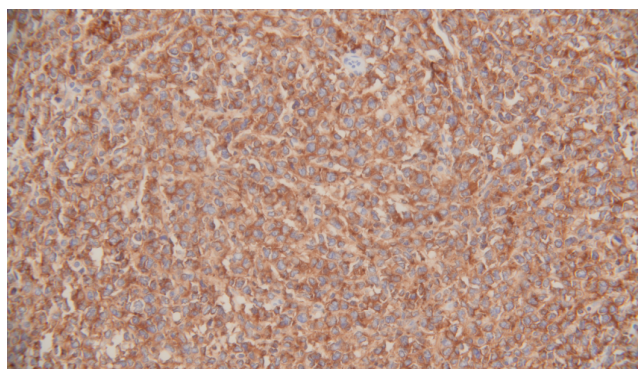
\* Corresponding author.

E-mail address: [tanuagrawal510@yahoo.co.in](mailto:tanuagrawal510@yahoo.co.in) (T. Agrawal).

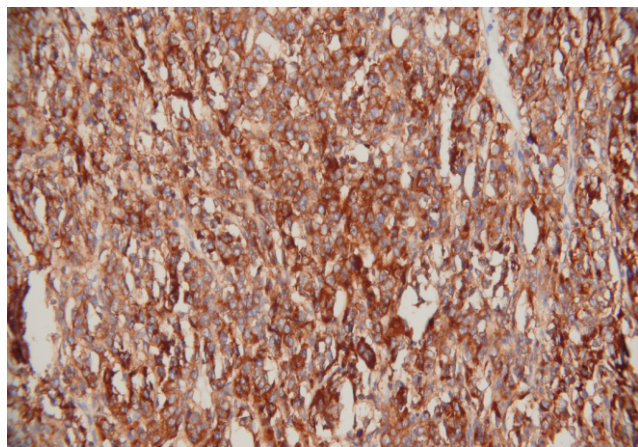
nucleoli. Immunohistochemistry revealed strong and diffuse positivity for CD 45, CD 20 and CD10 while tumour cells were negative for Vimentin, Desmin, ALK, S100, PanCK, CD 99, CD3 and HMB45. On the basis of morphological features and IHC, the diagnosis of Diffuse large B Cell Lymphoma (DLBCL) was made. (Figures 1, 2, 3 and 4)



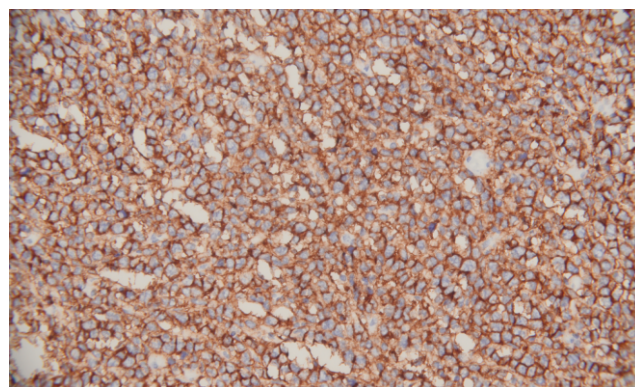
**Fig. 1:** Sheets of atypical lymphoid cells (H&E, 400X)



**Fig. 2:** Strong and diffuse CD 45 positivity in tumour cells (400X)



**Fig. 3:** Strong and diffuse CD 10 positivity in tumour cells (400X)



**Fig. 4:** Strong and diffuse CD 20 positivity in tumour cells (400X)

### 3. Discussion

Diffuse Large B Cell Lymphoma is the most common type of Non Hodgkins Lymphoma but extremely rare in the skeletal muscle.<sup>1</sup> Few cases involving both upper and lower extremities have been reported in the literature, where they were initially thought to be sarcomas and ultimately diagnosed as non hodgkin's lymphoma after excision biopsy.<sup>2</sup> Bolke et al<sup>5</sup> reported the same case as ours in a 78 years old man who was presented with an extensive tumour located on the right thigh. Siddiqui et al<sup>2</sup> reported a case of DLBCL in 64-year-old woman presented with a five-month history of an enlarging mass in left upper extremity associated with pain and redness. MRI of which revealed two masses, one was located in deep soft tissue between the biceps and triceps muscle and other mass was present in the subcutaneous tissue of the distal posterior part of left arm. Gupta et al<sup>6</sup> reported a case of left inguinal swelling and ulcer that mimicked sarcoma based on history and clinical presentation but biopsy established the diagnosis of primary cutaneous B-cell lymphoma. Mamorska-Dyga et al<sup>7</sup> and Mayo et al<sup>8</sup> reported a case of DLBCL involving upper extremity. Since there are various genetic sub types of DLBCL which may have different prognoses and treatment responses. Further research on this domain may have immense impact on the therapeutic modalities of these patients. Our case signifies the importance of including lymphoma in differential diagnosis of sarcoma of extremities. This will avoid unnecessary surgical excision and delay in appropriate treatment as sarcomas are generally treated by surgical excision followed by radiotherapy while lymphomas require chemotherapy.<sup>9</sup>

### 4. Conclusion

Histopathology is the gold standard while immunohistochemistry adds further accuracy in the diagnosis of rare tumours or tumours of unusual location. Here we reported a case which was mimicking sarcoma on the basis of clinical history, physical examination and

imaging but diagnosis was made as diffuse large B cell lymphoma on the basis of histopathological features and immunohistochemistry. Thorough histological evaluation with ancillary studies like immunohistochemistry play a key role in the diagnosis of soft tissue tumours and prevent misdiagnosis which may have significant clinical and therapeutic implication.

## 5. Conflict of Interest

The authors declare no relevant conflicts of interest.

## 6. Source of Funding

None.

## References

- Hatem J, Bogusz AM. An Unusual Case of Extranodal Diffuse Large B-Cell Lymphoma Infiltrating Skeletal Muscle: A Case Report and Review of the Literature. *Case Rep Pathol.* 2016;p. 9104839. doi:10.1155/2016/9104839.
- Siddiqui RS, Ferman D, Tuli S. Diffuse Large B-Cell Lymphoma of the Left Upper Extremity Mimicking a Sarcoma. *Cureus.* 2021;13(6):e15588. doi:10.7759/cureus.15588.
- Bourdeanu L, Menon R, Somlo G. Diffuse large B-cell lymphoma with calf muscle localization. *Case Rep Hematol.* 2011;p. 292494. doi:10.1155/2011/292494.
- Alamdari A, Naderi N, Peiman S, Shahi F. Non-Hodgkin lymphoma with primary involvement of skeletal muscle. *Int J Hematol Oncol Stem Cell Res.* 2014;8(3):55–7.
- Bolke E, Peiper M, Matuschek C, Schieren G, Glombick R, Förster C, et al. Extranodal Diffuse Non Hodgkin Lymphoma in the Thigh. *Eur J Med.* 2010;15(8):367–8. doi:10.1186/2047-783x-15-8-367.
- Gupta P, Agarwal P, Ahuja A, Durga CK. Primary cutaneous non-Hodgkin's lymphoma, clinically mimicking a soft tissue sarcoma. *Cytojournal.* 2018;15(2).
- Mamorska-Dyga A, Ronny FM, Puccio C, Islam H, Liu D. A rare case of the upper extremity diffuse large B-cell lymphoma mimicking soft tissue sarcoma in an elderly patient. *Stem Cell Investig.* 2016;3:25. doi:10.21037/sci.2016.06.06.
- Mayo J, Bogenberger K, Raj T, Reha J. Subcutaneous mass concerning for sarcoma: a peculiar presentation of diffuse large B-cell lymphoma. *BMJ Case Rep.* 2019;12(7):e229327. doi:10.1136/bcr-2019-229327.
- Hoefkens F, Dehandschutter C, Somville J, Meijnders P, Van Gestel D. Soft tissue sarcoma of the extremities: pending questions on surgery and radiotherapy. *Radiat Oncol.* 2016;11:136. doi:10.1186/s13014-016-0668-9.

## Author biography

**Shabana A. Ansari**, Assistant Professor

**Tanu Agrawal**, Professor

**Swarneet Bhamra**, Senior Resident

**Cite this article:** Ansari SA, Agrawal T, Bhamra S. Diagnostic surprise on IHC: A rare case of intramuscular DLBCL in thigh region mimicking sarcoma. *IP Arch Cytol Histopathology Res* 2022;7(3):205-207.