

Content available at: <https://www.ipinnovative.com/open-access-journals>

IP Archives of Cytology and Histopathology Research

Journal homepage: <https://www.achr.co.in/>

Editorial

Collecting duct carcinoma (Bellini Duct Carcinoma) of kidney-An overview

Dhiraj B Nikumbh ^{1,*}

¹Dept of Pathology, SBH, Government Medical College, Dhule, Maharashtra, India



ARTICLE INFO

Article history:

Received 25-11-2022

Accepted 28-11-2022

Available online 30-11-2022

Keywords:

Bellini duct

Renal

Carcinoma

Variants

ABSTRACT

Renal cell carcinoma (RCC) accounts for more than eighty-five percent of primary renal cell carcinomas with male preponderance in 5th to 7th decades. Collecting duct carcinoma (CDC) constitutes for less than 1% of all renal cell carcinomas. Histopathological examination of all types of RCC is almost importance in view of therapeutic and prognostic implications of its varied subtypes. The purpose of this editorial is to highlight the morphology and rarity of collecting duct carcinoma and differentiation of it from papillary renal cell carcinoma.

This is an Open Access (OA) journal, and articles are distributed under the terms of the [Creative Commons Attribution-NonCommercial-ShareAlike 4.0 License](https://creativecommons.org/licenses/by-nc-sa/4.0/), which allows others to remix, tweak, and build upon the work non-commercially, as long as appropriate credit is given and the new creations are licensed under the identical terms.

For reprints contact: reprint@ipinnovative.com

We received a large left radical nephrectomy specimen of a 65/male for histopathology. Radiological and clinical diagnosis was renal cell carcinoma (RCC).Grossly nephrectomy specimen measured 22x20x10 cms with globular rounded and bulging areas on gross (Figure 1). On c/s-variegated tumor occupying mainly medulla but infiltrating whole of the parenchyma was noted with focal infiltrative viable satellite nodules of tumor (Figure 2). Extensive areas of hemorrhages and necrosis was noted. Renal pelvis showed extensive necrosis with no viable renal veins. Capsule is stripped of at focal areas with adherent at many places. The attached fibroadipose tissue showed no evidence of tumor deposits.

Light microscopy from representative multiple sections showed large areas of tumor necrosis with foci of complex infiltrative and poorly circumscribed tumor. The tumor is composed of cords, tubules, tubulopapillary or tubulocystic structures embedded into inflamed desmoplastic stroma (Figure 3). Focal irregular channels are lined by high grade cuboidal to hobnail cells with eosinophilic cytoplasm was

noted (Figure 4). The tumor cells were large round to oval with large pleomorphic nuclei and prominent nucleoli and coarse chromatin. Numerous mitotic figures, focal neoplastic spindle cells with sarcomatoid morphology were evident. Focal rhabdoid morphology of tumor cells noted. Final histopathological diagnosis was given as Collecting duct carcinoma with G3(WHO)/pT3a grade.IHC was not performed as patient was referred for higher center for chemotherapy.

Renal cell carcinoma (RCC) accounts for more than eighty five percent of primary renal cell carcinomas with male preponderance and in 5th to 7th decades.¹ Collecting duct carcinoma (CDC) constitutes for less than 1% of all renal cell carcinomas.² Histopathological examination of all types of RCC is almost importance in view of aggressive nature, therapeutic and prognostic implications of its varied subtypes.¹⁻³ The carcinoma arises from the principal cells of the distal collecting ducts of Bellini hence the historic name was Bellini duct carcinoma and it was not used now a days.

In between 5 distinct subtypes of RCC, Collecting duct carcinoma has very aggressive course with mortality of 70% in two years as per Muglia VF et al.⁴ CDC, basically

* Corresponding author.

E-mail address: drdhirajnikumbh@gmail.com (D. B. Nikumbh).

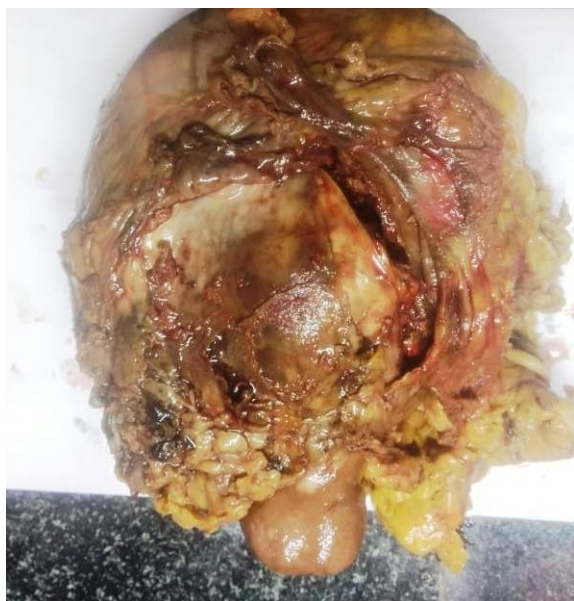

Fig. 1: Gross appearance of globular nephrectomy specimen.

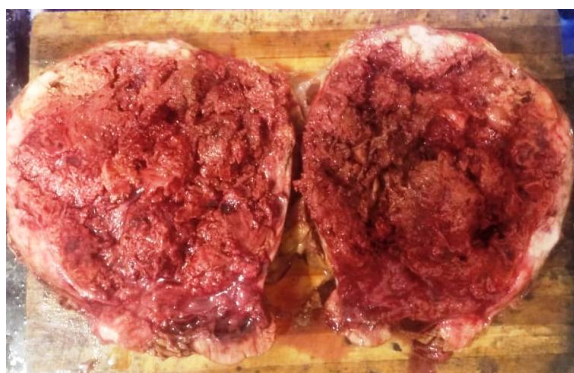

Fig. 2: Cut section of nephrectomy with extensive variegated tumor involving medulla and whole of parenchyma.

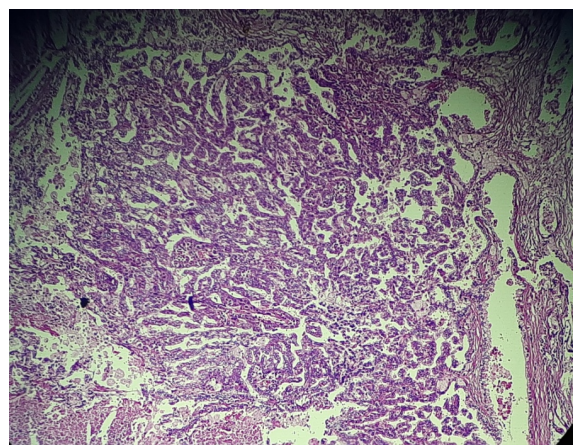


Fig. 3: Microphotograph of tumor composed of cords, tubules, tubulopapillary or tubulocystic structures embedded into inflamed desmoplastic stroma. (H&E,x100)

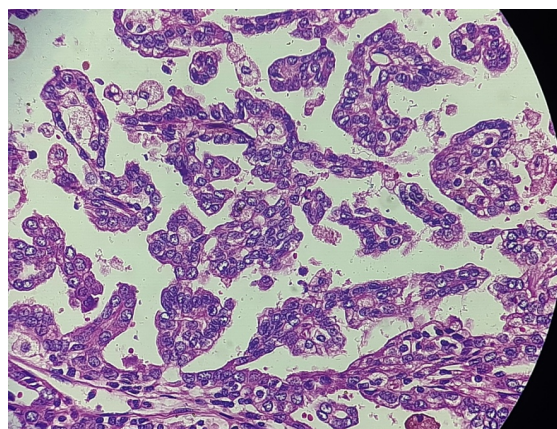


Fig. 4: Large round to oval tumor cells with pleomorphic nuclei with focal irregular channels are lined by high grade cuboidal to hobnail cells with eosinophilic cytoplasm. (H&E,x400)

is tumor (adenocarcinoma) with 2 components. First component is major tumor with papillary and fibrovascular core and other component consist of invasive glandular elements with marked desmoplastic reaction with columnar tumor cells with varied pleomorphism.¹

Major diagnostic criteria to define CDC pathologically –are 1) location of tumor in a medulla (small ones), 2) typical tubular, irregular tubulopapillary histology, desmoplasia and high grade, 3) reactive with antibodies to HMWK, Ulex europaeus lectin and 4) absence of urothelial carcinoma.^{1,5}

Minor criteria are- 1) Central location (large ones), 2) papillary architecture with wide, fibrous stalk and desmoplastic stroma, 3) inflammatory stroma with neutrophils and 4) extensive renal, extrarenal and vascular infiltration.^{1,5}

Immunohistochemistry (IHC) of tumor cells of CDC was strongly positive for PAX-8, GATA-3, EMA, and CK weakly. CK-7, CD10 and 34BE12 was immune-negative.^{1,5}

The aim of this editorial is to distinguish CDC from papillary RCC as its importance in view of therapy and prognosis. But both the tumors share some pathological features including papillary architecture and some immunomarkers.^{1,5}

Papillary RCC constitutes 10% of renal cell carcinomas with distinct morphology with indolent prognosis. Both papillary RCC and CDC show papillary architecture and positive immunoreaction with distal nephron markers.⁶ Grossly, papillary RCC tends to be more well circumscribed and has a yellow to dark-brown cut surface; its center should be in the renal cortex as opposed to the medulla.⁶ Microscopically, atypia in adjacent collecting duct cells, marked stromal desmoplasia, and the presence of mucin favor CDC although mucin can be seen in papillary RCC as well. Immunohistochemically, CK 7, CD10, racemase, RCC and N-cadherin positivity favor papillary RCC while ulex

europaeus-1, e-cadherin, and high molecular weight keratin 34betaE1 positivity favor CDC.⁶

Rarely synchronous CDC and papillary RCC occurs in the same kidney by some authors.⁷ Collecting duct carcinoma is essentially diagnosis of exclusion after ruled out other RCCs like medullary and papillary RCC, urothelial carcinomas and metastatic adenocarcinomas.⁷

Conflict of Interest


None.

References

1. Yoon SK, Rha SH. Collecting duct carcinoma. In: Guermazi A, editor. Imaging in kidney cancer. Berlin: Springer- Verlag; 2003. p. 171–85.
2. Harbin AC, Styskel BA, Patel V, Wang H, Eun DD. Collecting Duct Renal Cell Carcinoma Found to Involve the Collecting System During Partial Nephrectomy: A Case Report. *J Kidney Cancer VHL*. 2015;2(3):134–9.
3. Hu YU, Zhou H, Wang G, Song Z, Zhao C, Wang Y, et al. Collecting duct carcinoma of the kidney: A case report. *Oncol Lett*. 2015;9(6):2902–4.
4. Muglia VF, Prando A. Renal cell carcinoma: histological classification and correlation with imaging findings. *Radiol Bras*. 2015;48(3):166–74. doi:10.1590/0100-3984.2013.1927.
5. Syed Z, Chaturvedi A, Bashir W. Collecting duct carcinoma of kidney in a teenage boy. *Oncol, Gastroenterol Hepatol Rep*. 2016;5(1):24. doi:10.4103/2348-3113.172529.
6. Jorda M, Manoharan M. Collecting Duct Carcinoma of Kidney: Differential Diagnosis of Neoplasms Involving the Renal Medulla. *Pathol Case Rev*. 2006;11(4):191–6. doi:10.1097/01.pcr.0000227452.50951.
7. Arik D, Açıkalın MF, Can C. Papillary renal cell carcinoma and collecting duct carcinoma combination. A case report and review of synchronous renal cell carcinoma subtypes in the same kidney. *Arch Med Sci*. 2015;11(3):686–90.

Author biography



Dhiraj B Nikumbh, Associate Professor
Dept. of Pathology
SBH, Government Medical College, Dhule,
Maharashtra, India.
Editor-In-Chief: IP Archives of Cytology
and Histopathology Research (IP ACHR)
 <https://orcid.org/0000-0002-7440-9007>

Cite this article: Nikumbh DB. Collecting duct carcinoma (Bellini Duct Carcinoma) of kidney-An overview. *IP Arch Cytol Histopathology Res* 2022;7(4):211-213.