



## Case Report

# Multilocular cystic renal cell carcinoma of low malignant potential- A rare case report

Vidya Bhat <sup>1,\*</sup>

<sup>1</sup>Dept. of Pathology, Manipal Hospital, Bangalore, Karnataka, India



## ARTICLE INFO

### Article history:

Received 27-07-2022

Accepted 21-07-2022

Available online 30-11-2022

### Keywords:

Kidney

Multilocular cyst

Renal cell carcinoma

## ABSTRACT

Multilocular cystic renal neoplasm of low malignant potential (MCRCC) by definition is "Neoplasm composed entirely of numerous cysts, the septa of which contain individual or groups of clear cells without expansile growth" according to WHO 2016 classification. In 2016 WHO separates this neoplasm of low malignant potential from cystic renal cell carcinomas which have some overlapping morphologic features. Tumor exhibits low stage and low -grade characteristics and is a special type of RCC. We report this case in a 49 year old male patient for its rarity and also to know the importance of it to identify and differentiate from its mimicks.

This is an Open Access (OA) journal, and articles are distributed under the terms of the [Creative Commons Attribution-NonCommercial-ShareAlike 4.0 License](https://creativecommons.org/licenses/by-nc-sa/4.0/), which allows others to remix, tweak, and build upon the work non-commercially, as long as appropriate credit is given and the new creations are licensed under the identical terms.

For reprints contact: [reprint@ipinnovative.com](mailto:reprint@ipinnovative.com)

## 1. Introduction

Multilocular cystic renal cell carcinoma (MCRCC), also known as multilocular clear cell renal cell carcinoma (RCC), is a rare cystic tumor of the kidney with an excellent outcome. It occurs in about 3.1-6% of the conventional RCC.<sup>1-3</sup> It is usually included in the group of tumors of undetermined malignant potential with low nuclear grade. Adult patients are eight times more likely to be female and most often present with flank mass, abdominal pain, or hematuria.<sup>3,4</sup>

## 2. Case Details

A 49 year old male patient presented to the department of urology with complaints of left sided abdominal distension since 2years. Investigations- Urinalysis didn't reveal any obvious abnormalities, urine cytology revealed an inflammatory process. Laparoscopic left radical nephrectomy was done and specimen was sent to the department of pathology. We received a specimen


of left nephrectomy in formalin, with perirenal fat totally measuring 15x9.5x5 cm. The lower pole of the kidney appeared bosselated and on cut section revealed a multiloculated cystic neoplasm measuring 6x5 cm (Figure 1). The tumor appeared multiseptate, vareigated and well encapsulated with a non- communicating cysts ranging in size from 0.1 to 0.7 cm. The cysts were filled with straw coloured fluid. No other solid nodules or papillary projections seen.

### 2.1. Microscopy

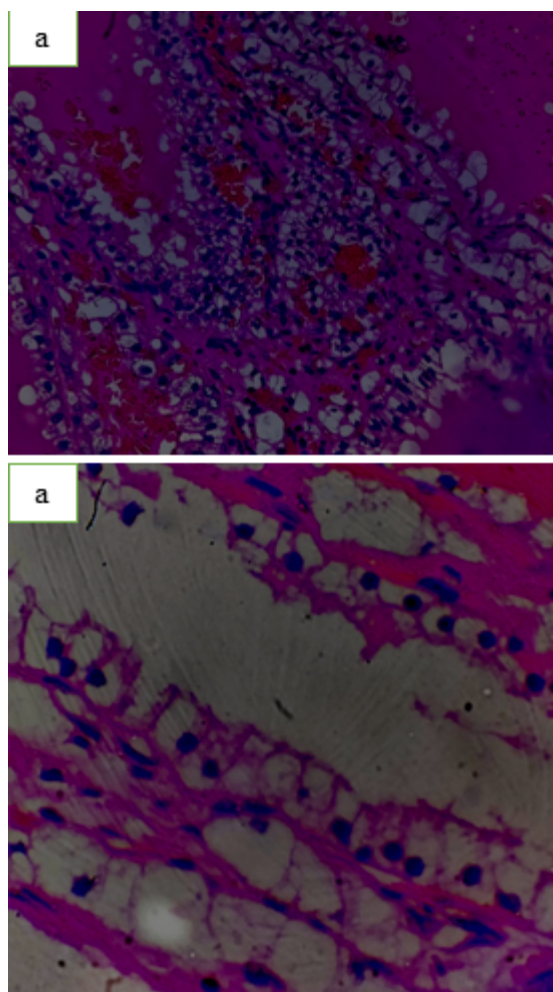
Sections revealed a multicystic tumor seperated by thick fibrous septae. These septae were lined by cells which were cuboidal to low columnar with clear cytoplasm (Figure 2a). These clear cells had a small hyperchromatic nucleus with minimal anisonucleosis and inconspicuous nucleoli with Furhman nuclear grade of 1 or 2. There was no mitosis seen (Figure 2b). There was no tumor invasion into adjacent renal parenchyma, and the tumour cells were limited to the kidney capsule, and no extension to the major vessels as well as perinephric fat. There was no

\* Corresponding author.

E-mail address: [vidya.baliga.76@gmail.com](mailto:vidya.baliga.76@gmail.com) (V. Bhat).



**Fig. 1:** Left radical nephrectomy specimen with multicystic tumor at lower pole



**Fig. 2:** **a:** H& E,10X Cystic spaces lined by low cuboidal clear cells, **b:** H&E,40X, Clear cells with low grade nuclei.

associated tumor necrosis/infiltration into the ureter. No sarcomatoid/rhabdoid features were seen. Based on these findings, a diagnosis of multilocular cystic clear cell renal neoplasm of low malignant potential was given with following staging pT1NxMx.

### 3. Discussion

Multilocular cystic renal cell carcinoma of low malignant potential (MCRCC) has a very low incidence of < 2% and first reported by Perlmann in 1928 and named it as lymphangiohemangioma.<sup>1</sup>

Tumor has a low incidence accounts for about 1- 2% of all renal neoplasms<sup>1</sup> and about 3.1 to 6% of clear cell RCC as per a study done by Chowdhary et al.<sup>1,2</sup> They have been found patients with a mean age of 51 years and affects individuals of the age group 20 to 76.<sup>1,2</sup> The males are more commonly affected than females with a male to female ratio of 3:1.<sup>3</sup>

The 2004 WHO classification recognizes MCRCC as a rare variant of clear cell RCC with a good prognosis.[shivakumaraswamy et al]. Some of the differential diagnoses that were considered consisted of other cystic lesions of kidney, including tubulocystic carcinoma, primary cystic nephroma, extensively cystic clear cell RCC, and clear cell papillary RCC. Tubulocystic carcinoma differs from MCRCC in that the cystic spaces are lined by flat cuboidal and sometimes hobnail-type cells with eosinophilic cytoplasm and variable nuclear atypia, usually with nucleolar prominence in the range of Fuhrman Grade 2 or 3, which is incompatible with MCRCC. In addition, the septal lining of tubulocystic carcinoma do not harbor clusters of clear cells.<sup>3</sup> Cystic nephroma may have few clear cells lining the septae, they are more focal and donot have a diffuse arrangement. In clear cell papillary neoplasm, papillary fronds are prominent, whereas in MCRCC do not show papillary pattern. In 2016, the WHO published a new classification on renal tumors, and as per the evidence and data collected they had termed this tumor as MCRN-LMP

Multilocular cystic clear cell renal neoplasm of low malignant potential is a tumors having good prognosis. As seen in a study by Li et al, which studied 76 patients, there was no recurrence of tumors in the patients on follow up.<sup>5</sup> In a study done by Murad et al, it was concluded that the tumor was a low grade variant of RCC.<sup>4</sup> In a large series done by Suzigan et al it was found that 82% of their cases were in the T1 stage with a low nuclear grade in 62% cases and a 100% 5 year survival rate.<sup>1,2,6</sup>

Even though majority of case reports have reported a low malignant potential of this tumour, in 2010 Walsh et al reported the first case of this tumour metastasizing to one out of 7 intra aortocaval lymph nodes.<sup>7,8</sup>

#### 4. Conclusions

Multilocular cystic clear cell renal neoplasm of low malignant potential is now recognised as a separate entity as per the WHO classification of 2016. This tumour has shown an indolent behaviour in the previous cases. We report this case as, identification and diagnosis of this rare tumor helps the patient as it has a good prognosis.

#### 5. Source of Funding

None.

#### 6. Conflicts of Interest

There is no conflict of interest.

#### References

1. Chowdhury AR, Chakraborty D, Bhattacharya P, Dey RK. Multilocular cystic renal cell carcinoma a diagnostic dilemma: A case report in a 30-year-old woman. *Urol Ann.* 2013;5(2):119–21.
2. Eble JN, Bonsib SM. Extensively cystic renal neoplasms: cystic nephroma, cystic partially differentiated nephroblastoma, multilocular cystic renal cell carcinoma, and cystic hamartoma of renal pelvis. *Semin Diagn Pathol.* 1998;15(1):2–20.
3. Udasimath S, Niranjana J, Puruhotham R, Nagesha KR. Multilocular cystic renal cell carcinoma in a 23 year old female. *Urol Ann.* 2016;8(4):506–8. doi:10.4103/0974-7796.192095.
4. Murad T, Komaiko W, Oyasu R, Bauer K. Multilocular cystic renal cell carcinoma. *Am J Clin Pathol.* 1991;95(5):633–7. doi:10.1093/ajcp/95.5.633.
5. Li T, Chen J, Jiang Y, Ning X, Peng S, Wang J, et al. Multilocular Cystic Renal Cell Neoplasm of Low Malignant Potential: A Series of 76 Cases. *Clin Genitourin Cancer.* 2016;14(6):553–7. doi:10.1016/j.clgc.2016.03.017.
6. Suzigan S, Lopez-Beltran A, Montironi R, Drut R, Romero A, Hayashi T, et al. Multilocular cystic renal cell carcinoma: a report of 45 cases of a kidney tumor of low malignant potential. *Am J Clin Pathol.* 2006;125(2):217–22. doi:10.1309/AH6F-C77P-YR2V-6YAY.
7. Walsh TJ, Naik P, Sweeney P, Fitzgibbon J, Murphy M. Metastatic multilocular cystic renal cell carcinoma - Malignant cells clearly a treatment dilemma. *J Lab Physicians.* 2014;6:50–2.
8. Wahal SP, Mardi K. Multilocular cystic renal cell carcinoma: a rare entity with review of literature. *J Lab Physicians.* 2014;6(1):50–2.

#### Author biography

**Vidya Bhat**, Consultant Pathologist  <https://orcid.org/0000-0002-2393-6077>

**Cite this article:** Bhat V. Multilocular cystic renal cell carcinoma of low malignant potential- A rare case report. *IP Arch Cytol Histopathology Res* 2022;7(4):258-260.