



Case Report

Immunohistochemical markers in differential diagnosis of endometrial stromal sarcoma and leiomyosarcoma in an endometrial polyp: A case report

Shana Nikhat Khan¹, Ekta Patidar¹, Ranjana Hawaldar^{1,*}

¹Dept. of Pathology, SampurnaSodani Diagnostic Clinic, Indore, Madhya Pradesh, India



ARTICLE INFO

Article history:

Received 20-01-2023

Accepted 21-02-2023

Available online 11-03-2023

Keywords:

Leiomyosarcoma

Postmenopausal bleeding

Endometrial polyp

Immunohistochemistry

ABSTRACT

Leiomyosarcoma is the malignant counterpart of leiomyoma. It arises from smooth muscle of the uterus and is rare tumor that account for 2-5% of all uterine malignancy. We report a case of 60 years old female who presented with post menopausal bleeding with endometrial polyp. A total abdominal hysterectomy specimen was received in our center. A differential diagnosis of leiomyosarcoma/Endometrial stromal sarcoma was made by histopathological examination. Immunohistochemistry report confirmed the diagnosis of uterine Leiomyosarcoma.

This is an Open Access (OA) journal, and articles are distributed under the terms of the [Creative Commons Attribution-NonCommercial-ShareAlike 4.0 License](https://creativecommons.org/licenses/by-nc-sa/4.0/), which allows others to remix, tweak, and build upon the work non-commercially, as long as appropriate credit is given and the new creations are licensed under the identical terms.

For reprints contact: reprint@ipinnovative.com

1. Introduction

Leiomyosarcoma is the malignant counterpart of leiomyoma. Leiomyosarcoma occurs mainly after menopause, an older average age group than leiomyomas (median age, 54 years) although they can also occur in younger patients.¹ It is the most common sarcoma of the uterus, with incidence of 2 to 3 for every 1,000 women with leiomyomata. African Americans have higher occurrence rate.²

Some epidemiologic findings in patients with leiomyosarcoma parallel those from studies in endometrial carcinoma and suggest a role for unopposed estrogen stimulation.³ The genetics of leiomyosarcomas have confirmed that they do not arise from leiomyoma.

The relative rarity and pathological diversity makes it difficult to define the optimum management. We report a case of 60 year old female who presented with postmenopausal bleeding with endometrial polyp and was diagnosed later to be a case of leiomyosarcoma of uterus.

* Corresponding author.

E-mail address: drranjana@sampurnadiagnostics.com (R. Hawaldar).

2. Case Report

A 60 years old female of north Indian origin, reported to outpatient clinic, Khandwa on 5th October 2022 with the complaint of postmenopausal bleeding since 4 months and lower abdomen pain for 3 months. Bleeding was off and on and irregular in nature.

Abdominal pain was mild in intensity, non-radiating and having no variability with change in posture or respiration. There was also a history of weight loss and decreased appetite over 2 months. There were no associated bowel or bladder complaints. There was no history of long term illness or any chronic disease or any prior hospitalization.

2.1. On examination

Patient was moderately built. Vitals were stable with blood pressure was 138/90 mm Hg, pulse rate 74/min and respiratory rate 18/min, no pallor present.

On per abdominal examination, an irregular midline mass arising from the pelvis was present. The upper and lateral borders of the mass could be made out, lower margin could not be ascertained. The mass was firm to hard in

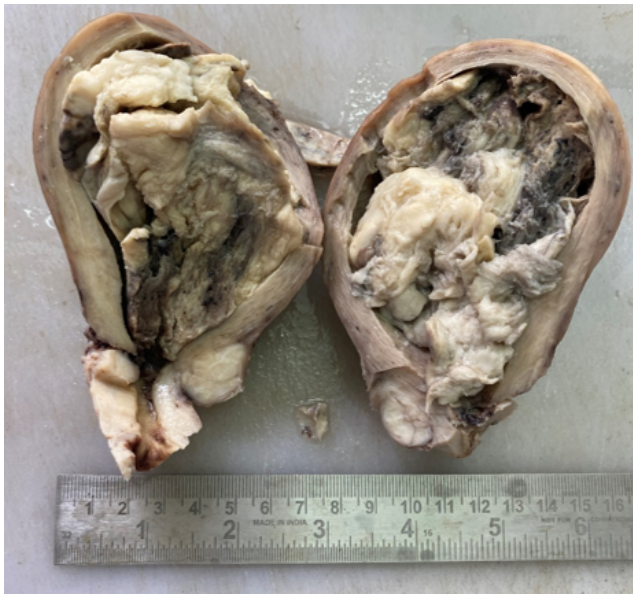

Fig. 1: Gross image: Polypoidal bulky fleshy tumor with areas of necrosis and hemorrhage.

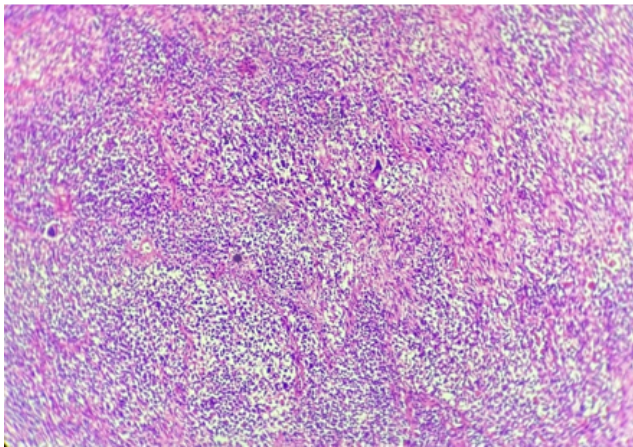


Fig. 2: Microscopic image at low power (10x): Hypercellular, neoplastic growth of elongated cells.

consistency with restricted mobility and non tender with no free fluid. There was no hepatosplenomegaly.

On vaginal examination, the cervix was directed backwards, uterus was anteverted, around 20 weeks size and mobile, B/L fornices were clear, no tenderness was observed.

2.2. Investigation

Ultrasonography findings were an ill defined heterogeneous echotexture mass lesion measuring 7.4x 4.7cm seen in the endometrial cavity with mildly increased vascularity. Both ovaries were not visualized- likely atrophic-postmenopausal. No adnexal mass was seen. Possibility of

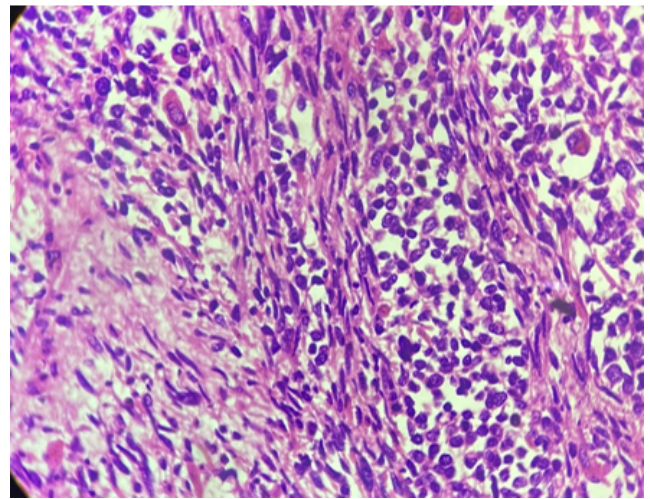


Fig. 3: Microscopic image at high power (40X): Cellular tumor comprised of spindled/ fascicular cells with moderate to severe pleomorphism and many mitotic figures.

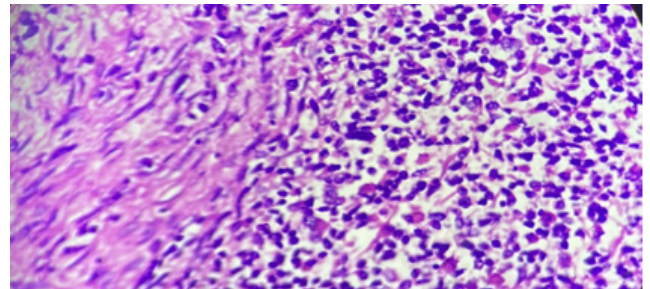


Fig. 4: Microscopic image at low power (10x): Tumor cells infiltrating muscle layers.

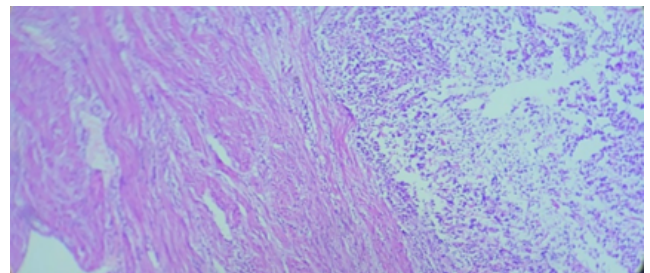


Fig. 5: Microscopic image at high power (40x): Tumor cells infiltrating muscle layers.

neoplastic etiology was a conclusion.

Patient underwent total abdominal hysterectomy on 11th October 2022 at a private nursing home and we received the biopsy for histopathological examination sample at our center.

2.3. Gross examination

Some leiomyosarcomas are grossly similar to ordinary leiomyomas but majority are soft or fleshy with areas of necrotic or hemorrhagic areas. In our case Uterus was uniformly enlarged weighing 300gm and measuring 10.0x 9.5x 7.0cm and surface was smooth apart from irregularity because of removal of adhesions. On cut section Endometrial cavity showed a polypoidal mass measuring 7.5x 5.0x 4.0cm. An intramural fibroid measuring 2.0cm in diameter was also identified. Cervical canal was 2.5cm in length. Grossly bilateral parametrial tissue was unremarkable.

2.4. Microscopic examination

Section from polypoidal mass showed tumor and myometrial tissue. Tumor was composed of round to spindle cells with high N:C ratio, eosinophilic cytoplasm, marked nuclear pleomorphism forming diffuse sheets with focal areas of necrosis. Tumor cells were infiltrating the muscle layer. Serosal layer was unremarkable. Bilateral parametrium was unremarkable. Cervix was free of tumor cells.

Features suggested two possibilities with differential diagnosis of Endometrial stromal sarcoma and leiomyosarcoma. So for further confirmation Immunohistochemistry was advised for definitive diagnosis.

2.5. The IHC profile of this case

Endometrial stromal nodules and sarcomas are diffusely positive for CD-10 and negative for desmin. Whereas cellular leiomyomas and leiomyosarcomas are usually positive for CD10 and positive for desmin, immunohistochemistry can be helpful in difficult cases.^{4,5}

Carcinosarcoma was also a differential diagnosis as they commonly present as a uterine polyp in post menopausal women. But in our case, there was absence features of endometrioid, serous or clear cell type adenocarcinoma.^{6,7} Ultrastructurally and immunohistochemically, the features of leiomyosarcoma are those of smooth muscle cells.⁴

Leiomyosarcoma show consistent immunoreactivity for smooth and common muscle actin, desmin, calponin, h-caldesmon and vimentin. Endometrial stromal sarcoma show sensitivity for CD-10, ER, PR and cyclin D1.⁸

In our case, Tumor cells were positive for vimentin, desmin, h caldesmon, p-53 and focally SMA. Also, Tumor cells were negative for PanCK, S100, CD34, ER, CD10, Cyclin D-1, CD117.

In contrast to leiomyoma, there is commonly TP53 mutation in leiomyosarcoma, which results in overexpression of p-53 as in our case.

Ki- 67: 50%

Conclusive diagnosis by IHC was Leiomyosarcoma.

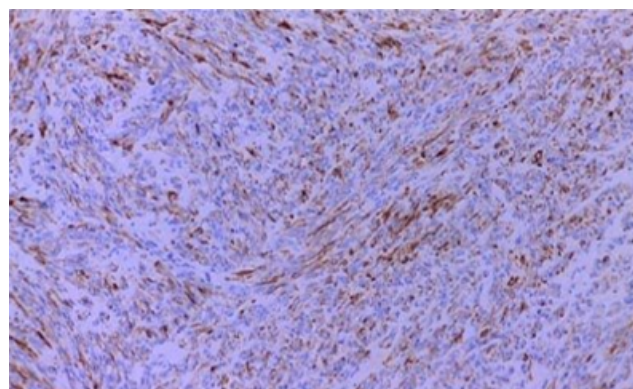


Fig. 6: IHC: h-Caldesmon positive

Table 1:

Immunohistochemistry	h-Caldesmon	CD-10	Desmin	Cyclin D1
Leiomyosarcoma	Positive	Negative	Positive	Negative
Endometrial stromal sarcoma	Negative	Diffusely positive	Negative	Positive

3. Discussion

Uterine sarcomas are rare and constitute about 2% to 5% of all malignancies with annual incidence of 0.64 per 1,00,000 women. Although leiomyosarcomas can occur elsewhere in the pelvis, including the cervix and urinary bladder, it is more commonly found in uterus. Signs and symptoms resemble those of the far more common leiomyoma and preoperative distinction between the two tumors may be difficult. Our patient presented with complaints of postmenopausal bleeding since four months.

At molecular level, there is no evidence of progression from leiomyoma to leiomyosarcoma and approximately 0.5% of women who have hysterectomies for uterine fibroids are found to have leiomyosarcomas.^{2,9}

SMA, MSA and vimentin were shown by many researchers to have little reliability in differentiating endometrial stromal neoplasms from uterine smooth muscle tumors. However there appeared to conflicting results regarding the discriminatory value of desmin for this differential diagnosis. Olive et al.¹⁰ demonstrated that highly cellular uterine leiomyomas were positive for desmin, whereas endometrial stromal nodules and ESSs were negative.

Uterine leiomyosarcomas are aggressive tumors with high rates of recurrence.^{11,12} The uterine sarcoma is made from histologic examination of entire uterus as seen in our case.

Leiomyosarcoma has a poor prognosis. Prognostic factors include tumor size >5 cm and high mitotic index. The most common mode of spread is hematogenous.

Surgical intervention is the treatment of choice with Total abdominal hysterectomy, bilateral salpingo – oophorectomy for postmenopausal females and those with metastatic disease and Total abdominal hysterectomy without bilateral salpingo – oophorectomy for premenopausal females.⁵ Hormonal therapy may be an option in hormone receptor positive tumors.

4. Conclusion

It is important to differentiate endometrial stromal sarcoma from uterine leiomyosarcoma, which is vital due to their clinical course and management. IHC panels along with gross and microscopic examination play a major role in reaching a definitive diagnosis.

5. Conflict of Interest

None.

6. Source of Funding

None.


References

1. Park JY, Park SK, Kim DY, Kim JH, Kim YM, Kim YT, et al. The impact of tumor morcellation during surgery on the prognosis of patients with apparently early uterine leiomyosarcoma. *Gynecol Oncol.* 2011;122(2):255–9. doi:10.1016/j.ygyno.2011.04.021.
2. Liu FW. A critical assessment of morcellation and its impact on gynecologic surgery and the limitations of the existing literature. *Am J Obstet Gynecol.* 2015;212(6):717–24. doi:10.1016/j.ajog.2015.01.012.
3. Garg G, Shah JP, Kumar S, Bryant CS, Munkarah A, Morris RT, et al. Ovarian and uterine carcinosarcomas: a comparative analysis of prognostic variables and survival outcomes. *Int J Gynecol Cancer.* 2010;20(5):888–94. doi:10.1111/IGC.0b013e3181dc8292.
4. Althobaiti FA. A case of hemoperitoneum due to spontaneous bleeding from a uterine leiomyoma. *Am J Case Rep.* 2019;20:167–70. doi:10.12659/AJCR.914573.
5. Patel SM, Tiwari R, Arora RS, Poddar P, Desai A, Mankad MH, et al. Uterine Sarcomas: Surgical Management, Adjuvant Therapy and Survival Outcome. Experience at Gujarat Cancer and Research Institute. *Indian J Gynecol Oncol.* 2019;17(1). doi:10.1007/s40944-018-0247-0.
6. Jin Z, Ogata S, Tamura G, Katayama Y, Fukase M, Yajima M, et al. Carcinosarcomas (malignant mullerian mixed tumors) of the uterus and ovary: a genetic study with special reference to histogenesis. *Int J Gynecol Pathol.* 2003;22(4):368–73.
7. Villena-Heinsen C, Diesing D, Fischer D, Griesinger G, Maas N, Diedrich K, et al. Carcinosarcomas - a retrospective analysis of 21 patients. *Anticancer Res.* 2006;26(6C):4817–23.
8. Watanabe K, Tajino T, Sekiguchi M, Suzuki T. h-Caldesmon as a specific marker for smooth muscle tumors. Comparison with other smooth muscle markers in bone tumors. *Am J Clin Pathol.* 2000;113(5):663–8. doi:10.1309/jnqx-f4km-q0q0-7xk8.
9. Liu F, Bin L. Dissemination problems of laparoscopic uterine fibroids morcellation and its prevention. *Cancer Res Prev Treat.* 2017;44(9):627–30.
10. Olive E, Young RH, Clement PB, Scully RE. Myxoid and fibrous endometrial stromal tumors of uterus: a report of 10 cases. *Int J Gynecol Pathol.* 1999;18(4):310–9. doi:10.1097/00004347-199910000-00004.
11. Khushpreet K, Parneet K, Arvinder, Atish S. Uterine leiomyosarcoma A case report. *J Mid-life Health.* 2014;5(4):202–4. doi:10.4103/0976-7800.145175.
12. Sujatha V, Rao M, Sunkavalli CB. A rare case of uterine leiomyosarcoma: A case report. *J Med Case Rep.* 2010;4:222. doi:10.1186/1752-1947-4-222.

Author biography

Shana Nikhat Khan, Consultant Pathologist

Ekta Patidar, Consultant Pathologist

Ranjana Hawaldar, Consultant Pathologist  <https://orcid.org/0000-0003-4059-0781>

Cite this article: Khan SN, Patidar E, Hawaldar R. Immunohistochemical markers in differential diagnosis of endometrial stromal sarcoma and leiomyosarcoma in an endometrial polyp: A case report. *IP Arch Cytol Histopathology Res* 2023;8(1):56-59.