

Content available at: <https://www.ipinnovative.com/open-access-journals>

IP Archives of Cytology and Histopathology Research

Journal homepage: <https://www.achr.co.in/>

## Case Report

# Hyalinizing trabecular tumor of thyroid (HTT) – A rare case report

Anusha S<sup>1\*</sup>, Seema Bijjaragi<sup>1</sup>, HR Chandrashekar<sup>1</sup>, Veerendra Kumar HM<sup>1</sup>

<sup>1</sup>Dept. of Pathology, J.J.M Medical College, Davangere, Karnataka, India



### ARTICLE INFO

#### Article history:

Received 05-11-2023

Accepted 29-11-2023

Available online 08-01-2024

#### Keywords:

Benign

Fine needle aspiration cytology

Hyalinizing trabecular tumor

Rare

Thyroid tumor

### ABSTRACT

Hyalinizing Trabecular Tumour of the Thyroid (HTT) is a rare type of tumor that affects the thyroid gland. It was first discovered by Carney in 1987. This tumor is of follicular origin and has unique nuclear, architectural, and immunohistochemical features that differentiate it from other well-known thyroid abnormalities, such as Papillary Thyroid Carcinoma (PTC) and Medullary Thyroid Carcinoma (MTC). Although initially thought to be a subtype of PTC, several later reports showed that HTT is an independent entity. The incident rate of HTT ranges between 0.44% and 1.3%. This case report presents a 46-year-old male patient who complained of swelling in the front of his neck, more towards the left side, which had been observed for the past three months. FNAC (fine needle aspiration cytology) reported it as a follicular lesion of undetermined significance - Bethesda category III. Hemithyroidectomy was performed on the patient, and HTT was diagnosed through histopathological examination. As it is a benign neoplasm, PTC or other tumors had to be ruled out, and management varied accordingly. Based on its biological and clinical behavior, HTT should be considered as a benign neoplasm or as a neoplasm of extremely low malignant potential. This case report is presented for its unusual occurrence and unique behavior

This is an Open Access (OA) journal, and articles are distributed under the terms of the [Creative Commons Attribution-NonCommercial-ShareAlike 4.0 License](https://creativecommons.org/licenses/by-nc-sa/4.0/), which allows others to remix, tweak, and build upon the work non-commercially, as long as appropriate credit is given and the new creations are licensed under the identical terms.

For reprints contact: [reprint@ipinnovative.com](mailto:reprint@ipinnovative.com)

## 1. Introduction

HTT is a rare benign thyroid neoplasm that is often falsely diagnosed as either Papillary Thyroid Carcinoma (PTC) or Medullary Thyroid Carcinoma (MTC). According to the report, HTT was discovered in around 0.44% -1.3% of all thyroidectomies.<sup>1</sup>

Carney et al in 1987 was the first person to coin the term Hyalinizing Trabecular Adenoma (HTA) which manifests in trabecular growth pattern with hyalinizing stroma.<sup>2</sup> Later debates regarding the categorization of the tumour emerged, many consider it to be a distinct and separate entity, but others argue it is a variant of PTC. To further complicate matters, certain cases were found to be benign, while others showed the presence of metastasis to lymph nodes or lungs. As a result, it was given a new name, Hyalinizing Trabecular

Carcinoma (HTC).<sup>3</sup>

As a result of its uncertain malignant potential, the World Health Organization (WHO) gave a more generalized and broader term called Hyalinizing Trabecular Tumour (HTT) which was later accepted by all pathologists.<sup>4</sup> The difficulty of diagnosing HTT in FNA samples has been noted in the earliest report by Zipkin in 1905<sup>5</sup> and further elaborated in Carney's comprehensive description in 1987<sup>2</sup> due to its overlapping cytologic features of HTT with PTC and MTC. Surgeons must identify the characteristics of this abnormality for the effective treatment and management of HTT. Currently, lobectomy is the recommended as course of action for HTTs. However, in some cases, due to misdiagnosis total thyroidectomy will be done. We are sharing this case report due to its unusual occurrence and to provide some basic information about HTT.

\* Corresponding author.

E-mail address: [anushasmnth@gmail.com](mailto:anushasmnth@gmail.com) (Anusha S).

## 2. Case Report

### 2.1. Clinical history

A 46-year-old male patient presented with solitary swelling in front of the neck more towards the left side for 3 months. Clinically patient had no compressive symptoms nor hypothyroid or hyperthyroid symptoms. On examination palpable firm non-tender left thyroid nodule was noted but no palpable cervical lymph nodes. Ultrasonographic findings were nonspecific. Fine needle aspiration cytology (FNAC) was reported as a follicular lesion of undetermined significance in Bethesda category III. Later patient underwent a Hemithyroidectomy without any post-surgical complications.



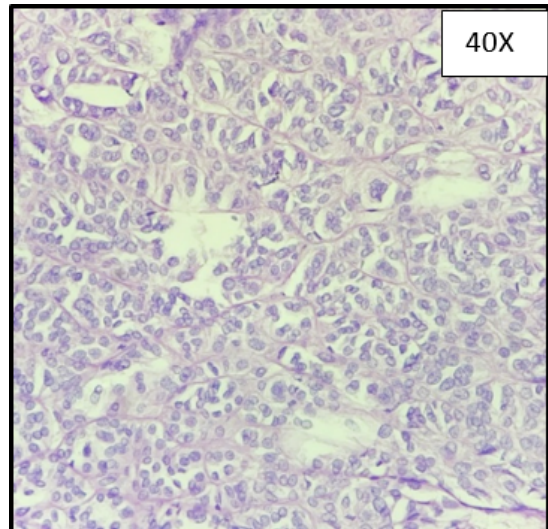
**Figure 1:** A well encapsulated hemithyroidectomy specimen



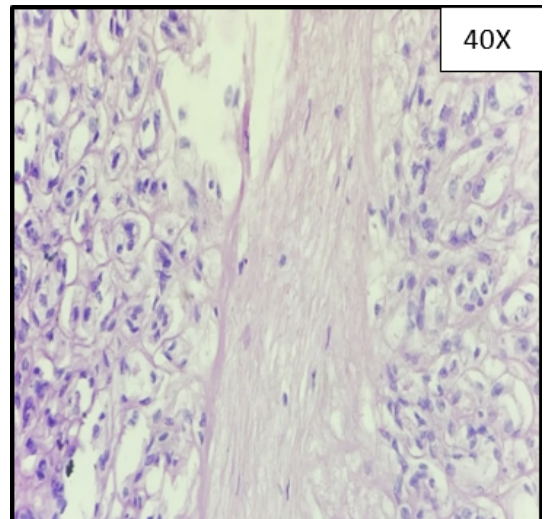
**Figure 2:** Homogenous grey white solid tumour with areas of haemorrhage

#### 2.1.1. Gross examination

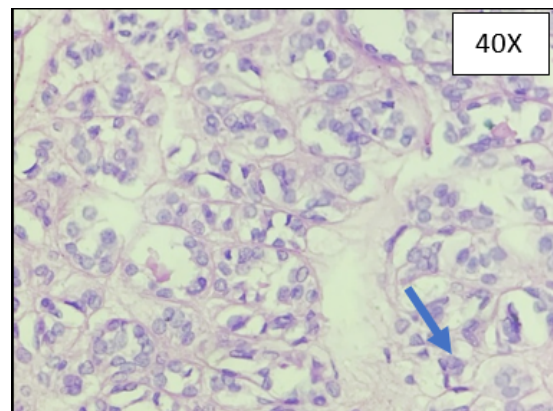
Received a Hemithyroidectomy specimen measuring 6x4x3.5cm (Figure 1). The Cut surface showed a



**Figure 3:** Trabecular pattern of arrangement of tumor cells

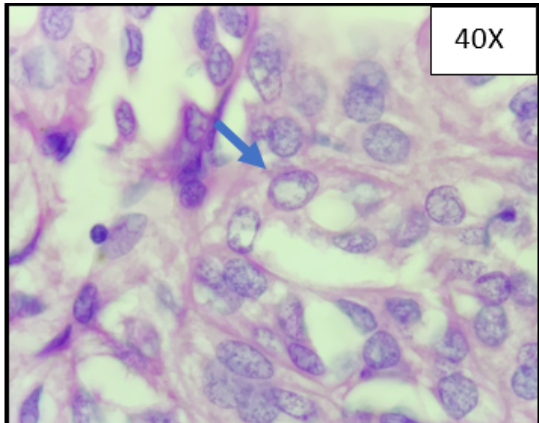


**Figure 4:** Hyalinized Stroma

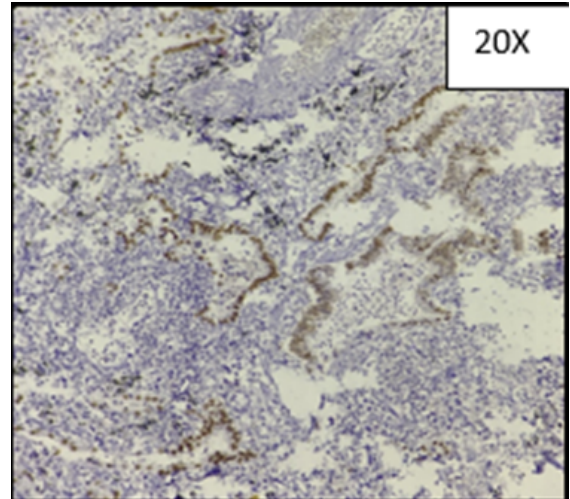


**Figure 5:** Oval to elongated nuclei with nuclear grooves

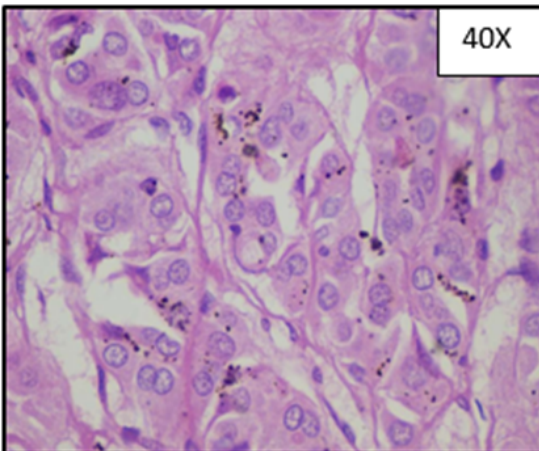




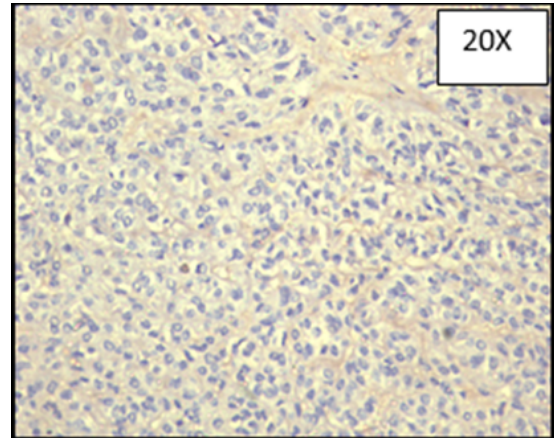
**Figure 6:** Intranuclear inclusion



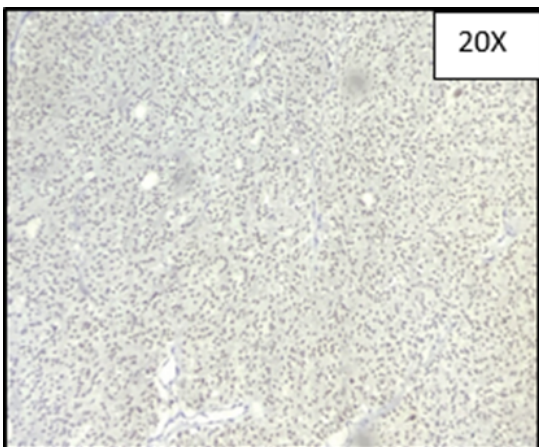
**Figure 9:** TTF1 Nuclear positivity



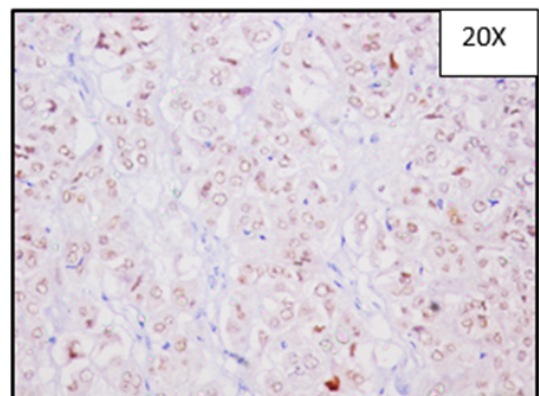
**Figure 7:** Intracytoplasmic yellow



**Figure 10:** MIB-1 (Ki-67) membranous staining



**Figure 8:** PAX8 Nuclear positivity



**Figure 11:** Thyroglobulin

homogenous grey-white solid tumor occupying entire lobes of the thyroid with areas of hemorrhage seen (Figure 2).

### 2.1.2. Microscopic examination

Multiple sections studied are showing a well-capsulated tumor bordered by a normal thyroid. Tumour cells are arranged in trabecular or a nested pattern (Figure 3), separated by vascular septa. Cells are large to medium-sized and have abundant pale eosinophilic cytoplasm. Nuclei are oval to elongated and have nuclear grooves (Figure 5) and few intranuclear inclusions (Figure 6). The cell cytoplasm has perinuclear inclusion bodies—no Capsular or vascular invasion. A small area has a microfollicular pattern. Hyaline is seen in the intertrabecular area (Figure 4).

Immunohistochemical study of these tumors showed positivity for thyroglobulin (Figure 11), Thyroid Transcription Factor-1 (TTF-1) [Figure 9], and diffuse, intense membrane staining with MIB-1 (Ki-67) monoclonal antibody (Figure 10) and PAX8 (Figure 8). These findings supported the diagnosis of HTT.

## 3. Discussion

WHO defines HTT as “a rare tumor of follicular origin with a trabecular pattern of growth and marked intra-trabecular hyalinization”.<sup>4</sup> In the recent 5th edition of the WHO classification of tumors of endocrine organs, HTT has been grouped with low-risk neoplasms. There is a lot of disagreement and debate about this thyroid lesion. It is commonly seen in 4<sup>th</sup> and 5<sup>th</sup> decade of age, especially in females<sup>6</sup>. This lesion is commonly misdiagnosed because of its overlapping cytological features with PTC and MTC. However, it is foremost important to take into account the distinguishing characteristics of HTT when diagnosing thyroid nodules. Identifying HTT on FNA is crucial in determining the appropriate treatment for a thyroid nodule. If the nodule is determined to be malignant, a total thyroidectomy is necessary. On the other hand, suspicious nodules or follicular neoplasms require a hemithyroidectomy to obtain samples for further investigation of capsular invasion.

The distinguishing characteristics of HTT, which come from follicular cells, consist of the presence of hyalinization and calcification of extracellular material, and the trabecular pattern of arrangement of tumor cells. These cells have a low nuclear-to-cytoplasmic ratio with nuclear grooves and pseudo inclusions are frequently seen. In the past, HTT was believed to be a type of PTC due to similar characteristics in terms of appearance and genetic factors like cytokeratin expression and RET/PTC translocation.<sup>7</sup> However, it differed from PTC because it did not have BRAF and RAS mutations.<sup>7</sup> Furthermore, Ki67 diffuse intense membrane staining is unique to HTT where MIB1 monoclonal antibody at room temp is used in comparison

with PTC where Ki67 is nuclear staining of dividing cells.<sup>8</sup> However, there is still ongoing debate about this.<sup>9,10</sup> Takada N et al. discovered Ki-67 (MIB-1) as a specific marker for HTT.<sup>9</sup>

Using a similar approach, P Caraci<sup>11</sup> et al also published a case report of a 69-year-old female with multinodular goiter, USG guided FNAC showed nuclear characteristics suggestive of papillary thyroid carcinoma (PTC), but they were not definitive enough to diagnose it as such due to the absence of colloid in the background. Therefore, the diagnosis of indeterminate follicular neoplasm, Category III was made but on histopathology, HTT was determined due to its unique morphological characteristics and confirmation through IHC testing.

In a study conducted by Casey et al<sup>10</sup> in a series of 29 cases, they described the specific cytological features to differentiate HTT from PTC and MTC. The main distinguishing feature is the arrangement of tumor cells with abundant cytoplasm forming cohesive clusters that radially surround hyaline material. Additionally, there is a distinct diffuse membrane immunoreactivity observed when using the MIB-1 antibody.

However, diagnosing HTT solely through FNA is difficult because it can resemble other types of thyroid cancer besides PTC.

Overall, the prognosis of HTT is favorable, although, in rare instances, there may be the presence of malignant characteristics or metastases.

## 4. Conclusion

Hyalinizing trabecular tumour is a rare and controversial thyroid tumour, characterized by a trabecular pattern of arrangement with hyalinizing stroma. Differentiation of HTT from other thyroid tumours such as Papillary Thyroid Carcinoma and Medullary Thyroid Carcinoma can be achieved using immunohistochemistry in addition to morphology. In general, the prognosis of HTT is favourable and should be considered as a benign neoplasm or as a neoplasm of extremely low malignant potential.

## 5. Source of Funding

None.

## 6. Conflict of Interest


None.

## References


1. Jones DJ, Kieliszak CR, Patel SS, Selinsky CR. Hyalinizing trabecular tumor of the thyroid gland and its significant diagnostic issue. *Thyroid Res.* 2017;10:7. doi:10.1186/s13044-017-0042-5.
2. Carney JA, Ryan J, Goellner JR. Hyalinizing trabecular adenoma of the thyroid gland. *Am J Surg Pathol.* 1987;11(8):583–91.
3. Gowrishankar S, Pai SA, Carney JA. Hyalinizing trabecular carcinoma of the thyroid gland. *Histopathology.* 2008;52(4):529–31.

4. Lloyd RV. Who classification of tumors of Endocrine Organs. 5th edn. Lyon: International Agency for Research on Cancer (IARC); 2022.
5. Zipkin R. Hyalinähnliche kollagene Kugeln als Produkte epithelialer Zellen in malignen Strumen. *Virchows Arch Pathol Anat Physiol Klin Med.* 1905;182:374–406.
6. Li J, Yang GZ, Gao LX, Yan WX, Jin H, Li L, et al. Hyalinizing trabecular tumour of the thyroid: Case report and review of the literature. *Exp Ther Med.* 2012;3(6):1015–7.
7. Salvatore G, Chiappetta G, Nikiforov YE. Molecular profile of hyalinizing trabecular tumours of the thyroid: high prevalence of RET/PTC rearrangements and absence of B-raf and N-ras point mutations. *Eur J Cancer.* 2005;41(5):816–21.
8. Leonardo E, Volante M, Barbareschi M, Cavazza A, Tos APD, Bussolati G, et al. Cell membrane reactivity of MIB-1 antibody to Ki67 in human tumors: fact or artifact? *Appl Immunohistochem Mol Morphol.* 2007;15(2):220–3.
9. Takada N, Hirokawa M, Ohbayashi C, Nishikawa T, Itoh T, Imagawa N, et al. Re-evaluation of MIB-1 immunostaining for diagnosing hyalinizing trabecular tumour of the thyroid: semi-automated techniques with manual antigen retrieval are more accurate than fully automated techniques. *Endocr J.* 2018;65(2):239–44.
10. Casey MB, Sebo TJ, Carney JA. Hyalinizing trabecular adenoma of the thyroid gland identification through MIB-1 staining of fine needle aspiration biopsy smears. *Am J Clin Pathol.* 2004;122(4):506–10.
11. Caraci P, Fulcheri A, Ondolo C, Laino F, Volante M, Aversa S, et al. Hyalinizing trabecular tumor of the thyroid: A case report. *Head Neck Pathol.* 2011;5(4):423–7.

### Author biography

**Anusha S**, Post Graduate  <https://orcid.org/0009-0002-9518-9987>

**Seema Bijjaragi**, Professor  <https://orcid.org/0000-0002-9911-1039>

**HR Chandrashekar**, Senior Professor  <https://orcid.org/0000-0001-9942-146X>

**Veerendra Kumar HM**, Associate Professor

**Cite this article:** Anusha S, Bijjaragi S, Chandrashekar HR, Veerendra Kumar HM. Hyalinizing trabecular tumor of thyroid (HTT) – A rare case report. *IP Arch Cytol Histopathology Res* 2023;8(4):253-257.