



Case Report

Huge renal oncocytoma with solid and cystic areas - A case report and review of literature

Jigna Jerambhai Kalariya^{1*}

¹Dept. of Pathology, B T Savani Kidney Hospital, Rajkot, Gujarat, India



ARTICLE INFO

Article history:

Received 30-11-2023

Accepted 06-12-2023

Available online 08-01-2024

Keywords:

Renal oncocytoma

Cystic areas

ABSTRACT

This abstract presents a rare case of a huge renal oncocytoma, emphasizing its diagnostic challenges, clinical management, and unique characteristics. Oncocytomas are relatively uncommon benign neoplasms, typically found in various organs, including the kidneys, salivary glands, and thyroid. However, the occurrence of an exceptionally large renal oncocytoma poses distinct clinical considerations. We report the case of a patient who presented with a large palpable mass occupying almost whole abdomen with firm to hard in consistency. The diagnostic process involved an imaging studies, including computed tomography (CT) along with histopathological examination of specimen. The diagnostic challenges stemmed from the atypical size and radiological features. Surgical intervention was necessary due to the size of the renal oncocytoma. This case highlights the importance of considering renal oncocytomas in the differential diagnosis of large renal masses, even when their size exceeds typical dimensions. The management of huge oncocytomas involves a multidisciplinary approach, incorporating advanced imaging techniques, pathological assessment, and surgical expertise. Histology of renal oncocytoma in our case is also different as it is showing cystic areas. Immunohistochemistry confirmed the diagnosis of renal oncocytoma. Awareness of these rare cases is crucial for clinicians to guide appropriate diagnostic and therapeutic strategies, ensuring optimal patient outcomes.

This is an Open Access (OA) journal, and articles are distributed under the terms of the [Creative Commons Attribution-NonCommercial-ShareAlike 4.0 License](https://creativecommons.org/licenses/by-nc-sa/4.0/), which allows others to remix, tweak, and build upon the work non-commercially, as long as appropriate credit is given and the new creations are licensed under the identical terms.

For reprints contact: reprint@ipinnovative.com

1. Introduction

Renal oncocytomas, characterized by the proliferation of oncocytes within the renal parenchyma, are typically benign tumors. Renal Oncocytomas are relatively uncommon and are usually of small size (average size 4.9 ± 2.7 cm). Cases of exceptionally large renal oncocytomas are very rare which presents a unique set of challenges in diagnosis and clinical management. Understanding and addressing these cases is of paramount importance due to the potential impact on patient outcomes and the intricate balance between diagnostic accuracy and therapeutic intervention.¹⁻⁵

2. Case Presentation

A 37-year-old male patient presented with anorexia, weight loss (5kg in 1 month), generalized weakness, abdominal lump. On examination Large palpable mass occupying almost whole abdomen with firm to hard in consistency. On laboratory investigations Hemoglobin – 6.8gm%, TC – 5420 /cu.mm, Serum Creatinine – 1.02mg/dl, Serum Calcium – 1.07mmol/L. On USG abdomen there was a large irregular heterogeneous mixed solid cystic lesion noted along upper pole of left kidney which measures 199 x 142mm. On CT abdomen a large smoothly marinated, heterogeneously enhancing soft tissue density lesion is seen at upper pole of left kidney. Scattered foci of calcifications are seen within the lesion. It measures 253mm x 202mm x 185mm. After anemia correction patient underwent left

* Corresponding author.

E-mail address: drjignapath83@gmail.com (J. J. Kalariya).

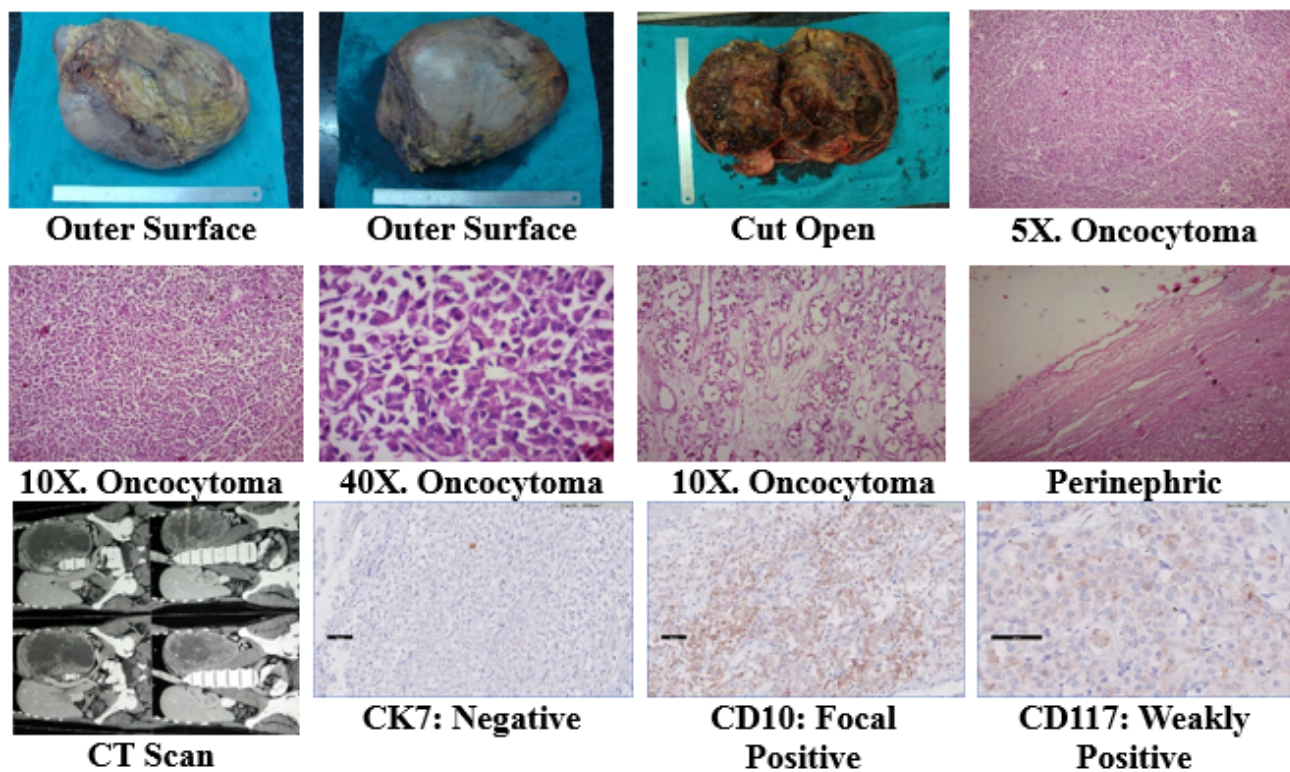


Figure 1:

open radical nephrectomy. On gross examination Weight: 5380 gm. 29.0 x 21.0 x 13.5 cm sized left kidney with perinephric fat received. On cut open there is a presence of huge mass measuring 27.0 x 19.0 x 11.5 cm sized with only 6.0 cm sized normal kidney identified at the periphery of mass. Mass is single, solid and cystic, yellowish and brownish black in color with areas of hemorrhage and necrosis. On microscopy, Sections from mass show cells with abundant acidophilic granular cytoplasm growing in nesting and alveolar pattern and at places in tubular fashion. The nuclei are small, round and regular. Focal loose fibrous and hyalinized stroma present. There are presence of areas with hemorrhage, severe necrosis and infiltration by inflammatory cells neutrophils, lymphocytes and plasma cells. Sections from perinephric fat, ureter and renal vessels are free from tumor cells. On immunohistochemistry, CK 7: negative, CD 10: focal positive, CD 117: weakly positive. So Renal Oncocytoma was diagnosed.

3. Discussion

According to English literature largest and heaviest Renal Oncocytoma reported is 4652 gm and the case we report is having weight of 5380 gm, is a largest Renal oncocytomas till now reported as per our knowledge. Renal oncocytomas make up approximately 7% of all primary non urothelial epithelial renal neoplasm. Typical gross features of renal

oncocytoma is a tan or mahogany brown colored cut surface generally similar to normal renal parenchyma, stellate scar may be present. Microscopically, oncocytoma shows cells having abundant acidophilic granular cytoplasm, growing in nesting and tubular fashion. The nuclei are usually small, round and regular. From nuclear feature also we can differentiate oncocytoma from chromophobe renal cell carcinoma as chromophobe renal cell carcinoma has resinoid nucleus, having irregular nuclear border and perinuclear clearing. In a huge renal oncocytoma gross as well as microscopic finding differs. It may have solid and cystic areas and necrosis due to lack of blood supply in the centre of tumor.⁶⁻¹⁰

4. Conclusion

Huge renal oncocytoma more than 5kg is very rare. Very few huge renal oncocytomas are reported in literature. Renal oncocytoma can present as solid and cystic morphology with areas of necrosis. Histology findings and immunohistochemistry confirms the diagnosis in unusual type of gross appearance. Instead of Huge size of tumor, perinephric fat may be free from tumor cells which suggest better prognosis for patient.

5. Source of Funding

None.

6. Conflict of Interest

None.

References

1. Akbulut S, Senol A, Cakabay B, Sezgin A. Giant renal oncocytoma: a case report and review of the literature. *J Med Case Rep.* 2010;4:52. doi:10.1186/1752-1947-4-52.
2. Amin MB, Crotty TB, Tickoo SK, Farrow GM. Renal oncocytoma: a reappraisal of morphologic features with clinicopathologic findings in 80 cases. *Am J Surg Pathol.* 1997;21(1):1–12.
3. Demos TC, Malone AJ. Computed tomography of a giant renal oncocytoma. *J Comp Assist Tomogr.* 1988;12(5):899–900.
4. Perez-Ordóñez B, Hamed G, Campbell S, Erlandson RA, Russo P, Gaudin PB, et al. Renal oncocytoma: a clinicopathologic study of 70 cases. *Am J Surg Pathol.* 1997;21(8):871–83.
5. Sundararajan S, Dyer J, Pemberton R, Cohen RJ. Asymptomatic giant renal oncocytoma presenting with hypertension. *Patholog.* 2008;40(7):723–4.
6. Kiliç S, Altınok MT, Ipek D, Ergin H. Case report of a giant renal oncocytoma. *Int Urol Nephrol.* 2003;35(1):83–4.
7. Lieber MM. Renal oncocytoma: prognosis and treatment. *Eur Urol.* 1990;18(2):17–21.
8. Shin LK, Badler RL, Bruno FM, Gupta M, Katz DS. Radiology-pathology conference: bilateral renal oncocytomas. *Clin Imaging.* 2004;28(5):344–8.
9. Sundararajan S, Dyer J, Pemberton R, Cohen RJ. Asymptomatic giant renal oncocytoma presenting with hypertension. *Pathology.* 2008;40(7):723–4.
10. Dechet CB, Bostwick DG, Blute ML, Bryant SC, Zincke H. Renal oncocytoma: multifocality, bilateralism, metachronous tumor development, and coexistent renal cell carcinoma. *J Urol.* 1999;162(1):40–2.

Author biography

Jigna Jerambhai Kalariya, Consultant Pathologist

Cite this article: Kalariya JJ. Huge renal oncocytoma with solid and cystic areas - A case report and review of literature. *IP Arch Cytol Histopathology Res* 2023;8(4):258-260.