

Content available at: <https://www.ipinnovative.com/open-access-journals>

IP Archives of Cytology and Histopathology Research

Journal homepage: <https://www.achr.co.in/>

Case Report

A rare case report of metastasizing pleomorphic adenoma of parotid gland

Lakshmi Agarwal^{1*}, Vishakha Sharma¹, Lokesh Rawat²

¹Dept. of Pathology, Govt Medical college, Kota, Rajasthan, India

²Dept. of Radiology, Balaji Sonography & Diagnostic Center, Kota, Rajasthan, India



ARTICLE INFO

Article history:

Received 21-11-2023

Accepted 08-12-2023

Available online 08-01-2024

Keywords:

Metastasizing pleomorphic adenoma

Parotid gland

Rare

Benign

ABSTRACT

Pleomorphic adenoma is one of the most common benign parotid gland tumors. Local recurrence can occur in 1% to 5% of cases after surgery. Metastasizing pleomorphic adenomas are very rare entity and have rarely been reported. Histologically it has benign morphology. Metastasis can occur in bone, lymph nodes, the lung, oral cavity, pharynx, skin, liver, kidney, and central nervous system. We hereby report a case of pleomorphic adenoma of the parotid gland metastasizing to lungs.

This is an Open Access (OA) journal, and articles are distributed under the terms of the [Creative Commons Attribution-NonCommercial-ShareAlike 4.0 License](https://creativecommons.org/licenses/by-nc-sa/4.0/), which allows others to remix, tweak, and build upon the work non-commercially, as long as appropriate credit is given and the new creations are licensed under the identical terms.

For reprints contact: reprint@ipinnovative.com

1. Introduction

Metastasizing pleomorphic adenoma (MPA) constitutes an extremely rare group of tumors and is also known as metastasizing benign pleomorphic adenoma, metastasizing benign mixed tumor, and metastasizing mixed tumor.^{1,2} WHO defines MPA as a “histologically benign pleomorphic adenoma that inexplicably manifests local or distant metastasis”.^{3,4} There are three main patterns of malignant change that occur in pleomorphic adenoma: MPA, Carcinoma ex pleomorphic adenoma, and true malignant mixed tumor (carcinosarcoma). The mortality rate is 22%.^{3,5} It occurs after a long-time interval between the initial surgery and metastasis. The most common primary site is the parotid gland (74%), followed by minor salivary glands (17%) and submandibular glands (10%). Most common site for metastasis is Bones (50%), Lung (30%) node and rarely to liver, CNS, skin.^{2,6}

2. Case Report

A 50-year-old woman presented with a large neck mass as shown in (Figure 1) msg 15x13x10 cm. The swelling was increasing in size from last 1 years. She had a history of surgery at the same site 5 years back which was diagnosed as pleomorphic adenoma. Systemic examination and routine blood investigation were within normal limits.

CECT neck and chest was done (Figure 2): - shows 15.5X13.7X10.1 cm sized lobulated heterogeneously enhancing mass lesion seen involving superficial & deep parotid gland involving medially and inferior triangle of neck. Multiple variable sized nodular lesions involving bilateral lungs S/O Lung Metastasis was also present.

FNAC from lung and neck mass (Figure 3a,b)– Smears from both the sites revealed fibrillary chondromyxoid stroma and singly scattered, clusters of myoepithelial cells. The cells are ovoid to plasmacytoid in shape with well-defined abundant cytoplasm. Features suggestive of Pleomorphic adenoma was given.

Trucut biopsy from neck mass (Figure 4a,b)—Sections reveal chondromyxoid stroma, myoepithelial cells and squamous metaplasia. Necrosis, mitosis and pleomorphism were not evident.

* Corresponding author.

E-mail address: dr_laxmiagarwal@gmail.com (L. Agarwal).

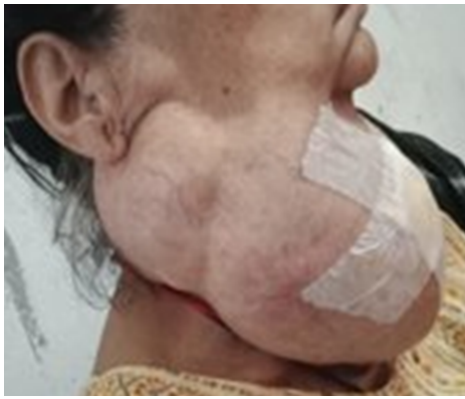

Figure 1: Showing large neck mass

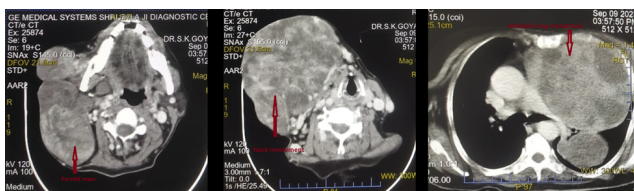


Figure 2: T scan image showing mass involving parotid and adjacent areas

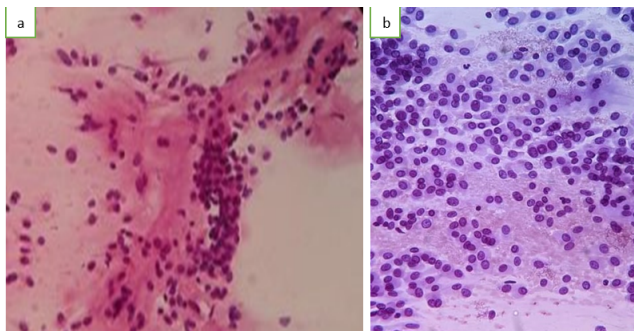


Figure 3: a: PAP stained smear showing chondromyxoid stroma and plasmacytoid cells; b: MGG stained smear showing plasmacytoid cells.

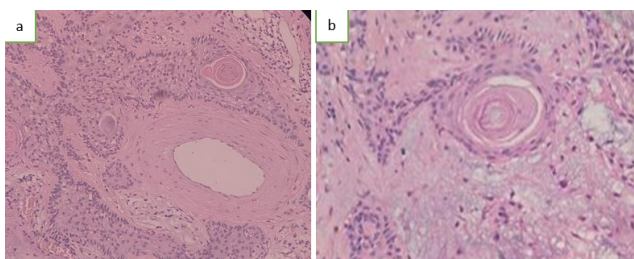


Figure 4: a: H&E stained smear showing chondromyxoid stroma, myoepithelial cells and squamous metaplasia; b: H&E stained smear showing Squamous metaplasia, chondromyxoid stroma and myoepithelial cells.

On the basis of imaging, cytology and histopathology findings, final diagnosis rendered was Metastasizing pleomorphic adenoma due to benign morphology and lung metastasis.

3. Discussion

Pleomorphic adenoma (PA) is the most common tumor that affects the parotid glands. Rarely PA undergoes malignant transformation into Carcinoma Ex-Pleomorphic Adenoma or carcinosarcoma.^{2,7} It's very rarely that PA metastasizes with benign morphology. The incidence of this is still unknown due to paucity of cases. The ratio of epithelial-myoeplithelial components to stromal components may vary in primary and metastatic deposits. There have been no reports of morphologic features in the original pleomorphic adenoma that can help predict the tumor's ability or inability to metastasize. Local recurrence of PA is most commonly related to incomplete resection of the disease during the first surgery or by vascular implantation.^{3,5} This theory was supported by Nourai et al.⁸ who studied 42 patients with MPA. Therefor complete surgery (Parotidectomy) instead of enucleation is the treatment of choice. Though the tumor has benign morphology, the behavior is aggressive. It has the potential to distant metastasis. The WHO reported that 40% of the patients die of the disease, 47% live free of the disease, and 13% live with the disease. The 5-year disease-specific and disease-free survival were 58% and 50%, respectively. There is no relation between tumor behavior and outcome with regard to the primary site of the tumor.^{9,10}

Histological diagnosis cannot differentiate MPA from a benign PA.^{3,6} Medical history of previous or concurrent primary PA is essential to diagnose MPA. IHC can help in primary diagnosis but not in differentiating from MPA. Therefore, correlation between clinical history, imaging finding and histopathology report are the gold standard for diagnosing MPA. Awareness of this entity is important for pathologist and clinician for diagnosing and proper management of the patient. Since only a few cases has been reported in the literature, more studies are required to understand the biology of this tumor.

4. Conclusion

MPA is a rare tumor of parotid gland. The etiology of this lesion is not clearly understood. The morphology of the cells is benign but can undergo metastasis. Therefore, metastatic workup should be done in such cases. Surgeon should be aware of this entity and complete surgery of the primary site should be mainstay of the treatment.

5. Source of Funding

None.


6. Conflict of Interest

None.

References

1. Fonseca D, Arya SS, Kodandapani S, Chandini A, Kurapati S, Rao C, et al. Metastasising Pleomorphic Adenoma: A Rare Entity. *Indian J Otolaryngol Head Neck Surg.* 2022;74(3):6321–3.
2. Nouraei SA, Ferguson MS, Clarke PM, Sandison A, Sandhu GS, Michaels L, et al. Metastasizing pleomorphic salivary adenoma. *Arch Otolaryngol Head Neck Surg.* 2006;132(7):788–93.
3. Santaliz-Ruiz LE, Morales G, Santini H, Sánchez-Santiago M, Arroyo A. Metastasizing Pleomorphic Adenoma: A Fascinating Enigma. *Case Rep Med.* 2012;10:148103. doi:10.1155/2012/148103.
4. Tumours of the salivary glands. In: Barnes L, Eveson J, Reichart P, Sidransky D, editors. World Health Organization Classification of Tumours: Pathology and Genetics of Head and Neck Tumours. Lyon, France: IARC Press; 2005.
5. Marioni G, Marino F, Stramare R, Marchese-Ragona R, Staffieri A. Benign metastasizing pleomorphic adenoma of the parotid gland: a clinicopathologic puzzle. *Head Neck.* 2003;25(12):1071–6.
6. Nakai A, Suzuki K, Furuse H, Tsuda T, Masaki Y, Shinno H, et al. Multiple metastasizing pleomorphic adenomas of the lung. *Intern Med.* 2017;56(6):691–4.
7. Reiland MD, Koutlas IG, Gopalakrishnan R, Pearson AG, Basi DL. Metastasizing pleomorphic adenoma presents intraorally: a case report and review of the literature. *J Oral Maxillofac Surg.* 2012;70(10):531–40.
8. Nouraei SAR, Ferguson MS, Clarke PM, Sandison A, Sandhu GS, Michaels L, et al. Metastasizing pleomorphic salivary adenoma. *Arch Otolaryngol Head Neck Surg.* 2006;132(7):788–93.
9. Manucha V, Ioffe OB. Metastasizing pleomorphic adenoma of the salivary gland. *Arch Pathol Lab Med.* 2008;132(9):1445–7.
10. Hoorweg JJ, Hilgers FJ, Keus RB, Zoetmulder FA, Loftus BM. Metastasizing pleomorphic adenoma: a report of three cases. *Eur J Surg Oncol.* 1998;24(5):452–5.

Author biography

Lakshmi Agarwal, Assistant Professor  <https://orcid.org/0000-0002-9191-6406>

Vishakha Sharma, Post Graduate Student

Lokesh Rawat, Consultant Radiologist

Cite this article: Agarwal L, Sharma V, Rawat L. A rare case report of metastasizing pleomorphic adenoma of parotid gland. *IP Arch Cytol Histopathology Res* 2023;8(4):261-263.