

Content available at: <https://www.ipinnovative.com/open-access-journals>

IP Archives of Cytology and Histopathology Research

Journal homepage: <https://www.achr.co.in/>

## Original Research Article

## Assessment of immunohistochemical expression of trophoblast cell surface antigen 2 (Trop 2) in oral squamous cell carcinoma and its clinicopathological correlation

Nidhi Kaushal<sup>1\*</sup>, Mandakini S Mandale<sup>1</sup>, Jayanti G Humbe<sup>1</sup>,  
Vaishali Anil Nandkhedkar<sup>1</sup>, Savita Prashant Wagh<sup>1</sup>, Priyanka S Pachpande<sup>1</sup>

<sup>1</sup>Dept. of Pathology, Government Dental College & Hospital, Chhatrapati Sambhajinagar, Maharashtra, India



## ARTICLE INFO

## Article history:

Received 03-02-2024

Accepted 12-03-2024

Available online 04-05-2024

## Keywords:

Trophoblast

Oral squamous cell carcinoma

Trop 2

## ABSTRACT

**Introduction:** Trophoblast cell surface antigen 2 (Trop 2) is a transmembrane glycoprotein that is involved in a variety of oncogenic cell signaling pathways. Its heterogeneous expression in normal and cancerous tissues makes it a diagnostic and prognostic marker for various malignancies, including Oral Squamous Cell Carcinoma (OSCC).

**Aim:** To assess the immunohistochemical expression of Trop 2 in OSCC and evaluate its clinicopathological correlation.

**Materials and Methods:** Histopathologically diagnosed 40 cases of OSCC and their respective clinical records were retrieved and subsequent clinical staging and histopathological grading was done. Formalin fixed paraffin embedded sections were subjected to immunohistochemistry with anti Trop 2 antibody using standard DAB technique. The immunohistochemical expression of Trop 2 was evaluated using immunostaining intensity and mean integrated score followed by its comparison with age, gender, anatomical site, clinical stages and histopathological grades of OSCC.

**Results:** Trop 2 expression was positive in 97.5% of cases. There was a statistically significant difference (p value<0.001) between immunostaining intensity and integrated score of Trop 2 among various histopathological grades of OSCC. As grade of OSCC increased, integrated score decreased.

**Conclusion:** Trop 2 is one of the biomarkers that may serve as a useful tool to detect the changes undergoing at the molecular level which have prognostic or therapeutic significance.

This is an Open Access (OA) journal, and articles are distributed under the terms of the [Creative Commons Attribution-NonCommercial-ShareAlike 4.0 License](https://creativecommons.org/licenses/by-nc-sa/4.0/), which allows others to remix, tweak, and build upon the work non-commercially, as long as appropriate credit is given and the new creations are licensed under the identical terms.

For reprints contact: [reprint@ipinnovative.com](mailto:reprint@ipinnovative.com)

### 1. Introduction

Oral squamous cell carcinoma (OSCC) is the 6<sup>th</sup> most common malignant tumor type worldwide. OSCC accounts for 24% of all head and neck cancers.<sup>1</sup> Various etiological factors for OSSC include tobacco consumption, chronic irritation and HPV 16 and 18<sup>2</sup> or may be preceded by potentially malignant disorders, like oral submucous fibrosis (OSMF), oral leukoplakia (OLK), and oral lichen planus (OLP).<sup>3</sup>

Despite numerous advances in diagnosis and treatment of OSCC including surgery, chemotherapy or radiotherapy over the last decades, mortality rates have remained unchanged. The 5-year survival rate is about 40–50%.<sup>4</sup>

While undergoing malignant transformation, the tissue undergoes various structural, molecular and functional changes. Identification of such molecular changes may help in early diagnosis, in understanding tumor behavior, and in precise stratification of patients into different risk categories. Therefore, molecular pathology using the potential biomarkers for diagnosis, prognosis and therapeutics can be applied for better patient outcome.<sup>5</sup>

\* Corresponding author.

E-mail address: [kaushalnidhi16@gmail.com](mailto:kaushalnidhi16@gmail.com) (N. Kaushal).

Trophoblast cell surface Antigen 2 (Trop 2) is a transmembrane glycoprotein of 35 kDa, an important factor in trophoblasts in placenta, and during embryonic growth and development. High expression of Trop 2 is expressed in most human cancers including ovarian, gastric, colorectal, pancreatic, and laryngeal cancers.<sup>6</sup> However, there are specific cancer types in which Trop 2 is downregulated i.e., loss of Trop 2 was identified in poorly differentiated SCC tissues collected from cervix, esophagus, head and neck.<sup>7</sup>

Hence, Trop 2 is one of the cancer biokmarkers that can serve as a useful tool to detect the changes undergoing at the molecular level. Its biological function and prognostic role in OSCC needs to be further established. The aim of the study was to assess the immunohistochemical expression of Trop 2 in oral squamous cell carcinoma. Its immunohistochemical expression was evaluated using immunostaining intensity and mean integrated score followed by its comparison with age, gender, anatomical site, clinical stages and histopathological grades of OSCC.

## 2. Materials and Methods

Paraffin embedded oral tissue samples of 40 histopathologically diagnosed OSCC cases were obtained. All the patients who had received or were receiving treatment for OSCC, or with a history of any other neoplastic disease were excluded. The clinicopathological information in each case, including age, sex, tumor site, tumor size and lymph node metastases was obtained from patient records. Clinical staging of the oral squamous cell carcinoma patients was done according to the TNM classification as given by American Joint Committee for Cancer staging and End results reporting (AJCCS, 2009).<sup>8</sup> The histopathological grading of oral squamous cell carcinoma was done according to the malignancy grading system proposed by Anneroth G et al (1987).<sup>9</sup>

Tissue sections from each OSCC were subjected to immunohistochemical staining for Trop 2. Each 4 micron tissue section was dewaxed and rehydrated in an alcohol gradient. Antigen retrieval was performed using EZ retrieval solution in a pressure cooker. Following this, all the incubations of sections with peroxide block, power block, primary antibody, super-enhancer and secondary antibody were performed at room temperature using a humidifying chamber. The slides were then immersed in Mayer's haematoxylin for 2 minutes, washed gently in tap water and then kept under running water for 2 minutes followed by mounting using DPX and observed under microscope.

The presence of brown coloured end product at the site of target antigen was indicative of positive immunoreactivity. The semi-quantitative H-score method was used to score Trop 2 expression which took into account both the percentage of positively stained cells and the intensity of staining, i.e;

Immunoreactivity Score = % of proportion of positive cells X Staining intensity

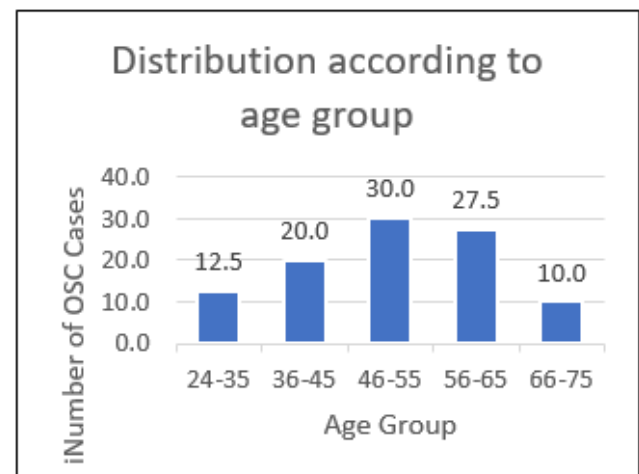
The proportion of positive cells was scored as 0 for 0-4%, 1 for 5-19%, 2 for 20-39%, 3 for 40-59%, 4 for 60-79% and 5 for 80-100%. The staining intensity was scored as 0 for negative intensity, 1 for weak intensity, 2 for moderate intensity and 3 for strong intensity.<sup>10</sup>

The results were tabulated according to age, gender, anatomical site, clinical staging and histopathological grading along with Trop 2 expression i.e immunostaining intensity and mean integrated score. Statistical analysis was applied to find correlations regarding Trop 2 expression among various clinical stages and histopathological grades of OSCC.

## 3. Results

The present study included total 40 subjects of histopathologically diagnosed OSCC. Demographic findings of all study subjects were recorded and were correlated with Trop 2 expression, i.e., its Immunostaining intensity were analyzed using Image J software.

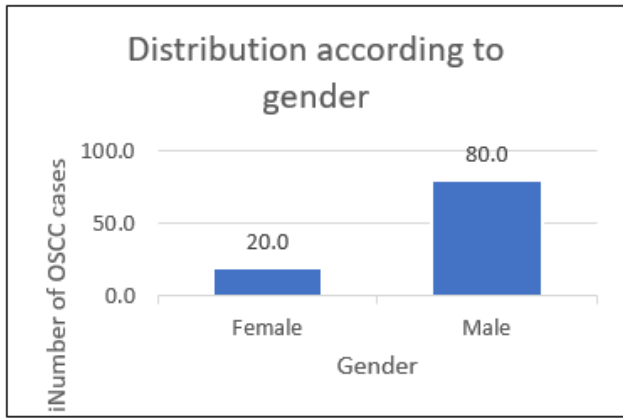
In the present study the age of OSCC cases ranged from 24- 75 years, with mean age values of  $48.24 \pm 11.61$  years. OSCC was found to be common in the age group of 46-55 years (30%) {Graph 1}. 80% males were involved in the diagnosis of OSCC giving male: female ratio of 4:1 {Graph 2}.



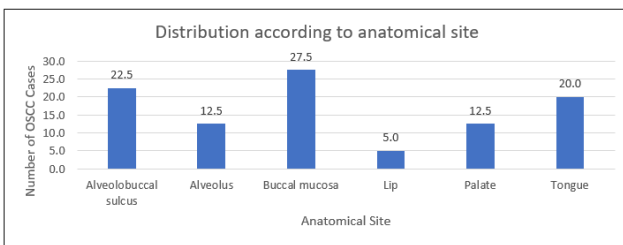
Graph 1: Age wise distribution of OSCC cases

In this study, OSCC cases involved different anatomical sites, including buccal mucosa(27.5%) being most common site, followed by alveolobuccal mucosa (22.5%), tongue (20%), alveolus (12.5%), palate (12.5%) and lips (5%) {Graph 3}.

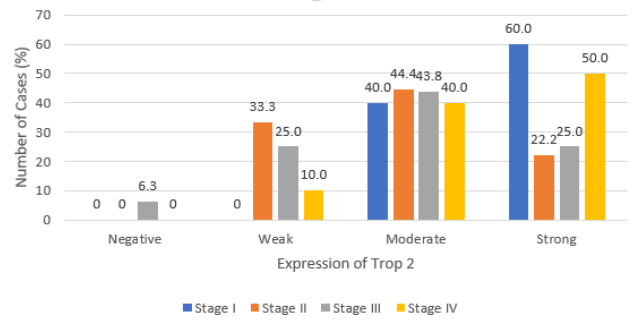
The expression of Trop 2 was compared with age, gender and anatomical sites in OSCC cases. The difference for Trop 2 immunostaining intensity and integrated score in different



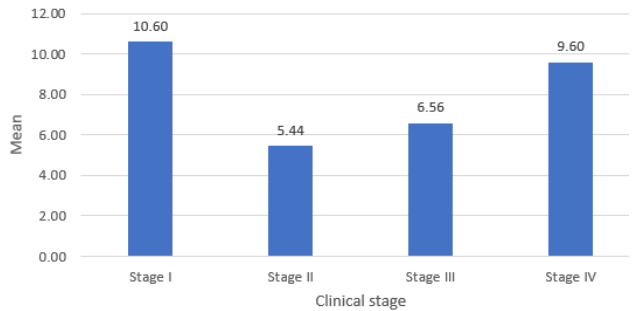
Graph 2: Gender wise distribution of OSCC cases



Graph 3: Anatomical site wise distribution of OSCC cases



Graph 4: Expression of Trop 2 with clinical stages



Graph 5: Mean integrated score

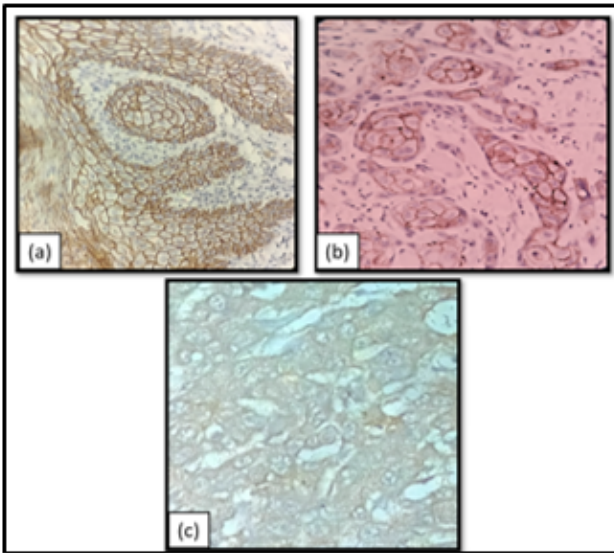
age groups, gender and anatomical sites among OSCC cases was statistically non-significant with p value 0.205, 0.472 and 0.347 respectively.

Clinical staging was done using TNM classification as given by American Joint Committee for Cancer staging and End results reporting (AJCCS, 2009).<sup>11</sup> Out of 40 cases of OSCC, 05 (12.5%) were Stage I, 09 (22.5%) were Stage II, 16 (40%) were Stage III and 10 (25%) were Stage IV. Amongst cases in stage I, 03(60%) showed strong and 02(40%) showed moderate immunostaining intensity. Stage II showed strong, moderate and weak immunostaining intensity in 02 (22.2%) cases, 04 (44.4%) cases and 03 (33.3%) cases respectively. In stage III, strong staining intensity was seen in 04 (25%) cases, whereas moderate, weak intensity and negative expression was evident in 07(43.8%), 04 (25%), and 01(6.3%) cases respectively. Stage IV showed strong, moderate and weak immunostaining intensity in 05 (50%), 04 (40%) and 01 (10%) cases respectively. On comparing, Chi square test revealed that the difference in immunostaining intensity for Trop 2 in all stage I, stage II, stage III and stage IV cases was not statistically significant ( $p=0.694$ ). Mean integrated score for clinical stage I was  $10.6 \pm 3.5$ , for stage II is  $5.4 \pm 3.1$ , for stage III is  $6.5 \pm 4.4$  and for stage IV is  $9.6 \pm 4.8$ . There was no statistically significant association between mean integrated score of Trop 2 expression and clinical staging of OSCC. {Graphs 4 and 5}

Distribution and comparison of immunostaining intensity (Graph 4) and integrated score (Graph 5) of Trop 2 expression among various clinical stages of OSCC

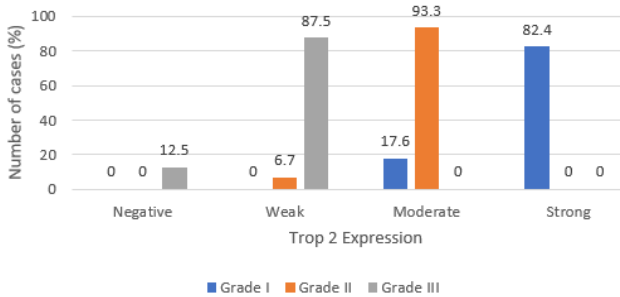
Histopathological grading was done using the multifactorial grading system by Anneroth et al (1987). He used six morphological parameters to grade malignancy, which included degree of keratinization, nuclear polymorphism, number of mitosis/high power field, pattern of invasion, stage of invasion and lymphoplasmacytic infiltrate. Out of 40 cases of OSCC, 17(42.5%) were in Grade I, 15(37.5%) were in Grade II and 08(20%) were in Grade III. In grade I, Trop 2 expression showed strong and moderate staining intensity in 14(82.4%) and 03(17.6%) cases respectively. In grade II, intensity of Trop 2 expression varied from moderate in 14(93.3%) cases and weak in 01(6.7%) cases. Grade III cases showed weak immunostaining intensity in 07(87.5%) cases and remaining 01(12.5%) cases showed negative expression of Trop 2. (Figure 1)

It was seen that, as histopathological grade increased immunostaining intensity for Trop 2 decreased. On comparing by Chi square test, the difference in staining intensities for Trop 2 between all the grades (I, II, III) was found highly statistically significant ( $p<0.001$ ). Mean integrated score of Grade I is  $11.8 \pm 2.6$ , for Grade II is  $5.8 \pm 1.4$  and for Grade III is  $1.7 \pm 1.03$ . There is statistically significant difference ( $p \text{ value} < 0.001$ ) between integrated score among various histopathological grades of OSCC.

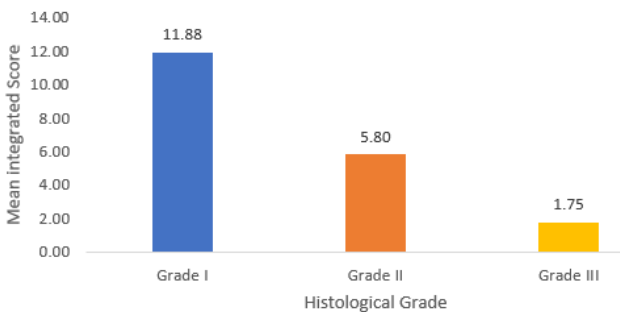


**Figure 1:** Immunohistochemical expression of Trop 2 in Grade I (a), Grade I (b) and Grade III (c) Oral Squamous cell carcinoma (400x)

As grade of OSCC increased, integrated score decreased. (Graph 6, 7)



**Graph 6:** Comparison of histological grade with expression of Trop 2



**Graph 7:** Mean integrated score

Distribution and comparison of immunostaining intensity (Graph 6) and integrated score (Graph 7) of Trop 2 expression among various histopathological grades of OSCC

#### 4. Discussion

Even though rapid advances have been made in the field of medicine and surgery, cancer is the leading cause for human mortality. It is estimated that more than one million new oral cancer cases are being detected annually in the Indian subcontinent, of which 90% are OSCC. The current mortality rate attributed to oral cancer can be reduced greatly if early signs and symptoms are given an adequate attention. Thus detection of oral cancer at an early stage is the most effective means to improve survival and reduce morbidity, disfigurement, duration of treatment and hospital costs associated with this disease.<sup>12,13</sup> Lack of public awareness about the signs, symptoms and risk factors, along with the absence of knowledge for early detection by health-care providers are believed to be responsible for this diagnostic delay and treatment initiation. It has been established by researchers that virtually all OSCC's arise de novo or are preceded by oral potentially malignant disorders.<sup>14</sup>

Research on cancer tissues has revealed that there may be a link between molecular level and tissue level changes that drive malignant changes in the tissue and play a pivotal role in disease progression. While undergoing malignant transformation, the tissue undergoes various structural, molecular and functional changes i.e. impaired DNA replication, uncontrolled proliferation of cells, epithelial–mesenchymal transition, loss of cell adhesion, increased cell motility etc. Early in OSCC, molecular changes are evident at cellular level even in the absence of phenotypic changes in the tissue. Identification of such molecular changes may help in early diagnosis, in understanding tumor behavior and in precise stratification of patients into different risk categories. Therefore, molecular pathology using the potential biomarkers for diagnosis, prognosis and therapeutics can be applied for better patient outcome.<sup>5</sup>

Trophoblast cell surface Antigen 2 (Trop 2) is a transmembrane glycoprotein and an epithelial cell adhesion molecule (EpCAM) family member. It was originally identified by its high expression on human trophoblast cells<sup>7</sup> Cancerous tissues show dysregulated expression of this molecule indicating its prognostic significance and making it a promising target for both direct and indirect therapies.<sup>15</sup>

Cell signaling mediated by Trop-2 involves the expression of Ki-67, activation of MAPK signaling and cell cycle progression by increasing levels of cyclin D1. Trop-2 expression can induce transcription factor AP-1 leading to upregulation of carcinogenesis associated genes. These pathways are often deregulated during tumorigenesis and

may be associated with modulation of Trop2 expression in malignant cells.<sup>16</sup>

Trop 2 contains phosphorylation sites in its cytoplasmic tail, and for that reason, the protein has been involved in several intracellular signaling pathways like calcium transportation, Akt pathway, MAPK/ERK, TGF-Beta, WNT, JAK STAT pathways, hence promoting cell proliferation. Trop 2 binds with claudin 1, claudin 7, cyclin d1, protein kinase C and insulin growth factor 1. It activates the extracellular signal regulated kinase/ mitogen activated protein kinase (ERK/MAPK) pathways. Mitogen expression increases levels of phosphorylated MAPK (ERK 1/ERK 2), which may inhibit the apoptosis of tumor cells and govern cell cycle progression. Then, the ERK pathway regulates the transition from G1 to S phase. Cyclin D is a downstream target of Trop 2 expression, related to the termination of G0-G1 cycle arrest and S phase progression, which contributes to tumor pathogenesis by activating the ERK pathway. Therefore, Trop 2 expression can lead to tumorigenic properties and increased proliferation, invasiveness and metastasis.<sup>17</sup>

Dysregulation of Trop 2 can be expressed in many cancer. In general, correlating with an unfavourable prognosis and increased risk of metastasis in tumors.

Oral squamous cell carcinoma is predominantly a disease of middle-aged populations who is affected with adverse oral habits and alcoholism. Approximately 95% of cancers occur after the age of 45, with an average age of 60 years. In the present study, age of the OSCC patients ranged from 24-75 years with a mean value of  $48.24 \pm 11.61$ . Peak incidence of OSCC was seen in 4<sup>th</sup>-5<sup>th</sup> decade comprising of about 30% of study population.

Considering the gender in all the age groups in OSCC, men are more affected than women. In India, men are two to four times more affected than women due to the changes in the behavioural and lifestyle patterns. A strong male predominance was observed in the current study in the study groups with M:F ratio 4:1 for OSCC cases.

Worldwide, most frequent sites for OSCC are tongue, lip and floor of mouth. In Indian population most common sites of involvement are buccal mucosa and alveolobuccal complex. In the present study, buccal mucosa was the most common site with 11 cases (27.5%) to be involved in OSCC patients followed by alveolobuccal complex 09(22.5%) In case of buccal mucosa, it may be due to the fact that most of the patients tend to keep the tobacco in the form of quid in the buccal sulcus with close proximity to buccal mucosa and alveolus. Collectively, buccal mucosa and alveolobuccal complex comprised 20 (50%) cases. The high prevalence of cancer in these regions may be due to two facts. The first is that, it may be accounted by habitual compression of the betel quid against these regions providing direct access for carcinogens from the quid. Another possibility can be attributed to the chronic mechanical repetitive

irritation caused by tobacco and betel quid which renders the mucosa more susceptible to carcinogens. The other possible explanation could be that when tobacco is smoked or chewed, its noxious agents get dissolved in saliva. Normally some saliva remains constantly in the vestibule of the mouth, facilitating greater and prolonged contact of tobacco carcinogens with buccal mucosa and vestibule.<sup>18</sup>

In the present study we found a statistically non-significant difference between the Trop 2 expression (immunostaining intensity and mean integrated score) and the patients's age, sex and anatomical site which was in accordance with the findings of Fong D et al(2008),<sup>18</sup> Tang G et al (2018),<sup>17</sup> Zhang B et al (2020)<sup>19</sup> and Dourado MR et al (2021).<sup>20</sup>

In the present study, 12.5 % (n=05) cases belonged to Stage I, 22.5% (n=9) cases belonged to stage II and bulk was seen in stage III and stage IV with 40% (n=16) and 25% (n=10) cases respectively. This was in accordance with Singh MP et al (2015),<sup>11</sup> Bazzano M et al (2022),<sup>21</sup> who showed approximately 70-80% of cases in Stage IV of OSCC. This was attributed to diagnostic delay due to lack of knowledge regarding OSCC and its related risk factors among patients. In addition, the absence of pathognomonic signs or symptoms of OSCC often leads the patients to incorrectly attribute these signs or symptoms to infections or dental problems.

Histopathologically, 42.5% (n=17) cases belonged to grade I, 37.5% (n=15) belonged to grade II and remaining 20% (n=8) belonged to grade III according to Anneroth's grading criteria. This was in accordance with Babu C et al (2021)<sup>22</sup> who observed 58% cases of Grade I, 39% cases of Grade II and 2% cases of Grade III in his study.

In the present study, Trop 2 expression in OSCC cases was positive in 97.5% cases, located primarily on the cell membrane of epithelial cells.<sup>18</sup> Expression of Trop 2 was localised on cell membrane of normal and neoplastic cells with variable intensities. In normal epithelium, the expression was in well keratinized layers of epithelium like startum corneum, stratum granulosum and stratum spinosum, but was absent in stratum basale. In neoplastic epithelial cells, Trop 2 expression was strongly observed in well differentiated layers of tumor as well as in the basal / parabasal layers.

There was variability in intensity of expression of Trop 2, which was described as weak, moderate and strong expression. 14 (35%) cases showed strong expression, 17(42.5%) showed moderate expression and 08(20%) showed weak expression of Trop 2. Amongst all the cases, 01(2.5%) did not show Trop 2 expression. This was in accordance with similar positivity reported by Zhang B et al (2020),<sup>19</sup> Jia L et al (2020),<sup>23</sup> Erber R et al (2021)<sup>24</sup> and Dourado MR et al (2021).<sup>20</sup>

Among 97.5% Trop 2 positive cases of OSCC, staining intensity for Trop 2 varied between various clinical stages.

In stage I, intensity of Trop 2 varied as strong (60%) and moderate (40%) staining intensity. In stage II, cases showed strong, moderate and weak intensity in 22.2%, 44.4% and 33.3% cases respectively. In stage III, strong, moderate and weak intensity was observed in 25%, 43.8%, 25% cases respectively. One case (6.3%) in stage III showed negative staining with Trop 2. In stage IV, 50%, 40% and 10% cases showed strong, moderate and weak intensity respectively. These findings were in favour with Zhang B et al (2020).<sup>19</sup>

In the present study, no significant differences regarding immunostaining intensity ( $p=0.694$ ) and mean integrated score ( $p=0.060$ ) for Trop 2 expression were found among clinical stages of OSCC. This result is in congruence with Fong D et al (2007),<sup>18</sup> Tang G et al(2018),<sup>17</sup> Zhang B et al(2020)<sup>19</sup> and Dourado MR et al(2021).<sup>20</sup>

In the present study, among positive cases of OSCC, immunostaining intensity for Trop 2 varied widely between different histopathological grades of OSCC. Trop 2 expression varied from strong and moderate intensity in Grade I of OSSC cases as 82.4% ( $n=14$ ) and 17.6% ( $n=3$ ) respectively. None of the cases in Grade I showed weak or negative immunostaining intensity. These findings are comparable with those of Dourado MR et al(2021)<sup>20</sup> In grade II, majority of the cases exhibited moderate expression, constituting 93.3% ( $n=14$ ) of OSCC cases. Only 6.7% ( $n=1$ ) showed weak expression of Trop 2. These results were in accordance with the findings of Dourado MR et al (2021)<sup>20</sup> In grade III, immunostaining intensity was weak in 87.5% ( $n=7$ ) cases and negative in 12.5% ( $n=1$ ) cases. This finding is consistent with Wang F et al(2014)<sup>7</sup> and Dourado MR et al(2021).<sup>20</sup> Hence, there was statistically significant correlation present between histological grade and Trop 2 staining intensity. As the grade of OSCC increased, the Trop 2 staining intensity decreased and vice versa.

Thus, Trop 2 staining was heterogenous and was detected in well-differentiated epithelial cells. Compared with poorly differentiated OSCCs, a higher percentage of Trop 2 expression was identified in well and moderately differentiated SCCs, indicating that loss of Trop 2 is a hallmark of the stepwise progression of SCC. Hence, the immunostaining intensity and mean integrated score of Trop 2 decreases as the histopathological grade increases. Similar inverse correlation between Trop 2 expression and histopathological grade of OSCC was reported by Wang F et al (2014)<sup>7</sup> and Dourado MR et al(2021).<sup>20</sup>

In stratified squamous epithelia, cell membrane staining of Trop 2 was detected in differentiated keratinocytes in the stratum spinosum, stratum granulosum and stratum corneum, whereas staining of Trop 2 was absent in less differentiated keratinocytes in the stratum basal/parabasal layers. These results indicated that expression and cell membrane localization of Trop 2 is tightly associated with differentiated keratinocytes. Disruption of keratinocyte differentiation has critical roles in OSCC progression. Trop

2 loss with Grade III OSCC is observed due to disruption in apoptosis and keratinocyte differentiation.<sup>7</sup>

Hence, the present study showed statistically significant ( $p=0.001$ ) difference between the histopathological grades (I, II and III) of OSCC regarding Immunostaining intensity and mean integrated score for Trop 2 expression. Membrane accumulation of Trop 2 associated with increased cellular proliferation and disrupted apoptosis supports the role of Trop 2 as a prognostic marker. This provides insight into its utility as a diagnostic and prognostic marker and its further exploitation as a target for cancer therapies.<sup>25</sup> Thus, the present study showed significant association between degree of differentiation and immunohistochemical expression of Trop 2.

## 5. Conclusion

Despite a continuous refinement of TNM staging system to express disease extent and define prognosis which will eventually guide the treatment, mortality and morbidity rates of OSCC are still exceedingly high. Outcome of patients with cancer may vary considerably even within the same tumor stage. Therefore, the need for new factors, either morphologic or molecular, could more precisely stratify patients into different risk categories is clearly warranted.<sup>26</sup>

An upcoming all-inclusive molecular and clinical staging system will allow a more accurate selection of patients that should undergo more aggressive, specific, or individualized cancer therapy.<sup>26,27</sup> Similar effort was made in present study to investigate and validate the probable use of immunohistochemical expression of Trop 2 (Immunostaining intensity) as a prognostic marker in OSCC patients.

Trop 2 expression, considered as a transmembrane protein, has been described in many non-neoplastic cells but also in cancer cells. Moreover, it has been discussed as a stem/progenitor cell biomarker and reported to be a calcium signal transducer. Trop 2 has a regulatory function within several signaling pathways, including PI3K/Akt, MAPK/ERK, ErbB, TGF-beta, Wnt/beta-catenin, JAK/STAT, integrin and adherent and tight junction signaling pathways. Due to both the activating and inhibiting capabilities of Trop 2, it is supposed that the function is context-dependent. Hence, Trop 2 is one of the biomarkers that may serve as a useful tool to detect the changes undergoing at the molecular level which have prognostic or therapeutic significance.<sup>25</sup>

## 6. Source of Funding

None.

## 7. Conflict of Interest

None.


## References


- Georgaki M, Theofilou VI, Pettas E, Stoufi E, Younis RH, Kolokotronis A, et al. Understanding the complex pathogenesis of oral cancer: A comprehensive review. *Oral Surg Oral Med Oral Pathol Oral Radiol*. 2021;132(5):566–79.
- Varshitha A. Prevalence of oral cancer in India. *J Pharm Sci Res*. 2015;7(10):845–8.
- Upadhaya P, Barhoi D, Giri A, Bhattacharjee A, Giri S. Joint detection of claudin-1 and junctional adhesion molecule-A as a therapeutic target in oral epithelial dysplasia and oral squamous cell carcinoma. *J Cell Biochem*. 2019;120(10):18117–27.
- Crissman JD, Liu WY, Gluckman JL, Cummings G. Prognostic value of histopathologic parameters in squamous cell carcinoma of the oropharynx. *Cancer*. 1984;54(12):2995–3001.
- Kesting MR, Sudhoff H, Hasler RJ, Nieberler M, Pautke C, Wolff KD. Psoriasis (S100A7) up-regulation in oral squamous cell carcinoma and its relation to clinicopathologic features. *Oral Oncol*. 2009;45(8):731–6.
- Tang G, Tang Q, Jia L, Xia S, Li J, Chen Y, et al. High expression of TROP2 is correlated with poor prognosis of oral squamous cell carcinoma. *Pathol Res Pract*. 2018;214(10):1606–12.
- Wang F, Liu X, Yang P, Guo L, Liu C, Li H, et al. Loss of TACSTD2 contributed to squamous cell carcinoma progression through attenuating TAp63-dependent apoptosis. *Cell Death Dis*. 2014;5(3):1133. doi:10.1038/cddis.2014.96.
- Edge SB, Compton CC. The American Joint Committee on Cancer: the 7th edition of the AJCC cancer staging manual and the future of TNM. *Ann Surg Oncol*. 2010;17(6):1471–4.
- Anneroth G, Batsakis J, Luna M. Review of the literature and a recommended system of malignancy grading in oral squamous cell carcinomas. *Scand J Dent Res*. 1987;95(3):229–49.
- Detre S, Jotti GS, Dowsett M. A "quickscore" method for immunohistochemical semiquantitation: validation for oestrogen receptor in breast carcinomas. *J Clin Pathol*. 1995;48(9):876–8.
- Singh MP, Kumar V, Agarwal A, Kumar R, Bhatt ML, Misra S, et al. Clinico-epidemiological study of oral squamous cell carcinoma: A tertiary care centre study in North India. *J Oral Biol Craniofac Res*. 2016;6(1):32–4.
- Warnakulasuriya S. Global epidemiology of oral and oropharyngeal cancer. *Oral Oncol*. 2009;45(4-5):309–16.
- Mathur A, Jain M, Shiva M, Navlakha M, Prabu, Kulkarni S, et al. Tobacco Habits and Risk of Oral Cancer: A Retrospective Study in Ind. *Iran J Blood Cancer*. 2009;1(3):111–6.
- Fedele S. Diagnostic aids in the screening of oral cancer. *Head Neck Oncol*. 2009;1(1):5. doi:10.1186/1758-3284-1-5.
- Cubas R, Zhang S, Li M, Chen C, Yao Q. Trop 2 expression contributes to tumor pathogenesis by activating the ERK MAPK pathway. *Mol Cancer*. 2010;9(1):253. doi:10.1186/1476-4598-9-253.
- Stepan LP, Trueblood ES, Hale K, Babcook J, Borges L, Sutherland CL, et al. Expression of Trop2 cell surface glycoprotein in normal and tumor tissues: potential implications as a cancer therapeutic target. *J Histochem Cytochem*. 2011;59(7):701–10.
- Tang G, Tang Q, Jia L, Xia S, Li J, Chen Y, et al. High expression of TROP2 is correlated with poor prognosis of oral squamous cell carcinoma. *Pathol Res Pract*. 2018;214(10):1606–12.
- Fong D, Spizzo G, Gostner JM, Gastl G, Moser P, Krammel C, et al. TROP2: a novel prognostic marker in squamous cell carcinoma of the oral cavity. *Mod Pathol*. 2008;21(2):186–91.
- Zhang B, Gao S, Li R, Li Y, Cao R, Cheng J, et al. Tissue mechanics and expression of TROP2 in oral squamous cell carcinoma with varying differentiation. *BMC Cancer*. 2020;20(1):815. doi:10.1186/s12885-020-07257-7.
- Dourado MR, Machado RA, Paranaíba LM, González-Arriagada WA, Silva SD, Sawazaki-Calone I, et al. Trophoblast cell surface antigen 2 expression predicts outcome in oral squamous cell carcinomas. *Oral Dis*. 2022;28(4):1085–93.
- Bazzano M, Mauceri R, Coppini M, Mantia G, Tozzo P, Caponio V, et al. Oral squamous cell carcinoma and patients delay: a systematic review. Abstractcduo-book-Digital Dentistry: la sfida del presente verso il futuro; 2022. Available from: <https://iris.unipa.it/handle/10447/567244>.
- Babu C, Pereira T, Shetty S, Shrikant G, Anjali A, Vidhale R, et al. Epidemiological trends of oral squamous cell carcinoma – An institutional study. *Muller J Med Sci Res*. 2021;12(1):1–5.
- Jia L, Wang T, Ding G, Kuai X, Wang X, Wang B, et al. Trop2 inhibition of P16 expression and the cell cycle promotes intracellular calcium release in OSCC. *Int J Biol Macromol*. 2020;164:2409–17. doi:10.1016/j.ijbiomac.2020.07.234.
- Erber R, Spoerl S, Mamilos A, Krupar R, Hartmann A, Ruebner M, et al. Impact of Spatially Heterogeneous Trop-2 Expression on Prognosis in Oral Squamous Cell Carcinoma. *Int J Mol Sci*. 2021;23(1):87. doi:10.3390/ijms23010087.
- Goldenberg DM, Stein R, Sharkey RM. The emergence of trophoblast cell-surface antigen 2 (TROP-2) as a novel cancer target. *Oncotarget*. 2018;9(48):28989–6.
- Chimeno-Küstner E, Font-Costa I, López-López J, J. Oral cancer risk and molecular markers. *Med Oral Patol Oral Cir Bucal*. 2004;9(5):381–4.
- Tannapfel A, Weber A. Tumor markers in squamous cell carcinoma of the head and neck: clinical effectiveness and prognostic value. *Eur Arch Otorhinolaryngol*. 2001;258(2):83–8.


## Author biography


**Nidhi Kaushal**, Assistant Professor

**Mandakini S Mandale**, Professor  <https://orcid.org/0000-0002-7878-2888>

**Jayanti G Humbe**, Associate Professor  <https://orcid.org/0000-0003-1926-915X>

**Vaishali Anil Nandkhedkar**, Assistant Professor  <https://orcid.org/0000-0001-9676-7182>

**Savita Prashant Wagh**, Assistant Professor  <https://orcid.org/0000-0002-9737-7941>

**Priyanka S Pachpande**, Assistant Professor  <https://orcid.org/0000-0003-0382-0779>

**Cite this article:** Kaushal N, Mandale MS, Humbe JG, Nandkhedkar VA, Wagh SP, Pachpande PS. Assessment of immunohistochemical expression of trophoblast cell surface antigen 2 (Trop 2) in oral squamous cell carcinoma and its clinicopathological correlation. *IP Arch Cytol Histopathology Res* 2024;9(1):23-29.