

Content available at: <https://www.ipinnovative.com/open-access-journals>

IP Archives of Cytology and Histopathology Research

Journal homepage: <https://www.achr.co.in/>

## Case Report

# Dermatopathological diagnosis of porphyria cutanea tarda - Two case reports

Chatura KR<sup>1\*</sup>, Swapnika Goud G<sup>1</sup>, Monish Ram S D<sup>1</sup>

<sup>1</sup>Dept. of Pathology, J.J.M. Medical College, Davangere, Karnataka, India



### ARTICLE INFO

#### Article history:

Received 24-01-2024

Accepted 16-02-2024

Available online 04-05-2024

#### Keywords:

Porphyria cutanea tarda  
HIV and Hepatitis C

### ABSTRACT

Porphyria cutanea tarda and its relationship with HIV and Hepatitis C are highlighted in the case reports. Porphyria cutanea tarda arises from a deficiency in the uroporphyrinogen decarboxylase enzyme, where there is an anomaly in the buildup of specific porphyrins, notably in blood vessels, liver, and skin. It can be either hereditary or acquired. In this context, we have discussed two individual patients with HIV and Hepatitis C who were diagnosed with porphyria cutanea tarda through skin biopsy.

This is an Open Access (OA) journal, and articles are distributed under the terms of the [Creative Commons Attribution-NonCommercial-ShareAlike 4.0 License](https://creativecommons.org/licenses/by-nc-sa/4.0/), which allows others to remix, tweak, and build upon the work non-commercially, as long as appropriate credit is given and the new creations are licensed under the identical terms.

For reprints contact: [reprint@ipinnovative.com](mailto:reprint@ipinnovative.com)

## 1. Introduction

Porphyria cutanea tarda (PCT) a prevalent form of porphyria, typically emerges as an acquired liver disease influenced by exogenous factors, commonly excess alcohol intake, iron overload, chronic hepatitis C, estrogen therapy, and cigarette smoking.<sup>1</sup> The enzymatic activity of uroporphyrinogen decarboxylase (UROD) is crucial for porphyrin metabolism, specifically converting uroporphyrinogen to protoporphyrin.<sup>2</sup> Insufficient functional UROD leads to abnormal accumulation of specific porphyrins in the body, especially in blood vessels, liver, and skin. Inborn errors in the metabolism of porphyrins are rare across the world, unlike PCT.

## 2. Case Report

### 2.1. Case 1

A 45-year-old HIV-positive patient, diagnosed ten years ago and on ART treatment for ten years presented to the skin outpatient with recurrent bullae over the bilateral dorsum of hands and feet for 6 months. They ruptured on scratching

and healed with depigmentation and atrophy. He also had ulcerated plaques with crusting over the dorsum of hands, feet, and face with photosensitivity.

On examination patient had multiple depigmented patches with crusting, and multiple dense bullae with few atrophic scars present over the dorsum of both hands, palms, soles, and feet with sparing of mucosal areas. (Figure 1) Liver function tests were within normal range. Serology for HCV was non-reactive. The previous CD4 count was 189 cells/mm<sup>3</sup>. The urine fluorescence test with Wood's lamp showed reddish-pink fluorescence confirming the presence of uroporphyrin. (Figure 2)

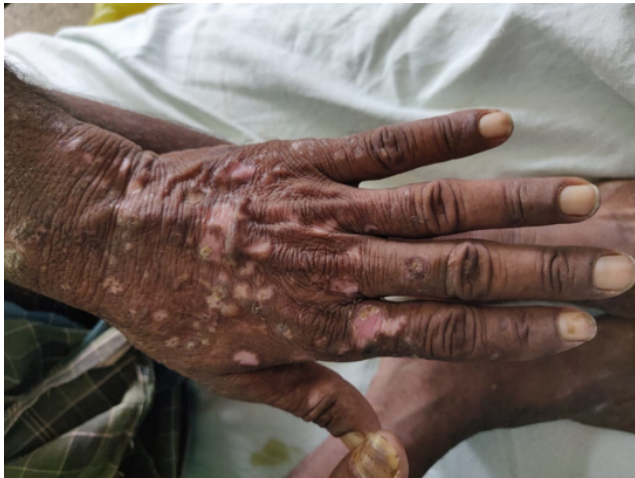### 2.2. Case 2

A 42 years male with, a known case of decompensated chronic liver disease presented to dermatology OPD with complaints of pruritic skin lesions over bilateral palms, feet, and legs for 4 days, and with bilateral pedal edema.

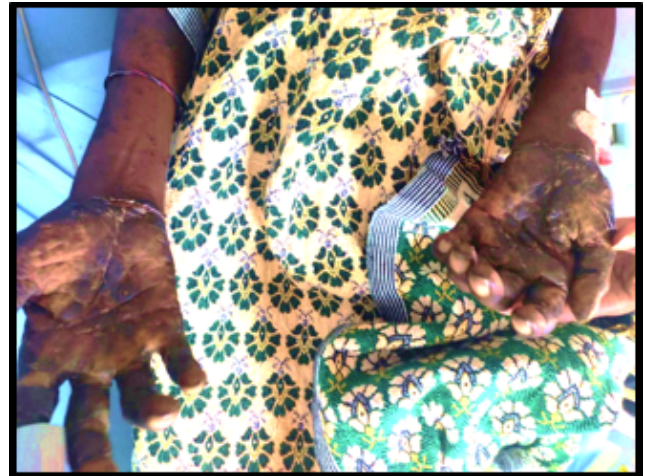On examination, dark brown ill-defined plaques and papules were noted over bilateral palms, abdomen, and legs along with ill-defined bullae over bilateral legs. (Figures 3 and 4)

\* Corresponding author.


E-mail address: [swapnikgoud12@gmail.com](mailto:swapnikgoud12@gmail.com) (Chatura KR).



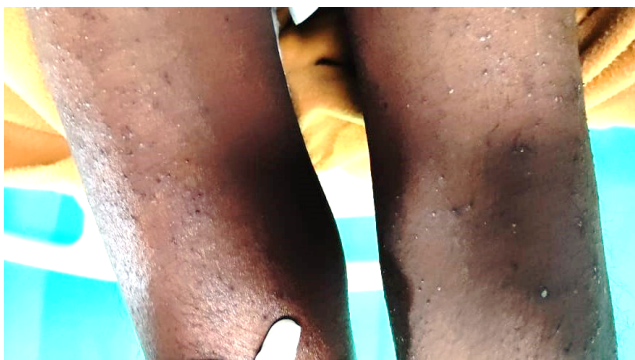**Figure 1:** Hypopigmented lesions on the dorsal aspect of the hand



**Figure 4:** Hypopigmented lesions over bilateral palms



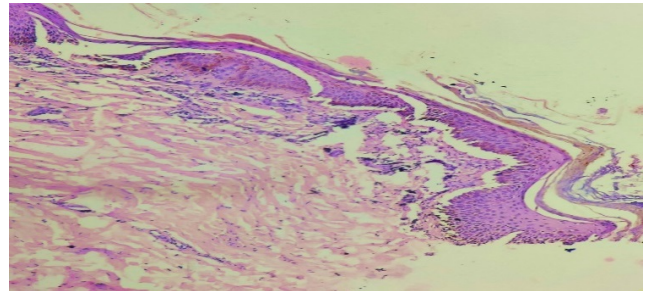
**Figure 2:** Urine fluorescence test with Wood's lamp in the patient sample on the left and control sample on the right



**Figure 3:** Papules in lower extremities

Biochemical investigations showed Total Bilirubin – 13.2 mg/dl, Conjugated Bilirubin – 11.5 mg/dl, Unconjugated bilirubin – 1.7 mg/dl, SGOT – 55.0 U/L, SGPT – 33.0 U/L, ALP – 192.0 U/L. Urea – 64.0 mg/dl. Serology was positive for HCV.

In both cases, skin biopsy of the bullous lesion showed on histopathological examination a subepidermal blister with dermal papillae extending irregularly from the floor into the bullae cavity. This phenomenon is festooning. (Figure 5)

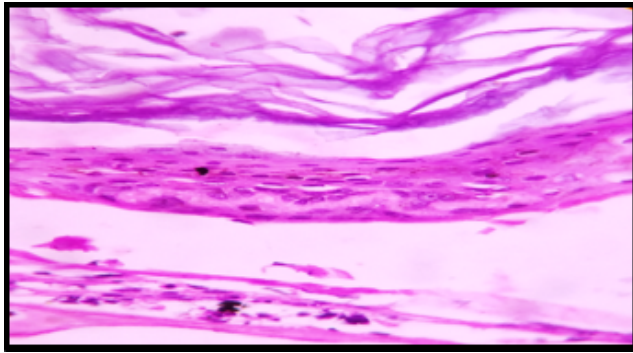


**Figure 5:** Case 1

The epidermis forming the roof of the blister contained eosinophilic bodies that were elongated and segmented called caterpillar bodies. (Figure 6) All these features were suggestive of porphyria cutanea tarda.

### 3. Discussion

PCT typically presents as a chronic, gradually progressive cutaneous disorder, with vesicles, milia, and bullae on the backs of the hands and forearms.<sup>1</sup> Clinical features rarely develop unless there is at least a 75% decrease in the activity of hepatic uroporphyrinogen decarboxylase. PCT is a heterogeneous disease and has been classified into three subtypes. Type I, accounting for 75-80%, is acquired PCT, in which deficiency of UROD is limited to hepatocytes.



**Figure 6:** Caterpillar body in the epidermis

Leading environmental factors are alcohol usage and the presence of hepatitis C or HIV.<sup>3</sup>

The diagnosis of PCT preceded the detection of HIV infection in 40% of cases.<sup>4</sup>

Although PCT in HIV-infected persons develops and may be diagnosed a decade earlier as compared to non-HIV-infected persons, it may also be diagnosed concurrently or later, suggesting that HIV per se and not reduced immune status precipitates porphyria.<sup>5</sup>

The prevalence of hepatitis C virus infection was retrospectively studied in 87 patients during a period of 11 years. Among patients with the sporadic form of PCT, the prevalence of hepatitis C virus infection was 36.4%. As hepatitis C virus infection may today be successfully treated and as the infection may be clinically silent and thus unknown to the patient, it is important to screen all patients with PCT for hepatitis C virus infection.<sup>6</sup>

HCV association with extrahepatic manifestations can occur in one-third of patients with chronic infection and is generally seen in the late stages of the disease. Cryoglobulinemia, polyarteritis nodosa, leukocytoclastic vasculitis, urticaria, and PCT are the classic skin manifestations of chronic HCV.<sup>7</sup>

PCT is often overlooked because of its rarity, overlapping clinical signs, and lack of awareness.

Typical skin lesions seen in chronic liver disease and HIV are due to iron overload. Skin parts that are exposed to the sun, such as the hands and face, are most commonly affected and these patients usually have extreme photosensitivity. Easily bruised and blistered skin is common. Liver involvement can present with iron overload in the liver (hepatic siderosis), fat overload in the liver (steatosis), and liver inflammation (portal triaditis and periportal fibrosis). The diagnosis of PCT depends on the definition of characteristic symptoms, a detailed history, clinical evaluation, and some special tests (blood test, urine test, stool test, and skin biopsy).

In Case 1 porphyrins present in urine were detected by placing samples under UV light. Urine acquired a distinctive fluorescent pink color, due to a chemical reaction called oxidation, as porphyrins were present.

Patients with PCT may have urine that appears pink, red, or brown, especially after exposure of the urine to air and light because of marked excretions of porphyrins in the urine. Because the free porphyrins do not contain iron, urine tests for heme, hemoglobin, or myoglobin are all negative. Thus, despite the pink-red color of urine, routine urinalysis and blood counts are normal in most patients.<sup>3</sup>

In our cases apart from clinical and biochemical findings, skin biopsy showed subepidermal bullae with festooning and caterpillar bodies in the epidermis forming the roof of the blister, which helped in excluding other dermatological entities.

The specificity of caterpillar bodies is as high as 98% for the diagnosis of PCT and is defined as segmented eosinophilic bodies within the blister roof, joined linearly and parallel to the surface of the blister roof. Clusters of CB-like segments are also relatively specific for the diagnosis of PCT (specificity, 77%) but are also seen in a variety of subepidermal vesiculobullous disorders.<sup>7</sup>

#### 4. Conclusion

Porphyria cutanea tarda, a rare entity must be considered in a differential diagnosis of skin involvement of patients with typical liver disease to decrease morbidity, and health costs and ensure early treatment.<sup>8</sup> The correct definition of skin lesions in the presence of liver damage facilitates the diagnosis.

Dermal changes associated with underlying disease states may aid in making a diagnosis in the present days where the clinician is satisfied in identifying these clinical signs and being supported by laboratory investigations.

#### 5. Source of Funding

None.


#### 6. Conflict of Interest

None.

#### References

1. Franzon VA, Mikilita ES, Camelo FH, Camargo R. Porphyria cutanea tarda in a HIV positive patient. *An Bras Dermatol.* 2016;91(4):520–3.
2. Anderson KE, Sassa S, Bishop DF, Desnick RJ. Disorders of Heme Biosynthesis: X-Linked Sideroblastic Anemia and the Porphyrins. In: Scriver C, Beaudet A, Sly W, Valle D, editors. *The Metabolic and Molecular Bases of Inherited Disease.* vol. 2. New York: McGraw-Hill; 2001. p. 2991–3062.
3. Caballes FR, Sendi H, Bonkovsky HL. Hepatitis C, porphyria Cutanea tarda and liver iron: An update. *Liver Int.* 2012;32(6):880–93.
4. Mansourati FF, Stone VE, Mayer KH. Porphyria Cutanea Tarda and HIV/AIDS: A review of pathogenesis, clinical manifestations, and management. *Int J STD AIDS.* 1999;10(1):51–6.
5. Sharma YK, Virmani NC, Dash KN, Deo KS, Mave V, Gupta A, et al. A 23-year-old man presenting with fluid-filled skin lesions, patchy pigmentation, and skin breakage after trivial trauma. *Clin Infect Dis.* 2013;56(6):851–2.


6. Linde Y, Harper P, Floderus Y, Ros AM. The prevalence of hepatitis C in patients with porphyria cutanea tarda in. *Acta Derm Venereol.* 2005;85(2):164–6.
7. Fung MA, Murphy MJ, Hoss DM, Berke A, Grant-Kels JM. The sensitivity and specificity of “caterpillar bodies” in the differential diagnosis of subepidermal blistering disorders. *Am J Dermatopathol.* 2003;25(4):287–90.
8. Atmaca HU, Akbas F. Porphyria cutanea tarda: a case report. *J Med Case Rep.* 2019;13(1):17. doi:10.1186/s13256-018-1956-9.

**Swapnika Goud G**, Post Graduate  <https://orcid.org/0009-0003-1923-654X>

**Monish Ram S D**, Post Graduate  <https://orcid.org/0009-0008-6195-9836>

**Cite this article:** Chatura KR, Swapnika Goud G, Monish Ram S D. Dermatopathological diagnosis of porphyria cutanea tarda - Two case reports. *IP Arch Cytol Histopathology Res* 2024;9(1):45-48.

### Author biography

**Chatura KR**, Professor (Rtd.)  <https://orcid.org/0000-0001-8070-8348>