

Content available at: <https://www.ipinnovative.com/open-access-journals>

IP Archives of Cytology and Histopathology Research

Journal homepage: <https://www.achr.co.in/>

Original Research Article

Tumor-infiltrating lymphocytes: As a prognostic parameter in oral squamous cell carcinoma

Sradha Kunhikoloth^{1*}, Seema Bijjaragi¹, Anusha Somanath¹, Vineet Prakash Sah¹¹Dept. of Pathology, J.J.M Medical College, Davangere, Karnataka, India

ARTICLE INFO

Article history:

Received 27-04-2024

Accepted 14-06-2024

Available online 16-07-2024

Keywords:

Tumor-infiltrating lymphocytes

Oral squamous cell carcinoma

ABSTRACT

Background : Oral cavity cancer ranks among the prevalent malignancies globally, constituting roughly 30% of all cancer cases in the nation. The assessment of Tumor-infiltrating lymphocytes (TILs) has garnered significant international interest as a prospective prognostic biomarker for cancer, offering valuable insights for clinical decision-making. TILs are evaluated based on the ratio of lymphocytes infiltrating the stromal area.

Materials and Methods: A two-year retrospective study was conducted, analysing 30 cases of Oral Squamous Cell Carcinoma (OSCC) to examine routine clinicopathological factors alongside Tumor-infiltrating lymphocytes (TILs) in Hematoxylin and Eosin (H&E) stained sections. TILs were categorized into low, moderate, and high grades.

Results : In the study, 30 cases of OSCC underwent analysis, focusing on histopathological parameters and TILs. Patient ages ranged from 25 to 70 years, and a male-to-female ratio of 2:1. Among the cases, 20 (66.7%) were well-differentiated, 9 (30%) were moderately differentiated, and only 1 (3.3%) was poorly differentiated. High TILs were found in 16 cases (53.3%), moderate TILs in 12 cases (40.0%), and low TILs in 2 cases (6.7%). Importantly, a significant correlation was observed between TILs and histological grade (p-value = 0.001), as well as between TILs and pT stage (p-value = 0.001).

Conclusion: In summary, tumors with a high degree of differentiation exhibited elevated TILs, while those with poor differentiation displayed lower TIL levels. Given their accessibility and predictive value, these TIL assessments could serve as valuable prognostic indicators for guiding treatment strategies.

This is an Open Access (OA) journal, and articles are distributed under the terms of the [Creative Commons Attribution-NonCommercial-ShareAlike 4.0 License](https://creativecommons.org/licenses/by-nc-sa/4.0/), which allows others to remix, tweak, and build upon the work non-commercially, as long as appropriate credit is given and the new creations are licensed under the identical terms.

For reprints contact: reprint@ipinnovative.com

1. Introduction

Globally, oral cancer ranks as the sixth most prevalent type of cancer, with India bearing a significant portion of this burden, accounting for nearly one-third of all cases and ranking as the second country with the highest number of oral cancer cases. Within India, oral cancer stands as the most frequently diagnosed cancer among males and the third most common among females.¹

Oral Squamous Cell Carcinoma (OSCC) presents numerous histopathologic prognostic parameters, encompassing tumor grade/histologic grade, worst Pattern of Invasion (WPOI), lymph-nodal Involvement (LNI), depth of Invasion (DOI), perineural Invasion (PNI), lymphovascular Invasion (LVI), lymphocytic host response (LHR), and mitotic Activity/Index (MI).²

The quest for dependable and straightforward immunological biomarkers is crucial for refining treatment approaches. The immune response holds significant sway over the survival rates of cancer patients. Recent advancements in immuno-oncology and cancer

* Corresponding author.

E-mail address: sradhakunhikoloth@gmail.com (S. Kunhikoloth).

biomarkers underscore the importance of tumor-infiltrating lymphocytes (TILs) as a promising prognostic factor across different tumor types, including Oral Squamous Cell Carcinoma (OSCC).³

This study delves into recent discoveries concerning Tumor-infiltrating lymphocytes (TILs) in Oral Squamous Cell Carcinoma (OSCC) and their potential as a robust prognostic biomarker for guiding clinical decisions. The evaluation of TILs involves assessing the ratio of lymphocytes infiltrating the stromal area, offering valuable insights into disease prognosis and treatment strategies.⁴⁻⁹

2. Objectives

The objective is to correlate the possible association between Tumor-infiltrating lymphocytes (TILs) and clinicopathological factors of Oral Squamous Cell Carcinoma (OSCC).

3. Materials and Methods

A two-year retrospective study was conducted on 30 cases of Oral Squamous Cell Carcinoma (OSCC) to analyse routine clinicopathological factors alongside Tumor-infiltrating lymphocytes (TILs) in Hematoxylin and Eosin (H&E) stained sections. The study period spanned from January 2020 to February 2022. TILs were categorized into three grades: low, moderate, and high.

3.1. Inclusion criteria

1. Patients diagnosed pathologically with squamous cell carcinoma.
2. Underwent primary resection and concomitant neck dissection.
3. Received primary treatment via surgery without prior therapy.
4. Availability of complete clinicopathological data and tissue specimens.

3.2. Exclusion criteria

1. History of preoperative chemotherapy or radiotherapy.

3.2.1. Approach

1. Tumor Area Determination:
 - (a) Scanned slides at low magnification to delineate tumor boundaries.
 - (b) After outlining, necrotic and degenerated tissue within the tumor area was excluded.
2. Assessment of Tumor-Infiltrating Lymphocytes (TILs) :
 - (a) Focused on quantifying mononuclear cells while excluding neutrophils in necrotic regions, dendritic cells, and macrophages.

- (b) Evaluated the percentage of TILs within the stromal area.

3. Established thresholds for TIL levels:

- (a) Low level: 0% to $\leq 30\%$
- (b) Moderate level: 31% to $\leq 70\%$
- (c) High level: 71% to $\leq 99\%$

3.3. Statistical analysis

SPSS (Statistical Package for Social Sciences) version 20. [IBM SPSS statistics (IBM Corp. Armonk, NY, USA released 2011)] was used to perform the statistical analysis. Data were entered in the Excel spreadsheet. Descriptive statistics of the explanatory and outcome variables were calculated by mean, and standard deviation for quantitative variables, frequency, and proportions for qualitative variables. Yate's chi-squared test was applied to test the statistical association between qualitative variables.

4. Results

The study encompassed an examination of 30 cases of OSCC, evaluating both histopathological parameters and TILs. The age spectrum ranged from 25 to 70 years, with a mean of 51.40 ± 10.27 years (Table 1). The male-to-female ratio was 2:1. Predominantly, OSCC manifested in the buccal mucosa (56.7%), followed by the tongue (20.0%), lip (6.6%), and lateral border of the tongue (6.6%) (Table 2). Among the 30 cases, 20 (66.7%) showed well differentiation, 9 (30%) moderate differentiation, and only 1 (3.3%) poor differentiation (Figure 5). Lymph node metastasis was evident in 5 cases (16.7%), while lymphovascular invasion and perineural invasion were observed in 2 (6.7%) and 3 cases (10.0%) respectively. TILs were notably present in 16 cases (53.3%) at high levels (Figures 3 and 4), 12 cases (40.0%) at moderate levels (Fig.2), and 2 cases (6.7%) at low levels (Figure 1), with a significant correlation observed with histological grade (p-value = 0.001) (Table 3). Regarding tumor staging, 50% of cases were classified as pT1, 20% as pT2, 20% as pT3, and 10% as pT4, with TILs demonstrating a significant correlation with pT stage (p-value = 0.001) (Figure 6) (Table 4).

5. Discussion

The importance of tumor-infiltrating lymphocytes (TILs) in predicting cancer outcomes has been underscored in numerous studies. A high abundance of TILs typically signifies a robust anti-tumor immune response, potentially leading to more favorable survival outcomes. In recent years, the recognition of TILs as a dependable prognostic marker has grown significantly across various tumor types, including breast, colorectal, gastric, and lung cancers.³

Table 1: Distribution of oral squamous cell carcinoma based on age

Age group	Frequency	Percent
< 40	1	3.3
40-49	13	43.3
50-59	7	23.3
60-69	8	26.8
>70	1	3.3
Total	30	100.0
Mean age – 51.40 ± 10.27 years		

Table 2: Distribution of oral squamous cell carcinoma based on anatomical site

Site	Frequency	Percent
Buccal mucosa	17	56.7
Buccal mucosa + lip	1	3.3
The lateral border of tongue	2	6.7
The lateral border of tongue and buccal mucosa	1	3.3
Lip	2	6.7
Lip and buccal mucosa	1	3.3
Tongue	6	20.0
Total	30	100.0

Table 3: Correlation of TILs with histopathological grade

Grade	Lymphocytic response			Total
	High	Moderate	Low	
Mod-diff	1 3.3%	8 26.7%	0 0.0%	9 30.0%
Poorly-diff	0 0.0%	0 0.0%	1 3.3%	1 3.3%
Well diff	15 50.0%	4 13.3%	1 3.3%	20 66.7%
Total	16 53.3%	12 40.0%	2 6.7%	30 100.0%
p-value - 0.001				

Table 4: Correlation of TILs with pT stage

T staging	Lymphocytic response			Total
	High	Intermediate	Low	
T1	11 36.7%	4 13.3%	0 0.0%	15 50.0%
T2	5 16.7%	1 3.3%	0 0.0%	6 20.0%
T3	0 0.0%	6 20.0%	0 0.0%	6 20.0%
T4	0 0.0%	1 3.3%	2 6.7%	3 10.0%
Total	16 53.3%	12 40.0%	2 6.7%	30 100.0%
p-value - 0.001				

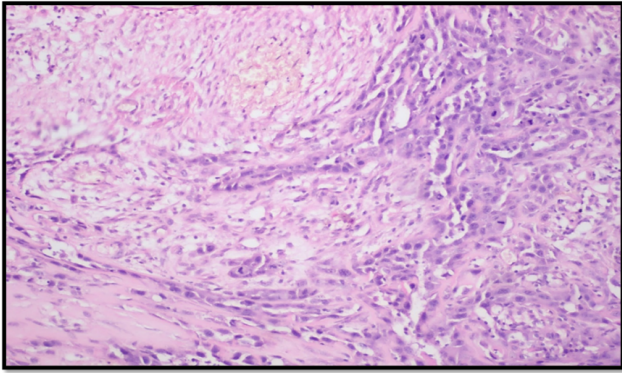


Figure 1: Low level TILs: 0% to ≤30% (H&E, X20)

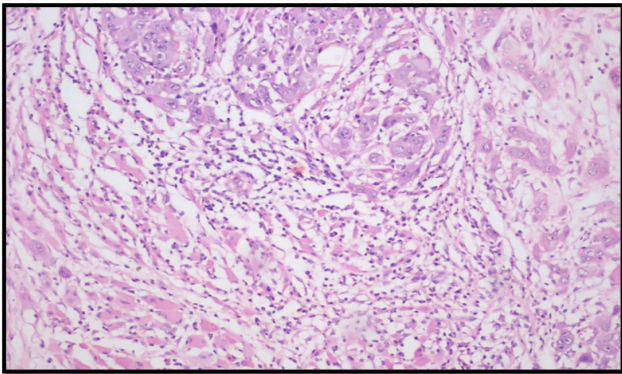


Figure 2: Moderate level TILs: 31% to ≤70% (H&E, X20)

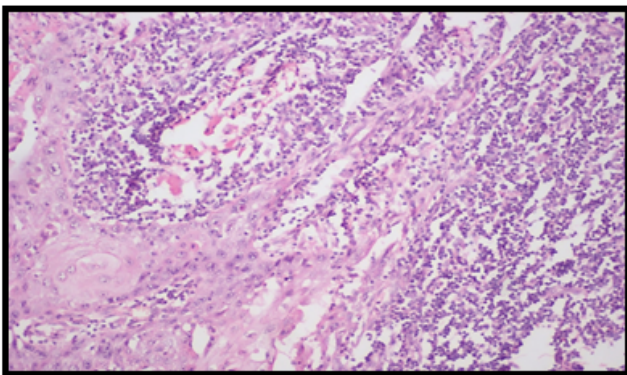


Figure 3: High level TILs: 71% to ≤99% (H&E, X20)

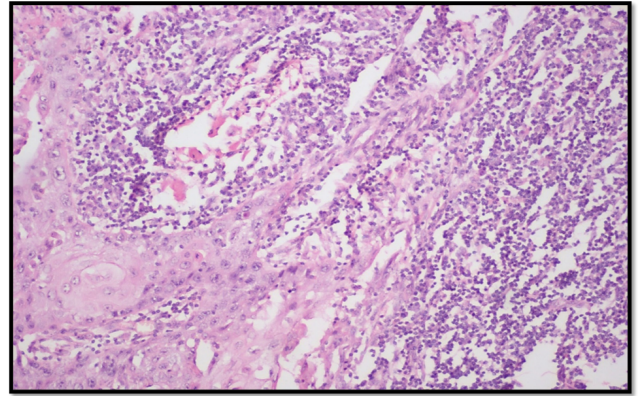


Figure 4: High level TILs: 70% to ≤99% (H&E, X40)

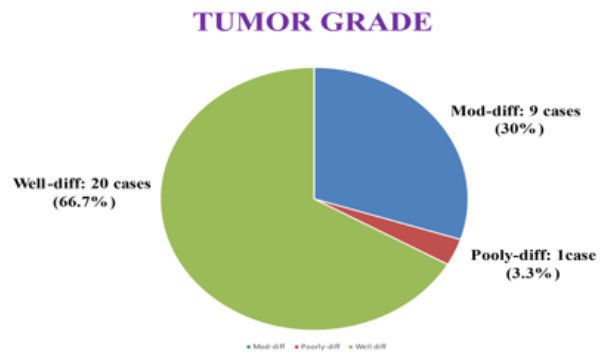


Figure 5: Distribution of oral squamous cell carcinoma based on histopathological grade

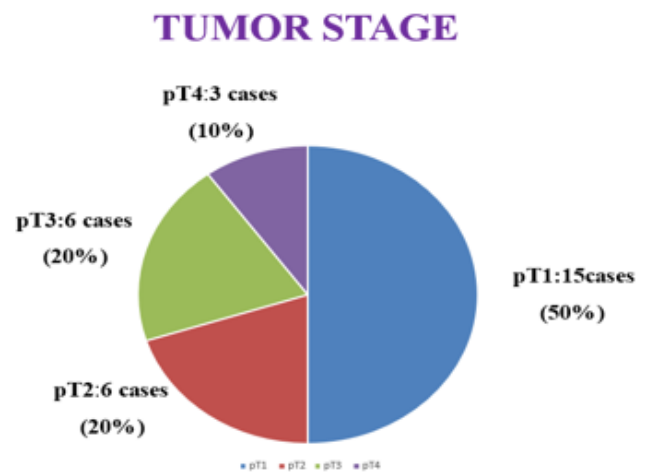


Figure 6: Distribution of oral squamous cell carcinoma based on pT stage

In the present retrospective study involving 30 cases of OSCC, the mean age at presentation was 51.40 ± 10.27 years, ranging from 25 to 70 years. A study conducted by B Chaitra et al. examined 69 cases of OSCC, revealing an age range of 25 to 87 years with a mean age of 49.9 years and a male-to-female ratio of 4.3:1. The primary site of OSCC in their study was predominantly the buccal mucosa (49%), followed by the tongue (43%), with the lateral border of the tongue being the most common site. Similarly, in our study,

the buccal mucosa was the most frequent site. Among the 69 cases reviewed by B Chaitra et al., 57 cases (82.6%) were grade 1 tumors, 9 cases (13%) were grade 2, and only 3 cases (4.3%) were grade 3 tumors. Furthermore, moderate TILs were observed in 46 cases (66.7%), followed by mild TILs in 13 cases (18.8%) and severe TILs in 10 cases (14.5%). Notably, TILs exhibited a significant correlation with various factors including WPOI, PNI, pT stage, and outcome.²

In a study conducted by Hitomi Suzuki et al., which involved 153 patients with an average age of 65.7 ± 11 years (124 males and 29 females), a cut-off value for TILs was set at 50%. The overall survival (OS) rates were 69.8% and 40.2% ($P = 0.01$) for patients with high and low TIL levels, respectively. Similarly, progression-free survival (PFS) rates were 58.4% and 31.6% ($P = 0.003$) in the high and low TIL groups, respectively.¹

In a cohort study conducted by Alhadi Almangush et al., which included 140 (76.9%) men and 42 (23.1%) women, the median follow-up time was 4.48 years (range 3.51–5.00 years). They found that 49 (26.9%) tumors exhibited low infiltration of TILs (<20%), while 133 (73.1%) tumors showed high infiltration ($\geq 20\%$) of TILs. Their analysis revealed a significant association between T-classification and TILs, indicating that smaller tumors were associated with a higher infiltration of TILs ($P = 0.01$).³ Similarly, in our study, we also observed a significant correlation between TILs and pT stage.^{10–15}

In a retrospective cohort study by Qiaoshi Xu et al., the records and pathological sections of 202 patients with HNSCC who underwent surgical treatment were reviewed. They determined that a cutoff value of 70% could be utilized as a threshold for assessing TILs, with a TIL level exceeding 70% being linked to a more favorable prognosis. Specifically, they found that patients with TIL levels higher than 70% exhibited a disease-free survival rate (DFS rate) of 51.9% ($P = .018$) and a disease-specific survival rate (DSS rate) of 59.3% ($P = .049$).^{16–25}

The findings of the present retrospective study underscored a significant association between higher TILs and improved histological grade and T stage in Oral SCC. Furthermore, multivariate analyses revealed that TILs serve as robust independent prognostic factors. Therefore, investigating TILs in Oral SCC holds considerable promise. TILs could potentially serve as sensitive markers for chemoradiotherapy response. Notably, the assessment of TILs was deemed feasible with just HE staining, emphasizing the importance of standardizing and establishing a simple evaluation method. Moving forward, multicentre, prospective clinical trials will be essential to elucidate the true utility of TILs in guiding treatment decisions and improving patient outcomes.

6. Conclusion

The observation that well-differentiated tumors exhibit high TILs while poorly differentiated tumors show low TILs

underscores the potential prognostic significance of TILs in Oral SCC. Furthermore, the significant correlation between TILs and pT stage suggests their relevance in tumor staging and prognosis. Given their ease of assessment and their prognostic value, TILs could serve as valuable prognostic tools for guiding treatment planning. Therefore, routine evaluation of TILs in both resection and preoperative biopsy specimens should be considered standard practice, facilitating more informed management decisions and potentially improving patient outcomes.

7. Conflict of Interest

The authors declare no conflicts of interest.

8. Source of Funding

No financial support of interest.

References

1. Suzuki H, Kawasaki Y, Miura M, Hatakeyama H, Shina K, Suzuki S, et al. Tumor Infiltrating Lymphocytes are Prognostic Factors and Can Be Markers of Sensitivity to Chemoradiotherapy in Head and Neck Squamous Cell Carcinoma. *Asian Pac J Cancer Prev.* 2022;23(4):1271–8.
2. Chaitra B, Burela M, Kasula L, Inuganti RV, Vaddatti T. Correlative Study of Tumor Budding, Mode of Invasion and Lymphocytic Host Response with Known Clinicopathological Prognostic Factors in Oral Squamous Cell Carcinoma. *J Oral Maxillofac Pathol.* 2020;24(3):484–91.
3. Almangush A, Jouhi L, Atula T, Haglund C, Mäkitie A, Hagström J, et al. Tumor-infiltrating lymphocytes in oropharyngeal cancer: a validation study according to the criteria of the International Immuno-Oncology Biomarker Working Group. *Br J Cancer.* 2022;126(11):1589–94.
4. Almangush A, De Keukeleire S, Rottey S, Ferdinande L, Vermassen T, Leivo I, et al. Tumor-Infiltrating Lymphocytes in Head and Neck Cancer: Ready for Prime Time? *Cancers (Basel).* 2022;14:1558. doi:10.3390/cancers14061558.
5. Moreira G, Fulgêncio LB, De Mendonça E, Leles CR, Batista, Batista AC, et al. T regulatory cell markers in oral squamous cell carcinoma: Relationship with survival and tumor aggressiveness. *Oncol Lett.* 2010;1(1):127–32.
6. Hori Y, Kubota A, Yokose T, Furukawa M, Matsushita T, Katsumata N, et al. Prognostic role of tumor-infiltrating lymphocytes and tumor budding in early oral tongue carcinoma. *Laryngoscope.* 2021;131(11):2512–8.
7. Silveira ED, Miguel MCC, Lima KC, Freitas RA, de Moraes MA, Queiroz LMG, et al. Analysis of local immunity in squamous cell carcinoma of the tongue and lower lip. *Exp Mol Pathol.* 2010;88(1):171–5.
8. Wolf GT, Liu S, Bellile E, Sartor M, Rozek L, Thomas D, et al. Tumor infiltrating lymphocytes after neoadjuvant IRX-2 immunotherapy in oral squamous cell carcinoma: Interim findings from the INSPIRE trial. *Oral Oncol.* 2020;111:104928. doi:10.1016/j.oraloncology.2020.104928.
9. Chatzistamou I, Rodriguez J, Jouffroy T, Girod A, Point D, Sklavounou A, et al. Prognostic significance of tumor shape and stromal chronic inflammatory infiltration in squamous cell carcinomas of the oral tongue. *J Oral Pathol Med.* 2010;39(9):667–71.
10. Thomas DW, Matthews JB, Patel V, Game SM, Prime SS. Inflammatory cell infiltrate associated with primary and transplanted

- tumours in an inbred model of oral carcinogenesis. *J Oral Pathol Med.* 1995;24(1):23–31.
11. Jadhav K, Gupta N. Clinicopathological prognostic implicators of oral squamous cell carcinoma: Need to understand and revise. *Am J Med Sci.* 2013;5(12):671–9.
 12. Parekh D, Kukreja P, Mallick I, Roy P. Worst pattern of invasion - type 4 (WPOI-4) and Lymphocyte host response should be mandatory reporting criteria for oral cavity squamous cell carcinoma: A re-look at the American Joint Committee of Cancer (AJCC) minimum dataset. *Indian J Pathol Microbiol.* 2020;63(4):527–33.
 13. Abbas SA, Saeed J, Tariq MU, Baksh AR, Hashmi S. Clinicopathological prognostic factors of oral squamous cell carcinoma: An experience of a tertiary care hospital. *J Pak Med Assoc.* 2018;68(7):1115–9.
 14. Majumdar B, Patil S, Sarode SC, Sarode GS, Rao RS. Clinicopathological prognosticators in oral squamous cell carcinoma. *Transl Res.* 2017;p. 1–14.
 15. Almangush A, Leivo I, Makitie AA. Overall assessment of tumor-infiltrating lymphocytes in head and neck squamous cell carcinoma: time to take notice. *Acta Otolaryngol.* 2020;140(3):246–8.
 16. Xu Q, Wang C, Yuan X, Feng Z, Han Z. Prognostic Value of Tumor-Infiltrating Lymphocytes in Head and Neck Squamous Cell Carcinoma. *Transl Oncol.* 2017;10(1):10–6.
 17. Hendry S, Salgado R, Gevaert T, Russell PA, John T, Thapa B, et al. Assessing tumor-infiltrating lymphocytes in solid tumors: a practical review for pathologists and proposal for a standardized method from the International Immuno-Oncology Biomarkers Working Group. *Adv Anat Pathol.* 2017;24(5):235–51.
 18. Swisher SK, Wu Y, Castaneda CA, Lyons GR, Yang F, Tapia C, et al. Interobserver agreement between pathologists assessing tumor-infiltrating lymphocytes (TILs) in breast cancer using the methodology proposed by the International TILs Working Group. *Ann Surg Oncol.* 2016;23(5):2242–8.
 19. Heikkinen I, Bello IO, Wahab A, Hagstrom J, Haglund C, Coletta RD, et al. Assessment of tumor-infiltrating lymphocytes predicts the behavior of early-stage oral tongue cancer. *Am J Surg Pathol.* 2019;43(10):1392–6.
 20. Almangush A, Ruuskanen M, Hagstrom J, Hirvikoski P, Tommola S, Kosma VM, et al. Tumor-infiltrating lymphocytes associate with outcome in nonendemic nasopharyngeal carcinoma: a multicenter study. *Hum Pathol.* 2018;81:211–9. doi:10.1016/j.humpath.2018.07.009.
 21. Shaban M, Khurram SA, Fraz MM, Alsubaie N, Masood I, Mushtaq S, et al. A novel digital score for abundance of tumor-infiltrating lymphocytes predicts disease-free survival in oral squamous cell carcinoma. *Sci Rep.* 2019;9(1):13341. doi:10.1038/s41598-019-49710-z.
 22. Xu B, Salama AM, Valero C, Yuan A, Khimraj A, Saliba M, et al. Histologic evaluation of host immune microenvironment and its prognostic significance in oral tongue squamous cell carcinoma: a comparative study on lymphocytic host response (LHR) and tumor-infiltrating lymphocytes (TILs). *Pathol Res Pract.* 2021;228:153473. doi:10.1016/j.prp.2021.153473.
 23. Wang YQ, Chen YP, Zhang Y, Jiang W, Liu N, Yun JP, et al. Prognostic significance of tumor-infiltrating lymphocytes in non-disseminated nasopharyngeal carcinoma: A large-scale cohort study. *Int J Cancer.* 2018;142(12):2558–66. doi:10.1002/ijc.31279.
 24. Wang J, Tian S, Sun J, Zhang J, Lin L, Hu C, et al. The presence of tumor-infiltrating lymphocytes (TILs) and the ratios between different subsets serve as prognostic factors in advanced hypopharyngeal squamous cell carcinoma. *BMC Cancer.* 2020;20(1):731. doi:10.1186/s12885-020-07234-0.
 25. Peled M, Onn A, Herbst RS. Tumor-infiltrating lymphocytes-location for prognostic evaluation. *Clin Cancer Res.* 2019;25(5):1449–51.

Author biography

Sradha Kunhikoloth, Post Graduate  <https://orcid.org/0009-0006-0369-4556>

Seema Bijjaragi, Professor  <https://orcid.org/0000-0002-9911-1039>

Anusha Somanath, Post Graduate  <https://orcid.org/0009-0002-9518-9987>

Vineet Prakash Sah, Post Graduate  <https://orcid.org/0009-0005-4562-4241>

Cite this article: Kunhikoloth S, Bijjaragi S, Somanath A, Sah VP. Tumor-infiltrating lymphocytes: As a prognostic parameter in oral squamous cell carcinoma. *IP Arch Cytol Histopathology Res* 2024;9(2):81-86.