

Content available at: <https://www.ipinnovative.com/open-access-journals>

IP Archives of Cytology and Histopathology Research

Journal homepage: <https://www.achr.co.in/>

Case Report

Acinic cell carcinoma of left parotid gland: A case report

Deep Pravinbhai Chauhan ¹, Kunjan Pramodbhai Patel ¹,
Darshan Rajeshbhai Parmar ², Anjali Goyal ^{2*}

¹SVP Hospital, Ahmedabad, Gujarat, India

²Dept. of Pathology, Smt. NHL Municipal Medical College, Ahmedabad, Gujarat, India



ARTICLE INFO

Article history:

Received 15-07-2024

Accepted 31-07-2024

Available online 08-10-2024

Keywords:

Acinic cell carcinoma

Parotid gland

Superficial Parotidectomy

ABSTRACT

Acinic cell carcinoma (ACC) is an uncommon and gradually developing tumour primarily found in the major salivary glands, most frequently originating in the parotid gland and less commonly in the submandibular and sublingual glands. ACC represents 3 to 4% of parotid gland tumours, 2 to 6% of all salivary gland tumours, and 10 to 17% of all malignant tumours in the salivary glands.

This is an Open Access (OA) journal, and articles are distributed under the terms of the [Creative Commons Attribution-NonCommercial-ShareAlike 4.0 License](https://creativecommons.org/licenses/by-nc-sa/4.0/), which allows others to remix, tweak, and build upon the work non-commercially, as long as appropriate credit is given and the new creations are licensed under the identical terms.

For reprints contact: reprint@ipinnovative.com

1. Introduction

Acinic cell carcinoma (ACC) is an uncommon and slow-growing tumor that primarily affects the major salivary glands, most often the parotid gland, and less frequently the submandibular and sublingual glands. ACC constitutes 3 to 4% of parotid tumors, 2 to 6% of all salivary gland tumors, and 10 to 17% of malignant salivary gland tumors. Malignant tumors from minor salivary glands make up about 2 to 3% of all upper aerodigestive tract malignancies. Among minor salivary glands, the palate is the most commonly affected site, while the buccal mucosa, lips, tongue, retromolar trigone, and paranasal sinuses are rarely involved. ACC in minor salivary glands typically presents as a slow-growing mass beneath a normal mucosal layer. These tumors are generally solitary, soft, and may appear round or lobulated with a grossly encapsulated appearance. Tumors in minor salivary glands are thought to be less aggressive than those in the parotid gland. Origin of ACC from minor salivary glands is rare, and there are no reported cases of it arising at the junction of the anterior two-thirds

and posterior one-third of the tongue.¹

2. Case Report

A 40-year-old male patient presented with a swelling in the left cheek region that had persisted for 3 years. Initially, the patient had no symptoms, but he developed the swelling for which he underwent surgical intervention (documentation not available). Post-surgery, the swelling reappeared and gradually increased to its current size. The patient reported no fever, pain, nausea, vomiting, discharge, pain from the swelling, or dry mouth.

Fine-needle aspiration cytology (FNAC) indicated a "salivary gland neoplasm of uncertain malignant potential with a higher likelihood of pleomorphic adenoma," classified under CATEGORY IV B of the MILAN System for reporting salivary gland cytopathology. Examination of the rest of the neck was unremarkable. A CT scan revealed a well-defined, heterogeneously enhancing isodense to hyperdense lesion measuring approximately 47 x 22 x 41 mm, originating from the residual left parotid gland, suggestive of a benign salivary gland lesion.

* Corresponding author.

E-mail address: anjaliideepak1212@gmail.com (A. Goyal).

2.1. Intervention

Superficial parotidectomy was performed and resected tissue was sent for histopathological examination.

2.2. Gross

Specimen weighing 30 grams total measuring 6.1 x 4.0 x 2.5 cm. On cut section ill-defined whitish soft to firm mass was identified measuring 3.2 x 3 x 2 cm.(Figures 1 and 2)

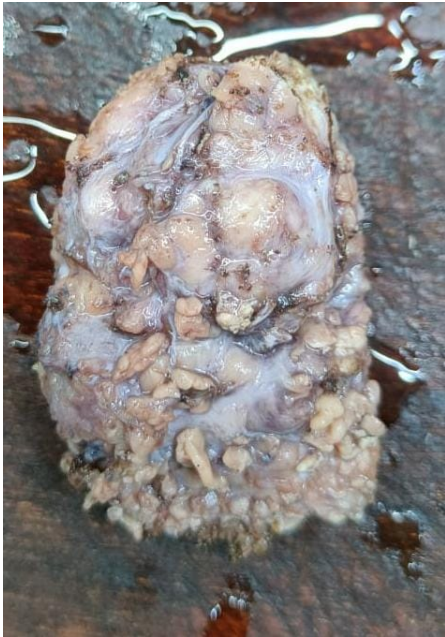

Figure 1: Gross image of biopsy specimen received in formalin

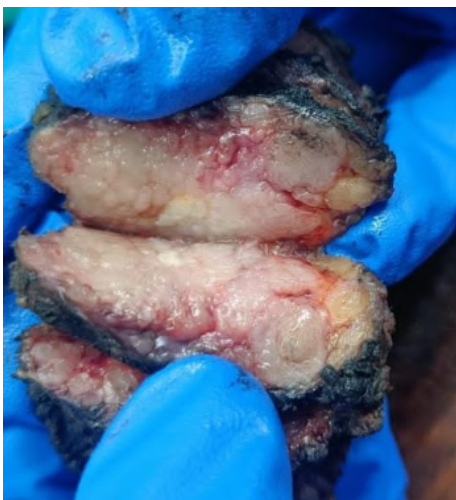

Figure 2: Cut section showing whitish soft to firm mass

2.3. Microscopic examination

Sections reveal salivary gland tissue showing infiltration by solid sheets of tumour tissue showing granular and vacuolated basophilic cytoplasm and eccentric nucleus and conspicuous nucleoli. Tumour tissue is surrounded by connective tissue showing sclerosis and scanty lymphocytic infiltration. There is also presence of tumour tissue infiltration into the surrounding adipose tissue and capsule and it is exceeding up to resected margin. Scattered hemosiderin laden macrophages are seen. No evidence of perineural infiltration is seen.(Figures 3 and 4)

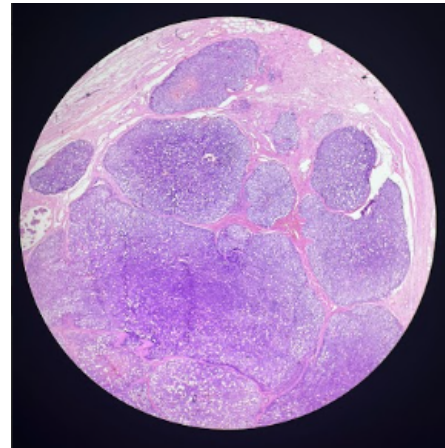


Figure 3: Tumor section revealing salivary gland tissue showing infiltration by solid sheets of tumor tissue surrounded by connective tissue showing sclerosis and scanty lymphocytic infiltration

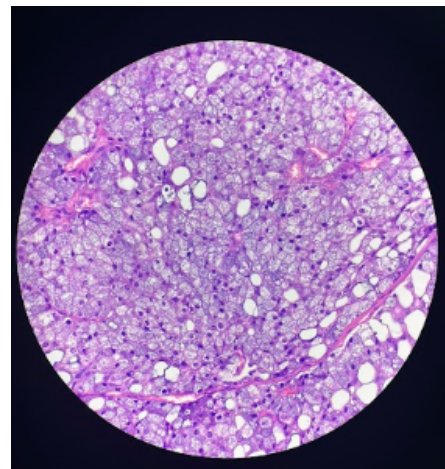


Figure 4: Tumor tissue showing granular and vacuolated basophilic cytoplasm and eccentric nucleus and conspicuous nucleoli

2.4. Special stain and immunohistochemistry report

Special stain: PAS-D – Positive.(Figure 5)

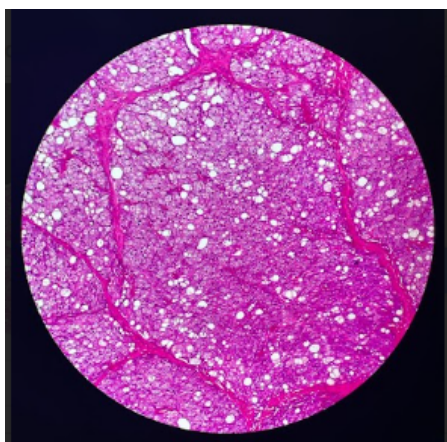


Figure 5: Special stain showing PAS-D positivity

3. Discussion

Acinic cell tumor of the salivary gland was initially described by Nasse in 1892 as a benign tumor.² However, in the 1950s, it was reclassified as malignant, thought to originate from reserve cells of the salivary gland ducts, with cases of local recurrence, as well as pulmonary and bone metastases being documented.² These tumors are most frequently observed in the fourth and fifth decades of life, predominantly in females, although cases in other age groups have also been reported. These tumors can manifest as ulcerated mucosal lesions of varying sizes and may exhibit solid, microcystic, follicular, and papillary-cystic patterns. The biological behavior of the tumor is not affected by its histopathological appearance, size, degree of differentiation, or infiltrative margins.³ Batsakis et al. found that acinic cell carcinomas (ACCs) originate from the intercalated ducts of the salivary gland's ductal and tubular system.⁴ Metastasis to the cervical lymph nodes and hematogenous spread to the lungs or bones occur in 7 to 29% of cases.^{5–7} Local tumor excision performed transorally, either by conventional methods or by LASER, is the preferred treatment for early lesions.^{8,9} Hiratsuka et al. reviewed 84 cases of intraoral ACC of the minor salivary glands, finding a higher incidence in superior regions such as the palate, and a lower incidence in inferior regions such as the retromolar trigone and the floor of the mouth.¹⁰ They did subsite stratification analysis and reported lesion in the palate in 28 cases, buccal mucosa in 20, lip in 17, tongue in eight, retromolar trigone in seven and floor of the mouth and gingival in four cases.¹⁰ Callender et al. found that adjuvant radiotherapy resulted in improved disease-free survival outcomes for high-grade tumors characterized by close or invaded margins, perineural invasion, and multiple-

positive lymph nodes.¹¹ Ferlito et al. documented three instances of adenoid cystic carcinoma (ACC) originating from minor salivary glands, specifically in the larynx, base of the tongue, and right tonsil. They characterized these tumors as having low-grade malignancy, highlighting their rarity and potential for recurrence post-surgery, sometimes leading to metastasis.¹² Tumor sizes ranged from 0.6 to 1.6 cm, and all cases underwent wide local excision. Out of the patients, 10 experienced recurrence or metastasis. The researchers concluded that it is generally a slow-growing tumor, sometimes occurring alongside other malignant salivary gland tumors either concurrently or at different times. Eneroth et al. discussed 10 cases of adenoid cystic carcinoma originating from the parotid gland, treated with a combination of surgery and radiotherapy.⁸ According to Batsakis et al., adenoid cystic carcinoma (ACC) demonstrates radiosensitivity, proving beneficial for treating locally advanced tumors, late-stage disease, and residual lesions. They observed varying overall survival outcomes between surgical intervention and aggressive radiotherapy for parotid tumors.^{4,13} They noted that adenoid cystic carcinoma (ACC) of the parotid gland can be managed through superficial or total parotidectomy while preserving the facial nerve. Tumors located in challenging areas such as the tongue base, floor of the mouth, or retromolar trigone may often be diagnosed at advanced stages due to their location.⁸ The management of such cases involves confirming the diagnosis through histopathology and assessing the patient's performance status, tumor size, location, and accessibility.

4. Conclusion

Adenoid cystic carcinoma (ACC) is a rare low-grade malignant tumor found infrequently in the minor salivary glands of the oral cavity. The overall prognosis following surgical removal hinges on the extent of the lesion and the effectiveness of the initial resection. Due to its malignant potential, careful long-term follow-up is recommended to monitor for recurrence or metastasis.

5. Source of Funding

None.

6. Conflict of Interest


None.


References


1. Van Den Akker H, Busemann-Sokole E, Becker AE. Acinic cell carcinoma of the sublingual gland. *Int J Oral Surg*. 1981;10(5):363–6.
2. Çelikyurt C, Yavuzer D. Acinic cell carcinoma in parotid gland: A case report. *Türk ORL Arflivi*. 1999;37:75–8.
3. Napier SS, Herron BT, Herron BM. Acinic cell carcinoma in Northern Ireland: A 10-year review. *Br J Oral Max Surg*. 1995;33(3):145–8.


4. Batsakis JG, Wozniak KJ, Regezi JA. Acinous cell carcinoma: A histogenetic hypothesis. *J Oral Surg.* 1977;35(11):904–6.
5. Kenner JR, Benson PM, Sinha C, Willard CC, Harrington AC, Sau P, et al. Acinic cell carcinoma presenting as an upper lip mass. *Dermatol Surg.* 1998;24(2):283–5.
6. Zbaeren P, Lehmann W, Widgren S. Acinic cell carcinoma of minor salivary gland origin. *J Laryngol Otol.* 1991;105(9):782–85.
7. Triantafillidou E, Karanezi E, Tsamis I. Acinic cell adenocarcinoma of a minor salivary gland. *J Oral Maxillofac Surg.* 1987;45(6):540–2.
8. Koyuncu M, Atmaca S, Kandemir B, Çakıl B. Acinic cell carcinoma in minor salivary glands of retromolar trigone. *OMÜ Tıp Dergisi Cilt.* 2008;25(2):72–4.
9. Hiratsuka H, Imamura M, Miyakawa A, Sunakawa H, Takahashi K, Yamamoto E. Acinic cell carcinoma of minosalivary gland origin. *Oral Surg Oral Med Oral Pathol.* 1987;63:704–8.
10. Callender DL, Frankenthaler RA, Luna MA, Lee SS, Goepfert H. Salivary gland neoplasms in children. *Arch Otolaryngol Head Neck Surg.* 1992;118(5):472–6.
11. Ferlito A. Acinic cell carcinoma of minor salivary glands. *Histopathology.* 1980;4(3):331–43.
12. Eneroth CM, Jakobsson PA, Blanck C. Acinic cell carcinoma of the parotid gland. *Cancer.* 1966;19(12):1761–72.
13. Spafford PD, Mintz DR, Hay J. Acinic cell carcinoma of the parotid gland: Review and management. *J Otolaryngol.* 1991;20(4):262–6.

Author biography

Deep Pravinbhai Chauhan, Resident  <https://orcid.org/0009-0001-3230-4127>

Kunjan Pramodbhai Patel, Consultant  <https://orcid.org/0009-0005-3708-8063>

Darshan Rajeshbhai Parmar, Resident  <https://orcid.org/0009-0005-9783-4195>

Anjali Goyal, Professor  <https://orcid.org/0000-0002-1945-0322>

Cite this article: Chauhan DP, Patel KP, Parmar DR, Goyal A. Acinic cell carcinoma of left parotid gland: A case report. *IP Arch Cytol Histopathology Res* 2024;9(3):163-166.