

Content available at: <https://www.ipinnovative.com/open-access-journals>

IP Archives of Cytology and Histopathology Research

Journal homepage: <https://www.achr.co.in/>

## Case Report

# Collagenising gastritis

Bhavana Grandhi<sup>1\*</sup>, K Durga<sup>1</sup>, P Maanasa Lakshmi<sup>1</sup>, R Madhuri<sup>1</sup>, P Divya Theja<sup>1</sup>

<sup>1</sup>Dept. of Pathology, Narayana Medical College, Nellore, Andhra Pradesh, India



### ARTICLE INFO

#### Article history:

Received 05-06-2024

Accepted 13-07-2024

Available online 08-10-2024

#### Keywords:

Collagenising gastritis

Gastroenterology

Epithelial collagen

### ABSTRACT

It is a rare condition defined histologically by superficial subepithelial collagen layer. Collagenous gastritis occurs in bimodal age distribution both paediatric and adults.

Sub epithelial collagen distribution favours the body or fundus in paediatric age group and antrum in adults. Now present a case of collagenising gastritis in 50 year male who presented with vomiting to medical gastroenterology department.

This is an Open Access (OA) journal, and articles are distributed under the terms of the [Creative Commons Attribution-NonCommercial-ShareAlike 4.0 License](https://creativecommons.org/licenses/by-nc-sa/4.0/), which allows others to remix, tweak, and build upon the work non-commercially, as long as appropriate credit is given and the new creations are licensed under the identical terms.

For reprints contact: [reprint@ipinnovative.com](mailto:reprint@ipinnovative.com)

## 1. Introduction

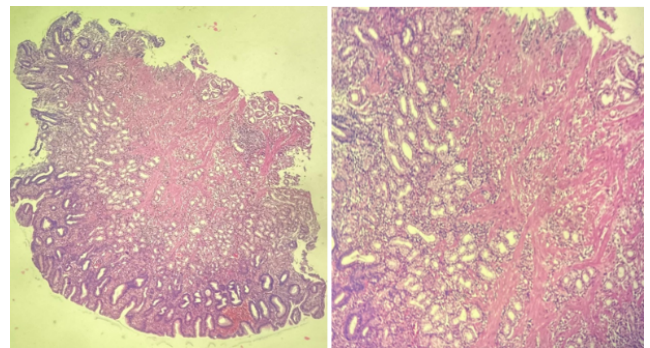
Collagenous gastritis is a rare and poorly understood condition characterized by the presence of a thickened subepithelial collagen layer in the gastric mucosa. This disorder shows a bimodal age distribution, affecting both pediatric patients and adults, but with different patterns of involvement. In children, the collagen deposition typically affects the gastric body or fundus, while in adults, it predominantly involves the antrum. Although the exact etiology remains unknown, patients often present with non-specific gastrointestinal symptoms. Here, we report a case of collagenous gastritis in a 50-year-old male who presented with recurrent vomiting, highlighting the challenges in diagnosis and management of this uncommon disease.

## 2. Case Report

A 50 year old male patient came to medical gastroenterology department with complaints of vomiting. There is significant history of alcohol intaske. Endoscopy was done and multiple spots were identified in the stomach. Multiple biopsies were taken and send to our department

for histopathological examination. We received multiple grey white mucosal bits which were processed routinely and examined.

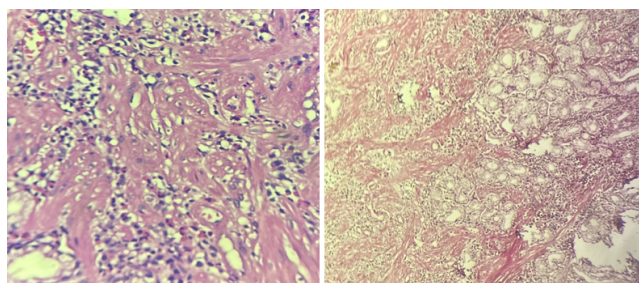
On microscopy mucosa was seen lined by columnar epithelium. Lamina propria showed extensive areas of collagenisation with fibrosis with entrapment of mucosal glands. Inflammatory cells predominantly lymphocytes, eosinophils were seen. Vangieson demonstrated collagen bands confirming the diagnosis of collagenising gastritis.



**Figure 1:** Scanner view; 10Xx100 showing collagen bands

\* Corresponding author.

E-mail address: [sashilaboratory@gmail.com](mailto:sashilaboratory@gmail.com) (B. Grandhi).



**Figure 2:** 40X100 showing glands within collagen Van Gieson stain positive for collagen

### 3. Discussion

Collagen gastritis is a very rare clinicopathological entity.<sup>1</sup>

Etiology of the disease was proposed to be due to primary vascular abnormality causing increased vascular permeability and collagen deposition.<sup>2</sup>

It covers under the broad category of collagenous gastroenteritis which includes collagenous gastritis and collagenous colitis. These are characterised by mucosal subepithelial collagen deposition along with mucosal inflammatory infiltrate.<sup>3–6</sup> Paediatric patients presenting with upper GI symptoms with abdominal pain and anaemia where adults present with autoimmune proctitis and coeliac disease.<sup>7,8</sup> Upper endoscopy is recommended diagnostic modality.

More cases are needed to be documented to establish a standard therapeutic strategy.

### 4. Conclusion

This is an uncommon entity with autoimmune etiology requiring further documentation.

### 5. Source of Funding

None.

### 6. Conflict of Interest

None.

### References

1. Rustagi T, Rai M, Scholes JV. Collagenous gastroduodenitis. *J Clin Gastroenterol.* 2011;45(9):794–9.
2. Hijaz NM, Septer SS, Degaetano J, Attard TM. Clinical outcome of pediatric collagenous gastritis: case series and review of literature. *World J Gastroenterol.* 2013;19(9):1478–84.
3. Nielson OH, Riis LB, Danese S, Bojesen RD, Soendergaard C. Proximal collagenous gastroenteritides: clinical management. A systematic review. *Ann Med.* 2014;46(5):311–7.
4. Gopal P, McKenna BJ. The collagenous gastroenteritides: similarities and differences. *Arch Pathol Lab Med.* 2010;134(10):1485–9.
5. Brain O, Rajaguru C, Warren B, Booth J, Travis S. Collagenous gastritis: reports and systematic review. *Eur J Gastroenterol Hepatol.* 2009;21(12):1419–24.
6. Freeman HJ. Complications of collagenous colitis. *World J Gastroenterol.* 2008;14(11):1643–5.
7. Lagorce-Pages C, Fabini B, Bouvier R, Scoazec JY, Durand L, Flejou JF, et al. Collagenous gastritis: a report of six cases. *Am J Surg Pathol.* 2001;25(9):1174–9.
8. Zhou H, Rossi G. Collagenous Gastritis: An Entity Distinct from Collagenous Colitis. *J Clin Pathol.* 2011;64(8):705–11.

### Author biography

**Bhavana Grandhi**, Professor

**K Durga**, Professor and HOD

**P Maanasa Lakshmi**, Assistant Professor

**R Madhuri**, Assistant Professor

**P Divya Theja**, Assistant Professor

**Cite this article:** Grandhi B, Durga K, Lakshmi PM, Madhuri R, Theja PD. Collagenising gastritis. *IP Arch Cytol Histopathology Res* 2024;9(3):167-168.