

Dens Invaginatus-Type 1-A rare case report

Sujata Byahatti^{1*}, Renuka Ammanagi²

¹Reader, ²Professor & HOD, Dept. of Oral Medicine & Radiology, M M's N.G. Halgekar Institute of Dental Sciences and Research Centre, Belgaum

***Corresponding Author:**

E-mail: sujatabyahatti@rediffmail.com

Abstract

Dens invaginatus (DI) which is even called as tooth within tooth is a rare developmental anomaly which results from a deep invagination of the enamel organ into the dental papilla during odontogenesis. This invagination can range from a slight pitting (coronal type) to an anomaly occupying most of the crown and root (radicular type). On clinical examination it may reveal a deep fissure or pit on the surface of a tooth, but radiographic examination is mandatory to diagnose the deep invagination. The presence of DI in the mandibular premolar teeth is rare and unusual. In this paper a 32-year-old female complaining of mobility with a premolar and its management is discussed in detail. The basic objective of this case presentation is to report a rare case of dens invaginatus occurring in the right mandibular premolar with brief review of literature.

Keywords: Double dens in dente, Dens invaginatus, Mandibular premolar.

Introduction

Dens in dente (DI), or (Dens invaginatus) is a rare developmental tooth anomaly which results from deep invagination of a part of the crown underneath. This invagination plays an important role as it has capacity of the possible pulpal involvement. Clinically this can be identified in a tooth which presents an unusual crown morphology or having deep foramen coecum. It is also noted that, clinically, unaffected teeth are usually diagnosed as an incidental finding on the radiograph. Whereas, presence of DI in the mandibular premolar teeth is unusual⁽¹⁾.

Dens invaginatus (DI), which is also known as “dens in dente” or “dilated composite odontome” or “gestant odontoma”, is a rare developmental tooth anomaly resulting from invagination of a portion of the crown (enamel organ) during morphodifferentiation⁽²⁻⁵⁾. This invagination can range from a slight pitting on the coronal surface (coronal type) to an anomaly which occupies most of the crown and the root portion (radicular type)^(5,6). The invagination is lined with enamel in coronal type and whereas invagination is lined with cementum in radicular type^(2,5). The etiology of DI remains as an unknown and controversial subject and the possible causes listed are as follows: (1) abnormal pressure resulting from the surrounding tissues, (2) rapid and aggressive proliferation of a part of the internal enamel epithelium invading the dental papilla, (3) local growth retardation, (4) invagination of the crown before calcification of the teeth, (4) infection and (5) genetic factors^(7,8). Various reports have mentioned the concomitant presence of DI with other dental anomalies such as dentinogenesis imperfecta, gemination, taurodontism, microdontia, supernumerary teeth and short roots and with some medical-dental syndromes^(1,4).

DI in a human tooth was first described by a dentist named ‘Socrates’ in 1856⁽¹⁾. Later Dens invaginatus was first classified by Hallet⁽¹⁰⁾ (1953) who suggested that the existence of 4 types of invagination is based on both clinical and radiographic criteria. Other classifications have also been described involving a variety of criteria and standards^(11,12). Schulze and Brand⁽¹³⁾ (1972) suggested an assessment is based upon 12 possible variations in both clinical and radiographic appearances of the invagination. Whereas the system described by Oehlers⁽¹⁴⁾ (1957a) appears to be the most widely used.

Here we report one such rare case of Dens invaginatus-Type 1 occurring in relation to lower right second premolar in detail with brief review of literature.

Case Report

A 32 year old female patient visited our department with a history of mobility and pain in her lower right posterior region of the jaw since 2 months. Initially she had similar type of pain which had occurred one year back which is pricking and gnawing type, intermittent in nature mild type and aggravates on mastication. She even noticed the mobility with the same tooth. On extra oral examination asymmetry was not noted and TMJ, lymph nodes were functioning within normal limits. The right submandibular groups of lymph nodes are enlarged, tender and palpable. The full complements of set of teeth were present with upper jaw with deposition of heavy calculus on the right side. The lower jaw shows crowns were placed with 35, 36 37 and 38 was missing. On the right side of lower jaw 46, 47 and 48 were missing. The second premolar (45) on the right quadrant was macrodontic with a deep groove noted on the occlusal surface running along (Fig 1). Grade 2 mobility was noted with the same tooth. The lingual

aspect of 45 showed recession with heavily deposited calculus (Fig 2). Then patient subjected for intraoral radiography, which shows a deep invagination noted on the coronal aspect (Fig 3). As patient was not willing to save the tooth and it was grade 2 mobile we performed extraction of the tooth and sent for ground sectioning. The ground section showed a clear deep invagination at the coronal surface (Fig 4) and the photomicrograph shows irregular dark calcified material surrounded by altered dentinal tubules in dentin. The dentinal tubules have lost "s" shaped structure and dead tract is evident surrounding the calcified material. Enamel appears to the normal showing enamel tufts and lamellae (Fig 5). As the tooth was grade 2 mobile and patient was not willing for saving the tooth we performed extraction with the same.

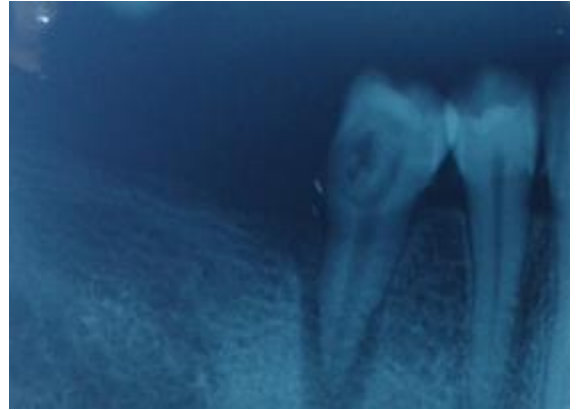

Fig. 3: IOPA showing Deep invagination noted at the coronal portion dividing it into two halves.

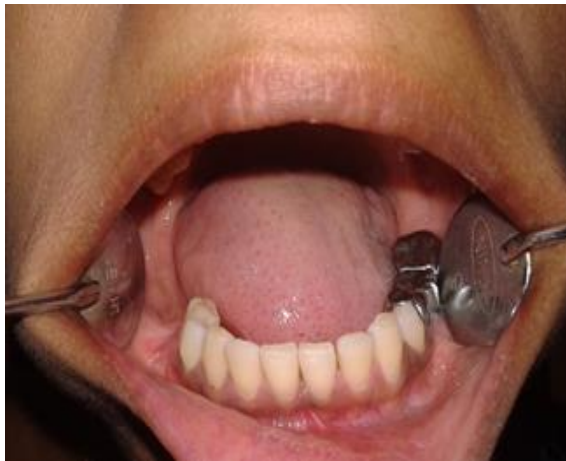

Fig. 1: Intraoral photograph showing Macrodontic 45 2nd premolar.

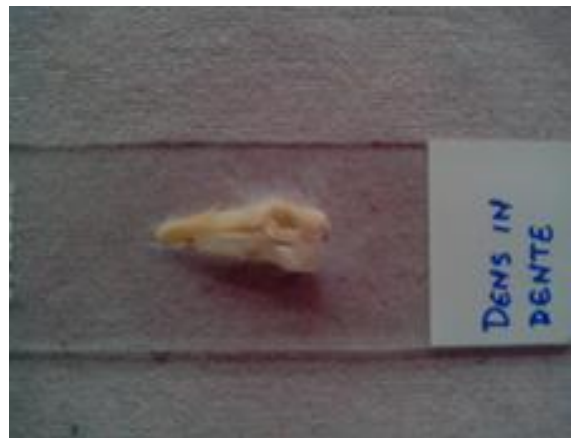

Fig. 4: Ground section showing the invagination at the coronal portion.

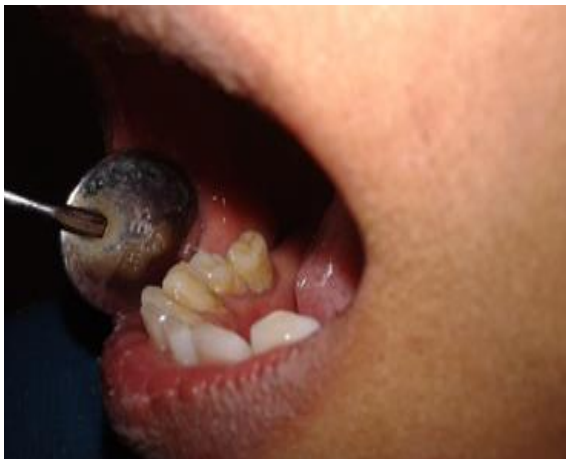

Fig. 2: Lingual aspect of 45 showing recession with heavy calculus deposit.

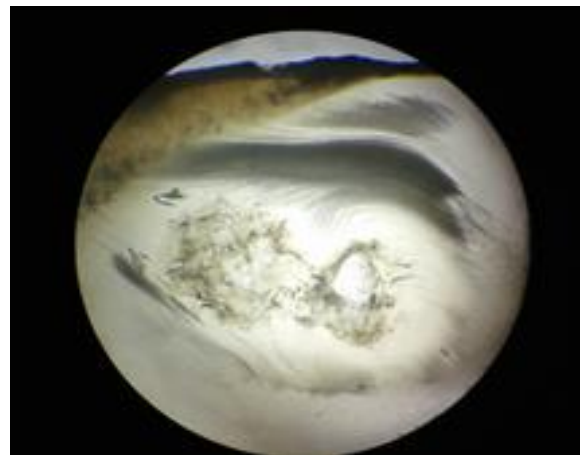


Fig. 5: Photograph showing the dentinal tubules have lost shaped structure and dead tract is evident 1187408.

Discussion

The detailed clinical examination of DI can reveal a deep fissure or pit on to the surface of an anterior tooth; however, radiographic confirmation is required for the most realistic and confirmatory way to diagnose the invagination^(2,5,6).

Causes

The causes of dens invaginatus remains as a controversial and quite unclear subject. Over the last few decades, several hypothesis have been put forward to explain the causes of dental coronal invaginations⁽²⁾. As it is suggested by Kronfeld (1934) the invagination is a result of a focal failure of growth of the internal enamel epithelium keeping the surrounding normal epithelium to proliferate and engulf the static area⁽¹⁵⁾.

According to Rushton (1937) the invagination results from rapid and aggressive proliferation of a part of the internal enamel epithelium which invades the dental papilla⁽¹⁶⁾.

As it has been considered by Oehlers (1957) the distortion of the enamel organ which occurs during tooth development and leading to subsequent protrusion of a part of the enamel organ leading to the formation of an enamel-lined channel ending at the cingulum or occasionally at the incisal tip^(14,17). Atkinson (1943) suggested that it was the result of external forces exerting which have an effect on the tooth germ during development⁽¹⁸⁾. Apart from these genetic factor also been proposed to be the cause^(19,20).

DI most commonly affects the maxillary lateral incisors followed by central incisors, premolars, canines and molars in decreasing order of frequency^(2,3,5,6).

DI occurs rarely in the mandible. Till date, approximately 13 cases have been reported, and five of them were in the premolar teeth^(7,21-25). Bilateral occurrence also reported in approximately 43% of the cases. Even though the invagination within the tooth is generally single, double and triple occurrences are even rarer anomalies and have been reported previously^(2,3,6,26,27). As double occurrence, nine cases have been reported, and only one of them was in a premolar tooth⁽²⁷⁾. In our case, invaginations was unilateral, in the right mandibular premolar region. DI rarely occurs in primary dentition but frequently in permanent dentition and has a general prevalence of 0.04–10%. The male to female predilection is 3:1 and, this condition exhibits a high degree of inheritance⁽²⁻⁷⁾. Among various classification systems of DI, Oehlers classification is the most popular and accepted one. He classified invaginations as follows. Type 1: Cases are those in which invagination is enamel-lined and ends as a blind sac within the crown, Type 2: Invagination extends apically beyond the cemento–enamel junction, but does not cross it and Type 3: Invagination extends beyond the cemento–enamel junction, penetrates the surface of the root and a second “apical foramen” is

evident^(2,3,6). According to Ohlers’s system, our case, showed the features similar to DI Type. Clinically, an unusual crown morphology or a deep foramen coecum may lead us to suspect a tooth with DI. In clinical findings characteristically, the DI presents as a deep invagination in the lingual or occlusal pit surface. The invagination area which gets separated from the pulpal tissues with a thin layer of dentin and frequently has communication with the oral cavity, making the entry of irritants and microorganisms, which usually leads to dental caries or infection and necrosis of the pulpal tissue and then to periodontal or periapical infections with continuous ingress.

The treatment of DI ranges from preventive (i.e. by sealing the invagination prophylactically with resin) and restorative treatment procedures in cases in which the bacterial invasion has reached the pulp and necrosis is established root canal therapy and where root canal therapy fails apical surgery can be performed and surgical removal of invagination under the operating microscope is recommended in cases where invagination is present within the root canal system. Extraction constitutes the final treatment option and can be preferred in hopeless cases^(2-8,28).

Radiographically, it shows a loop-like or pear-shaped defect which is lined by a radio opaque line with density equal to that of enamel, resembling a tooth within a tooth. In severe forms of invagination, the crown is malformed and an open apex is present.

Dens in dente never occurs alone it always accompanies other dental abnormalities such as taurodontism, microdontia, germination supernumerary tooth and dentinogenesis imperfecta⁽⁷⁾. As it is reported by Kantapura and Gorlin⁽⁸⁾ an extremely rare case of bilateral maxillary central incisors. Noikura et al⁽⁹⁾ reported bilateral double dens in dente of multi-tuberculated maxillary supernumerary central incisors with a central cusp⁽²⁹⁻³⁴⁾. Apical root resorption during orthodontic treatment is one of the adverse effect caused over compression of periodontal ligament⁽³⁵⁾. Dens invagination predisposes the tooth to root resorption during orthodontic treatment. The pulp in the invaginated canals is predisposed to infection resulting in apical breakdown. This apical breakdown can be aggravated by orthodontic forces⁽³⁶⁾. A periodic radiographic examination is required to monitor root resorption during orthodontic treatment and also to note down periapical infections.

Conclusion

As it is highly possible for tooth with DI for pulpal involvement it is very important for us to clinically to diagnose the lesion at earliest. As in our case, the patient had grade 2 mobility and lot of pain due to which she did not agree for saving the tooth we indicated it for extraction. Early diagnosis is required to save the tooth before it ends with the complications.

References

1. Canger EM, Kayipmaz S, Çelenk P. Bilateral dens invaginatus in the mandibular premolar region. *Indian J Dent Res* 2009;20: 238-40.
2. Mupparapu M, Singer SR. A rare presentation of dens invaginatus in a mandibular lateral incisor occurring concurrently with bilateral maxillary dens invaginatus: Case report and review of literature. *Aust Dent J* 2004;49:90-3.
3. Galindo-Moreno PA, Para-Vazquez MJ, Sanchez-Fernandez E, Avilla-Ortiz GA. Maxillary cyst associated with an invaginated tooth: A case report and literature review. *Quintessence Int* 2003;34:509-14.
4. O'Sullivan EA. Multiple dental anomalies in a young patient: A case report. *Int J Paediatr Dent* 2000;10:63-6.
5. Hülsmann M. Dens invaginatus: Aetiology, classification, prevalence, diagnosis, and treatment considerations. *Int Endod J* 1997;30:79-90.
6. Chen YM, Tseng CC, Harn W. Dens invaginatus: Review of formation and morphology with 2 case reports. *Oral Surg Oral Med Oral Pathol Oral Radiol Endod* 1998;86:347-52.
7. Mupparapu M, Singer SR. Diagnosis and clinical significance of dens invaginatus to practicing dentists. *N Y State Dent J* 2006;72:42-6.
8. Yeh SC, Lin YT, Lu SY. Dens invaginatus in the maxillary lateral incisor: Treatment of 3 cases. *Oral Surg Oral Med Oral Pathol Oral Radiol Endod* 1999;87:628-31.
9. Shulze C. Developmental abnormalities of the teeth and the jaws. In: Gorlin O, Goldman H, editors. *Thoma's Oral Pathology*. St. Louis; Mosby: 1970.p.96-183.
10. Hallet GE. The incidence, nature and clinical significance of palatal invagination in the maxillary incisors teeth. *Proc R Soc Med* 1953;46:491-9.
11. Ulmanský M, Hermel J. Double dens in dente in a single tooth. *Oral Surg Oral Med Oral Pathol* 1964;17:92-7.
12. Vincent-Townend J. Dens invaginatus. *J Dent* 1974;2:234-8.
13. Schulze C, Brand E. Über den dens invaginatus (Dens in dente). *ZWR* 1972; 81:569-73.
14. Oehlert FA. Dens invaginatus I. Variations of the invagination. *Oral Surg Oral Med Oral Pathol* 1957;10:1204-18.
15. Kronfeld R. Dens in dente. *J Dent Res* 1934;14:49-66.
16. Rushton MA. A collection of dilated composite odontomas. *Br Dent J* 1937;63:65-85.
17. Oehlert FA. Dens invaginatus II. Associated posterior crown forms and pathogenesis. *Oral Surg Oral Med Oral Pathol* 1957;10:1302-16.
18. Atkinson SR. The permanent maxillary lateral incisor. *Am J Orthod* 1943;29:685-98.
19. Hosey MT, Bedi R. Multiple dens invaginatus in two brothers. *Endod Dent Traumatol* 1996;12:44-7.
20. Pokala P, Acs G. A constellation of dental anomalies in a chromosomal deletion syndrome (7q32): Case report. *Pediatr Dent* 1994;16:306-9.
21. Banner H. Bilateral dens in dente in mandibular premolars. *Oral Surg Oral Med Oral Pathol* 1993;45:827-8.
22. Karaca I, Toller MO. Multiple bilateral dens in dente involving all the premolars. Case report. *Aust Dent J* 1992;37:449-52.
23. Bramante CM, De Sousa SM, Tavano SM. Dens invaginatus in mandibular first premolar. *Oral Surg Oral Med Oral Pathol* 1993;76:389.
24. Tavano SM, De Sousa SM, Bramante CM. Dens invaginatus in first mandibular premolar. *Endod Dent Traumatol* 1994;10:27-9.
25. Hartup GR. Dens invaginatus type III in a mandibular premolar. *Gen Dent* 1997;45:584-7.
26. Tüzüm MŞ, Bilge OM. Multiple bilateral dens invaginatus and an impacted cuspid in the maxillary incisor region: Case report. *Aust Dent J* 1990;35:128-9.
27. Bhatt AP, Dholakia HM. Radicular variety of double dens invaginatus. *Oral Surg Oral Med Oral Pathol* 1975;39:284-7.
28. Silberman A, Cohenca N, Simon JH. Anatomical redesign for the treatment of dens invaginatus type III with open apices: A literature review and case presentation. *J Am Dent Assoc* 2006;137:180-5.
29. Su-Chia Yeh, Yyg Tzertin, Shin Yulu, Dens invaginatus in the maxillary lateral incisor, *Oral Med Oral Pathol Oral Radiol Endod* 1999;87:628-31.
30. Shafer WG, Hine MK, Levy BM. *A Text Book of Oral Pathology*, 4th edn. Philadelphia: WB Saunders 1983;41-2.
31. Oehlert FA. Dens invaginatus, variations of the invagination process and associated anterior crown forms, *Oral Surg Oral Med Oral Pathol* 1957;10:1204-18.
32. Chen YM, Tseng CC, Harn WM. Dens invaginatus, Review of formation and morphology with 2 case reports, *Oral Surg Oral Med Oral Pathol* 1998;86:347-52.
33. Benenati FW. Complex treatment of a maxillary lateral incisor with dens invaginatus and associated aberrant morphology, *J Endod* 1994;20:180-2.
34. Vajrabhaya L. Non-surgical endodontic treatment of a tooth with double dens in dente: *J Endod* 1989;15:323-5.
35. Bender IB, Byers MR, Mari K. Periapical replacement resorption of permanent vital endodontically treated incisors after orthodontic tooth movement, Report of two cases, *J Endod* 1997; 23:768-73.
36. Fristad I, Molven O. Root Resorption and apical breakdown during orthodontic treatment of a maxillary lateral incisor with dens invaginatus, *Endod Dent Traumatol* 1998;14:241-4.