

## Clinicomorphological spectrum of Appendicectomy specimens

R. Thamil Selvi<sup>1\*</sup>, P. Koteswary<sup>2</sup>, K. Sivakami<sup>3</sup>, H. M. Prakash<sup>4</sup>

<sup>1,2</sup>Professor, <sup>3</sup>Assistant Professor, <sup>4</sup>Associate Professor, Vinayaga Mission's Kirupananda Variyar Medical College and Hospital, Salem, Tamil Nadu

**\*Corresponding Author:**

E-mail: drselvipatho@yahoo.com

---

### Abstract

**Introduction:** Appendicitis is a very common surgical emergency and carries risk of 7% the diagnosis of appendicitis is largely clinical and appendicectomy is the treatment of choice. If there is any delay in diagnosing appendicitis which may lead to complications like perforated appendix, peritonitis, sepsis, increased morbidity and mortality.

**Aims and Objectives:** To study the morphological features and to correlate the clinical diagnosis with the histopathological diagnosis of the appendicectomy specimens.

**Methods:** All the appendicectomy specimens received at histopathology section of our department and SIMS Chellum Hospital were reviewed retrospectively over a period of 2 years from January 2013 to December 2014 and prospectively over a period of six months from January 2015 to June 2015 were included in this study.

**Results:** A total of 149 specimens were analysed. 88 (59%) were males and 61 (41%) females. The histopathological examination showed acute inflammation in 97 (65%), chronic inflammation in 43 (28.8%), Gangrenous appendicitis in 6 (4.0%) and granulomatous in 1 (0.6%), Parasites were found in 1 (0.6%) and tumor like lesions in 2 (1.3%), were also seen in appendix. Clinico-pathological correlation for acute appendicitis was 69%, chronic appendicitis was 29% and for others (2%).

**Conclusion:** Acute appendicitis was the most common histopathological finding encountered in our study. The malignant neoplasm seen here was mucinous adenocarcinoma but clinically presented as acute appendicitis. Therefore careful and systematic study of all the surgically removed appendicectomy specimens are very important.

**Keywords:** Appendicitis, Appendicectomy, Histopathology of appendix, Mucinous adenocarcinoma.

---

### Introduction

Appendicitis is a very common surgical emergency and has a lifetime risk of 7% the diagnosis of appendicitis is largely clinical and appendicectomy is the treatment of choice. Delayed diagnosis of appendicitis could lead to complications like perforated appendix, peritonitis, sepsis, increased morbidity and mortality.<sup>(1,2)</sup>

### Aims and Objectives

1. To study the morphological features
2. To correlate the clinical diagnosis with the histopathological diagnosis of the appendicectomy specimens.

### Materials and Methods

All the appendicectomy specimens were reviewed retrospectively over a period of 2 years from January 2013 to December 2014 and prospectively over a period of six months from January 2015 to June 2015. All appendicectomy specimens received at histopathology section of our department and SIMS Chellum hospital were included in this study.

In each case, a short clinical history and physical examination along with relevant investigations were done. The specimens were fixed in 10% buffered formalin. A detailed gross examination of the appendicectomy specimens was done. Following the grossing of the specimens, tissue processing was done in an automatic tissue processor. Sections cutting and

staining were done using Hematoxylin and Eosin staining procedure. Special staining procedures like PAS (Periodic Acid Schiff), was carried out.

### Observation and Results

A total of 149 cases were studied. Emergency appendicectomy were done in 78.8 % of cases followed by interval appendicectomy in 21.2% cases. The most common position of appendix during surgery was in the retrocaecal region and the least common position was the pelvic region.

The youngest patient was four years old and the oldest was Eighty Three years of age. Overall, a higher number of appendectomies were performed in males (59%) compared to females (41%).

The most common symptom was right iliac fossa pain seen in 65 patients (43.6%), followed by generalized abdominal pain and vomiting 56 (37.6%) and triad of symptoms was seen in 28 (18.8%). The most common lesion seen in males was acute appendicitis in 56 (37.5%) cases followed by acute appendicitis with periappendicitis in 14(9.3%) cases.

Grossly, mucosal congestion was the most common finding seen in 77 (51.6%) cases. The neoplasms seen were mucinous neoplasm of uncertain malignant potential with pseudoxoma peritonei and mucinous adenocarcinoma.

Most of the patients were young in the age group of 20-30 years (Table 1). One case of mucinous neoplasm of uncertain malignant potential with pseudomyxoma peritonei was seen in a male patient of

50 years of age. One case of mucinous adenocarcinoma was seen in a forty year old male.

In the present study, the most common clinical diagnosis for which appendicectomy was done was acute appendicitis.

On histopathological analyses of 107 cases which presented as acute appendicitis, 87 (81.3%) were diagnosed as acute appendicitis (Fig. 1), 18 (16.8%) were diagnosed as acute appendicitis with periappendicitis, (Fig. 3 & 4) One case (0.95%) was diagnosed as Granulomatous appendicitis. (Fig. 5) and another case was diagnosed as mucinous adenomacarcinoma. (Fig. 6)

Five cases presenting clinically as appendicular lump were received. Of these, four were found to have appendicular abscess and one case was mucinous neoplasm of uncertain malignant potential with pseudomyxoma peritonei.

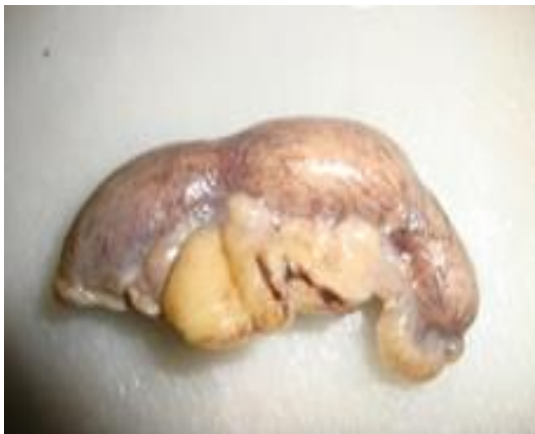Seven specimens were found to have acute appendicitis and were diagnosed as chronic appendicitis. Five cases of perforation peritonitis were received.

**Table 1: Age & Sex Incidence**

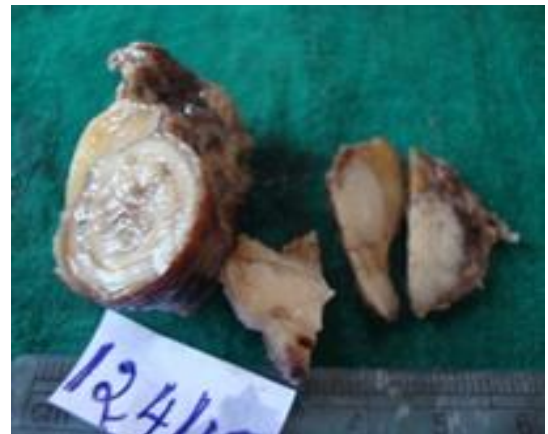	No of Cases	
	Males	Females
0-10	05	04
11-20	23	19
21-30	38	20
31-40	10	12
41-50	3	3
51-60	5	2
61-70	3	-
71-80	-	1
81-90	1	-
Total	88	61

**Table 2: Comparison of present study with various studies**

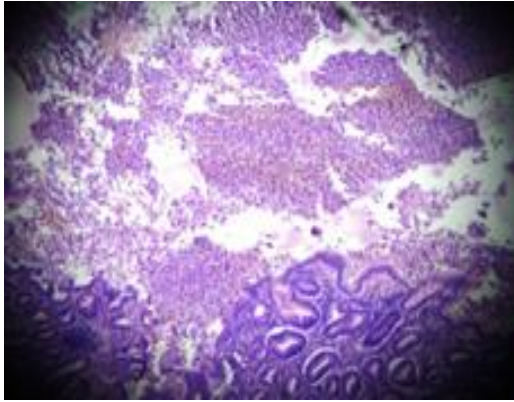
Study	Year	Total appendicectomy specimens	Abnormal percentage	Main abnormality
Jones AE et al <sup>(8)</sup>	2007	1225	77%	Acute appendicitis
Hamayun M et al <sup>(9)</sup>	2015	114	85%	Acute appendicitis
Emre A et al <sup>(10)</sup>	2013	1255	94%	Phlegomonous appendicitis
Monajemzedah M et al <sup>(7)</sup>	2011	947	64.1%	Inflammed appendix
Zarandi NP et al <sup>(11)</sup>	2014	342	79.5%	Acute appendicitis
Present study	2013-14	149	81.3%	Acute appendicitis



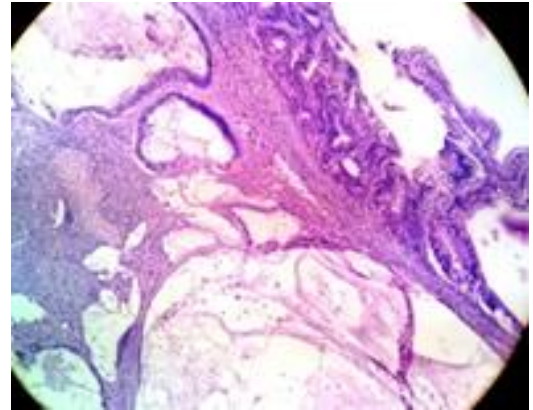
**Fig. 1: Enlarged Appendix**



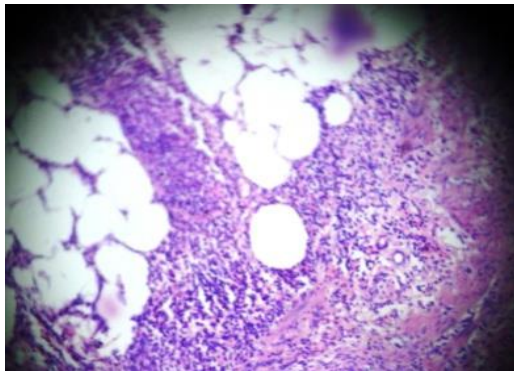
**Fig. 2: Mucin + Wall thickened-Mucinous Adenocarcinoma**



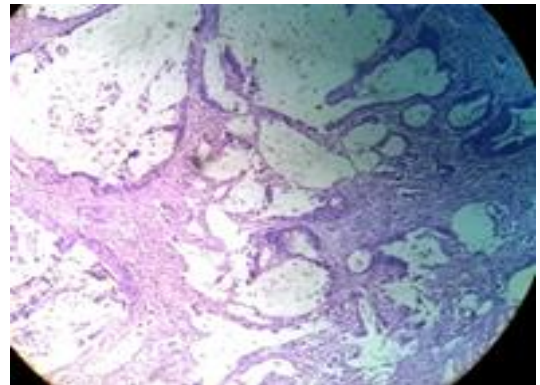
**Fig. 3: Appendicular lumen with Exudate**



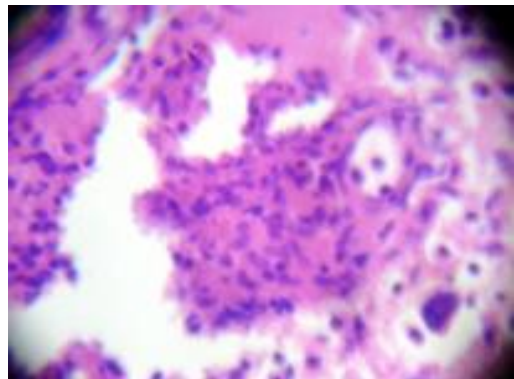
**Fig. 7: Mucinous Adenocarcinoma**



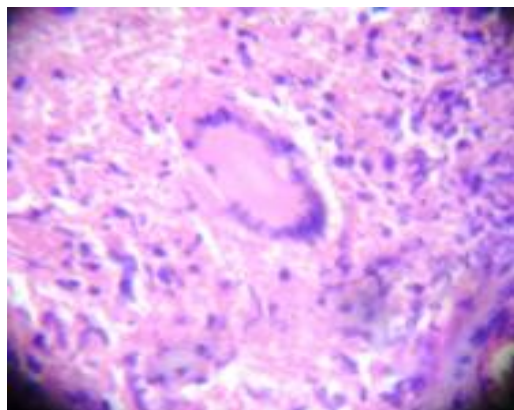
**Fig. 4: Periappendicitis**



**Fig. 8: Mucinous Adenocarcinoma**



**Fig. 5: Granuloma with Giant Cell**



**Fig. 6: Granuloma with Giant Cell**

### Discussion

The most frequently performed abdominal operation is appendicectomy and acute appendicitis is amongst the most common surgical emergency. However, true appendicitis incidence may be overrated based on histopathological evaluation. However, timely intervention is known to reduce the amount of complications. The histopathological examination is known to serve two important purposes confirmation of acute appendicitis primarily and second would be to identify any additional pathologies.<sup>(1)</sup>

Age incidence of appendicitis in our study was more in the second to third decade, which is similar to various studies. In our study 71.8% of the cases were of acute appendicitis. Other studies also showed similar incidence.<sup>(2,3)</sup> Many studies show a male preponderance for appendicitis with a range of 1.1:1 to 2.9:1. In our study, it was 1.43:1. The incidence of unusual findings in our study is low, similar to other studies. Compared to other studies, the incidence of malignancy is higher in our study. Few cases of parasitic infection and a case of granulomatous appendicitis was also noted.<sup>(4)</sup>

The incidence of appendiceal cancer is exceedingly rare (0.12 case per 1,000,000 people per year). Primary appendiceal cancer is difficult to diagnose preoperatively due to its vague and often normal presentation and any appendiceal carcinomas, if

diagnosed require right hemicolectomy for curative intent.<sup>(5)</sup>

Appendix neoplasms may present as acute appendicitis. In our study both neoplasms presented as acute appendicitis. Even though carcinoids are the common tumors of appendix, we did not notice any in our study.<sup>(6)</sup> In our study, both neoplasms were detected in above 40 year age group. Similar findings have been noted in other studies.<sup>(7)</sup>

In comparison to other studies, our prevalence of acute appendicitis and overall pathology found was within the normal range.<sup>(7-10)</sup>

Routine histopathology remains the gold standard for the primary diagnosis of all appendiceal lesions. Patient's age needs to be correlated as causative etiologies vary with age. Fecaliths, lymphoid hyperplasia being common causes, malignancies, especially in elderly should always be at the back of the mind.<sup>(11-15)</sup>

### Conclusion

Acute appendicitis, the most common disease which is encountered in our study. The malignant neoplasm seen here was mucinous adenocarcinoma, which clinically presented as acute appendicitis. Therefore, careful and systematic study of all the surgically removed appendicectomy specimens is very important.

### References

1. Jones AE, Phillips AW, Jarvis JR, Sargen K. the value of routine histopathological examination of appendicectomy specimens. *BMC Surg* 2007;7:17.
2. Oguntola AS, Adeoti ML, Oyemolade TA. Appendicitis: Trends in incidence, age, sex, and seasonal variations in South-Western Nigeria. *Ann Afr Med* 2010;9:213-7.
3. Nabipour F. Histopathological feature of acute appendicitis in Kerman-Iran from 1997 to 2003. *Am J Env Sci* 2005;1:130-2.
4. Sharma S et al. Histopathology of appendicectomy specimen: A 5 year study. *Scholar journal of applied medical sciences* 2014;2: 176-80.
5. Guraya SY. Do we still need to perform routine histological examination of appendicectomy specimens? *JCDR*.2015; 9(6):1.
6. Jat MA et al. Histopathological examination of appendicectomy specimens at a district hospital of Saudi Arabia. *Pak J Med Sci*. 2015;31(4):891-4.
7. Monajemzadeh M et al. Pathological evaluation of appendectomy specimens in Children: Is routine histopathologic examination indicated? *Iran J Pediar*. 2011;21(4):485-90.
8. Jones AE, Phillips AW, Jarvis JR, Sargen K. The value of routine histopathological examination of appendicectomy specimens. *BMC surgery*. 2007 Aug 10;7(1):1.
9. Hamayun M, Saba N, Bilal M, Mehsood N. Role of histopathology after emergency appendectomy. *Gomal Journal of Medical Sciences*. 2015 Mar 31;13(1).
10. Emre A, Akbulut S, Bozdag Z, Yilmaz M, Kanlioz M, Emre R, Sahin N. Routine histopathologic examination of appendectomy specimens: retrospective analysis of 1255 patients. *International surgery*. 2013 Oct;98(4):354-62.
11. Zarandi NP, Parsijani PJ, Bolandparvaz S, Paydar S, Abbasi H. Accuracy of Surgeon's Intraoperation Diagnosis of Acute Appendicitis, Compared with the Histopathology Results. *Bulletin of emergency & trauma*. 2014 Jan;2(1):15.
12. Zarandi NP, Parsijani PJ, Bolandparvaz S, Paydar S, Abbasi H. Accuracy of Surgeon's Intraoperation Diagnosis of Acute Appendicitis, Compared with the Histopathology Results. *Bulletin of emergency & trauma*. 2014 Jan;2(1):15.
13. Yilmaz M, Akbulut S, Kutluturk K, Sahin N, Arabaci E, Ara C, Yilmaz S. Unusual histopathological findings in appendectomy specimens from patients with suspected acute appendicitis. *World J Gastroenterol*. 2013 Jul 7;19(25):4015-22.
14. Akbulut S, Tas M, Sogutcu N, Arikanoglu Z, Basbug M, Ulku A, Semur H, Yagmur Y. Unusual histopathological findings in appendectomy specimens: a retrospective analysis and literature review. *World J Gastroenterol*. 2011 Apr 21;17(15):1961-70.
15. Hedyia MS, Nasr MM, Ezzat H, Hamdy H, Hassan A, Hammam O. Histopathological findings in appendectomy specimens: a retrospective clinicopathological analysis. *J Egypt Soc Parasitol*. 2012 Apr;42(1):157-64.