

Intratonsillar multiple epidermal inclusion cysts-A tumor mimic

Dhiraj B. Nikumbh^{1,*}, Roopali D. Nikumbh², Hemant More³

¹Professor, Dept. of Pathology, ²Associate Professor, Dept. of Anatomy, ACPM Medical College, Dhule, Maharashtra,

³Consultant ENT Surgeon, Dhule, Maharashtra

***Corresponding Author:**

Email: drdhirajnikumbh@rediffmail.com

Abstract

Epidermal inclusion cyst of oral cavity is a rare benign cystic lesion. In oral cavity, the most common affected site is floor of mouth but the tonsillar involvement by epidermal inclusion cyst seems to be very rare. Intratonsillar multiple epidermal inclusion cysts (EICs) are even rarer and only handful of case reports are reported in available literature. From the data search over Pubmed, Scopus and Goggle, we haven't found any case of intratonsillar multiple epidermal EICs from immunocompetent patient in India.

We discussed the role of histopathology in such rare lesions and highlight its rarity in view of clinical suspicious of malignancy. Histopathological diagnosed as multiple epidermoid cysts of right tonsil in a 40-year-old immunocompetent female.

Keywords: Tonsil, Epidermal inclusion cyst, Tumor, Benign.

Introduction

Epidermoid cysts are benign developmental lesion from abnormal epithelial components of ectodermal tissue formed during fetal period or implanted epithelium arising from trauma or surgery.⁽¹⁾ Epidermal inclusion cyst (EIC) has an incidence of 1.6-7% in head and neck region.⁽²⁾ It can be congenital or acquired. The most common site in oral cavity where cyst arises are sublingual, submental, submandibular, labial/lingual or buccal mucosa.⁽²⁾ Tonsillar involvement by EIC seems to be very rare.⁽²⁾ Multiple tonsillar EIC is even rarer in available literature. There are only handfuls of case reports of tonsillar EIC, but we haven't encountered the case of multiple epidermoid cysts in tonsil. The present case may be the first case of intratonsillar multiple EIC in Indian scenario in 40 year old immunocompetent female with clinical suspicious of malignancy. The role of histopathology in every resected tonsil is important to rule out benign cystic lesion as EIC to tumors as tonsillar carcinomas. In HIV positive patient, we expect multiple cysts ranges from benign to malignant condition, but in the present case 40-year-old female was HIV-negative presented with tumorous mass in right tonsil and histopathologically confirmed as intratonsillar multiple EIC.

Case Report

A 40-year-old female presented to the ENT OPD with chief complaints of difficulty in swallowing and pain in ear since one week. On local examination, she had hypertrophied right tonsil with congestion of pillars. Left tonsil appeared to be normal. The right sided cervical lymph nodes were enlarged and tender. Routine laboratory examination was within normal limits and serologically patient was non-reactive. Clinically diagnosed as tumorous mass s/o malignancy with chronic tonsillitis. The patient underwent

tonsillectomy under general anesthesia and post-operative was uneventful. We received right tonsillectomy specimen for histopathology measured 3x2.2 cms. External surface was circumscribed, round, regular with nodular areas (Fig. 1a) appeared to be hypertrophic with congested blood vessels. Cut section showed multiple cysts of varying diameter from 0.4 to 0.6 cms (Fig. 1b) with grey yellowish solid areas. The lumina of the cysts contain whitish material. Multiple sections studied showed features of chronic tonsillitis (Fig. 3) with many cysts lined by stratified squamous epithelium (Fig. 2) and the lumina of the cysts was filled with keratinous material, anucleated squames and cholesterol clefts (Fig. 4, 5). The tonsillar crypts contain dense lymphocytic infiltration. The wall of the cyst contain lymphoid follicles with prominent germinal centers s/o chronic tonsillitis (Fig. 3). Final histological diagnosis was rendered as multiple epidermal inclusion cysts of tonsil with chronic tonsillitis.

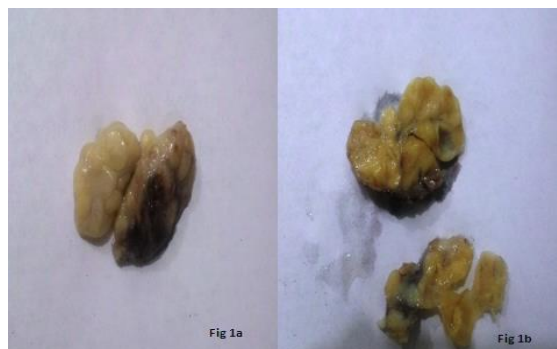

Fig. 1a): Gross of right tonsillar mass with hypertrophy, round regular and nodular areas, **b) C/S** showing multiple cysts of varying diameter with grey yellowish solid areas

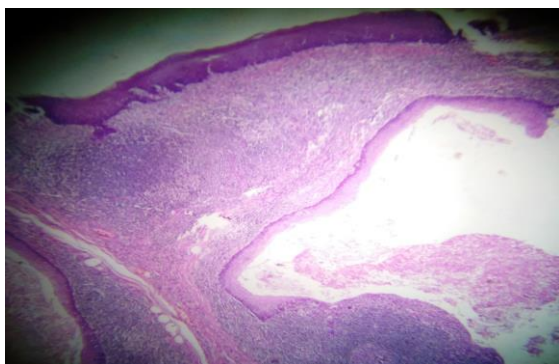


Fig. 2: Photomicrograph showing chronic tonsillitis with many cysts lined by stratified squamous epithelium (H & E, x100)

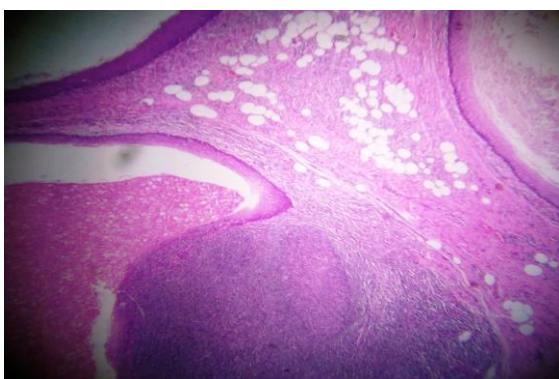


Fig. 3

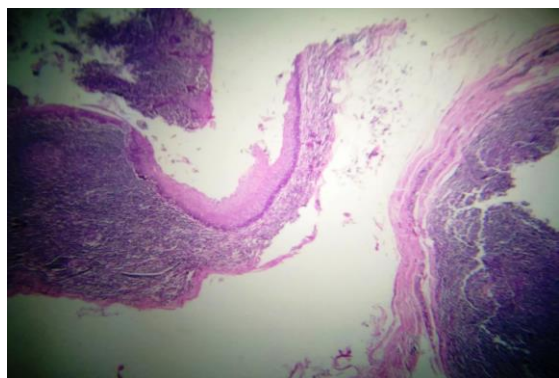


Fig. 4

Fig 3, 4: The wall of the cyst contain lymphoid follicles with prominent germinal centers s/o chronic tonsillitis with multiple epidermoid cysts (H & E, x100)

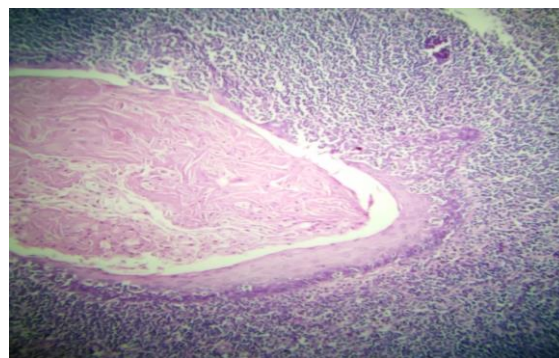


Fig. 5: EIC with lumina of the cysts filled with keratinous material, anucleated squames and cholesterol clefts (H& E, x400)

Discussion

The palatine tonsil is a pharyngeal lymphoid tissue with an external lining of stratified squamous mucosa.⁽³⁾ Epidermoid cysts are benign developmental lesion from abnormal epithelial component of ectodermal tissue during fetal period or implanted after surgery or trauma.^(4,5) Epidermoid cyst of head and neck constitutes 7% of cases. The incidence of EIC in oral cavity is upto 1.6% of total outcome and they constitute less than 0.01% of all cystic lesions of oral cavity.^(5,6)

The cysts in oral cavity are termed as “epidermoid” if they are enclosed and lined by stratified squamous epithelium only. If the wall of the cyst contains skin adnexal structures termed as “dermoid cyst” and if they include the tissues from ecto, endo or mesoderm like muscle, bone, cartilage or fat called as “teratoid cyst”.⁽⁷⁾ The treatment of choice is surgical excision. Recurrence after surgery is rare and malignant transformation into squamous cell carcinoma is reported but not common.⁽⁶⁾ EIC is lined by simple squamous epithelium and its wall does not contain skin adnexal structures or fibrous elements.⁽⁷⁾

The etiology of epidermoid cysts are varied and noted from hormonal influence during puberty to abnormal inclusion of cells during surgery/trauma or development from the epithelia remnants isolated during the closure of first and second branchial arches in the midline.⁽⁸⁾ The male to female ratio with diagnosis of EIC is 1:4 with majority in 10-35 years.⁽⁷⁾ Our patient was 40 years female presented with hypertrophied mass in tonsil.

The differentials of epidermoid cyst in tonsil are varied from benign lesions like dermoid cyst, lymphoepithelial cyst, and papilloma to tonsillar carcinoma. Histopathologically we can easily differentiate these entities, hence gross and microscopical examination of every resected tonsillar mass is important. Histopathology is the gold standard to rule out malignancy and to confirm the benign nature of tonsillar epidermoid cyst.

Conclusion

The aim of this short report is to highlight the role of histopathology in every resected tonsil and to enlighten the rarity of intratonsillar multiple epidermal inclusion cysts for proper patient management.

References

1. Suga K, Muramatsu K, Uchiyama T, Takano N, Shibahara T. Congenital epidermoid cyst arising in soft palate near uvula: a case report. *Bull Tokyo Dent Coll*, 2010;51(4):207-211.
2. Sandhya Panjeta Gulia, Lavanya M, Varun Kamidi, Arun Kumar SP. Epidermoid cyst of the tonsil: an incidental finding. *International Journal Of Advances In Case Reports*, 2015;2(12):777-779.
3. Swarnagowri B.N., Suba G., Nitya Prabhakaran. Epidermal Inclusion Cyst In Palatine Tonsil: A Case Report. *Sch J Med Case Rep* 2014;2(2):83-84.
4. Kini YK, Kharkar VR, Rudagi BM, Kalburge JV. An unusual occurrence of epidermoid cyst in the buccal mucosa: A case report with review of literature. *J Maxillofac Oral Surg*. 2013;12,90-93.
5. Calderon S, Kaplan I; Concomitant sublingual and submental epidermoid cysts: a case report. *J Oral Maxillofac Surg*, 1993;51(7):790-792.
6. Calderon S, Kaplan I. Concomitant sublingual and submental epidermoid cysts: A case report. *J Oral Maxillofac Surg* 1993;51:790-792.
7. Erol K, Erkan KM, Tolga D, Bengu C. Epidermoid cyst localized in the palatine tonsil. *J Oral Maxillofac Pathol*. 2013;17:148.
8. Gnepp DR; *Diagnostic Surgical Pathology of the Head and Neck*. 2nd ed. Philadelphia: Elsevier; 2009;226–227.