

## Histopathological spectrum of gallbladder diseases in a tertiary care centre

Dost Mohamed Khan<sup>1</sup>, Abilsh S.C<sup>2,\*</sup>

<sup>1</sup>Professor, <sup>2</sup>Associate Professor, Dept. of Pathology, Shri Sathya Sai Medical College & Research Institute, Balaji Vidyapeeth-Deemed University to be University, Kancheepuram, Tamil Nadu, India

**\*Corresponding Author:**

Email: abey4aris@gmail.com

### Abstract

**Introduction:** Gallstones are the commonest biliary pathology, the incidence ranging from 10% to 20% of the world population. Over 95% of biliary tract disease is attributable to cholelithiasis. Gallbladder stones are known to reduce histopathological changes in the gallbladder.

**Aim:** To study the spectrum of gallbladder pathology in cholecystectomy specimens.

**Materials and Methods:** The study was conducted from January 2011 to December 2014 in the department of pathology, tertiary care centre. A total of 197 cases of cholecystectomy specimens were stained using hematoxylin and eosin and evaluated.

**Results:** Gallstones and associated diseases were more common in women within 4th to 5th decade, with a maximum number of patients being 41 to 50 years. Histopathologically the most common diagnosis was chronic calculous cholecystitis amounting to 122 cases. Female preponderance was observed in all gallstone diseases. Gallstones were present in 126 cases and significantly associated with various lesions. Pigment stones were most common. The present study carried out in our institution showed gallbladder malignancy was uncommon and was seen only in two cases.

**Conclusion:** Almost all of the gallbladder lesions are inflammatory in origin, of which the most common disease being chronic calculous cholecystitis presenting with abdominal pain. Pigmented gall stones were found to be the most common etiology of chronic cholecystitis.

**Keywords:** Gall stones, Cholecystitis, Chronic Inflammation.

### Introduction

The gallbladder is a small pear-shaped sac located underneath the liver. Disease of gall bladder is one of the common gastrointestinal manifestations encountered worldwide. The prevalence of gall bladder diseases differs from nation to nation and in India it is found to be 2-29%.<sup>1,2</sup> Among complete gamut of gall bladder diseases ranging from non neoplastic to neoplastic lesions, cholelithiasis is the commonest disorder affecting about 20% of the population among developing countries.<sup>3</sup> Cholelithiasis leads to diverse histopathological changes in the gallbladder comprising of cholecystitis, cholesterolosis, metaplasia & hyperplasia.<sup>4</sup>

Risk-factors involved in the occurrence gall bladder stone diseases can be classified into modifiable and non-modifiable. Factors encompassing sedentary lifestyle, obesity, metabolic syndrome, pregnancy and parity, high fat & low fiber diet, can be included in the modifiable ones; the non-modifiable ones comprise age, female sex preponderance, hereditary and ethnicity. Most of gallstones (>80%) are "silent" but gallstones can also cause numerous complications associated with cholecystitis and can lead to significant morbidity and mortality.<sup>5</sup> The rare and most fearsome complication of gallstone disease is a carcinoma, since it carries the worst prognosis notably when diagnosed at a later course of the disease.<sup>6</sup>

The current study was undertaken to determine the demographic profile along with the varied histopathological spectrum of gall bladder lesions

encountered in surgically resected cholecystectomy specimens.

### Materials and Methods

The study was a retrospective observational study conducted in the Department of Pathology, Shri Sathya Sai Medical College and Research Institute, Kancheepuram district, India, during the period of four years between January 2011 and December 2014. Patients of all ages were considered in the present study. Clinical details including age and sex of the patient, other relevant clinical findings were recorded from the hospital registry. Specimens were received in 10% buffered formalin and processed under routine histopathology techniques. All specimens were subjected to gross and microscopic evaluation. Multiple sections were taken from the larger specimens and the smaller ones were fully submitted for processing by paraffin embedding. Appropriate number of 4-5 micron thick tissue sections were cut and stained routinely with Hematoxylin and Eosin (H&E).

### Statistical analysis

Data regarding various etiologies of gallbladder lesions was collected and analyzed by using IBM Statistical Package for the Social Sciences (SPSS) Software version 21. Statistical methods including Pearson Chi-square test and Fischer's exact tests were applied to compare whether a significant difference exists between different variables. Significance of the

statistical tests at P value less than 0.05 was based on 95% confidence interval.

## Results

Total 197 cholecystectomy specimens were included in the present study. Gallstones and associated diseases were more common in women within 4th to 5th decade as compared to men with a M:F ratio 0.6:1, Table.1

**Table 1: Age & sex distributions in gallbladder diseases**

Age(Years)	Male	Female	Percentage
21-30	3	7	3.5%
31-40	18	25	21.82%
41-50	31	59	45.68%
51-60	16	21	18.78%
61-70	5	9	7.10%
71-80	1	2	1.5%
Total	74(37.56%)	123(62.43%)	

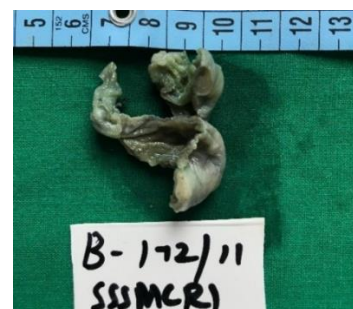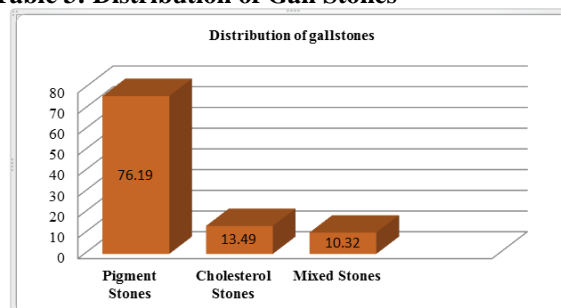
**Table 2: Distribution on the basis of Histopathological Lesions**

Histopathology Lesions	Frequency	Percentage
Acute Calculous Cholecystitis	4	2%
Chronic Calculous Cholecystitis	122	61.92%
Chronic Acalculous Cholecystitis	37	18.78%
Chronic Cholecystitis with Cholesterolosis	18	9.13%
Chronic Cholecystitis with adenomatous hyperplasia	3	1.52%
Empyema	2	1.01%
Xanthogranulomatous Cholecystitis	9	4.56%
Adenocarcinoma Gallbladder	2	1.01%

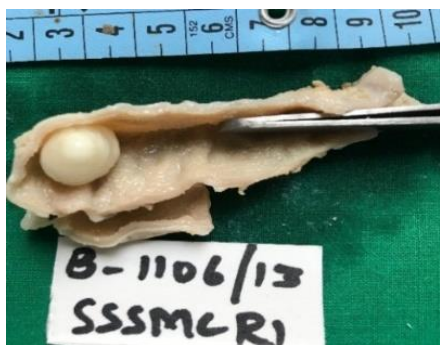The age of patients varied from 21 to 80 years, with a maximum number of patients being 41 to 50 years (45.68%). Histopathologically the most common diagnosis was chronic calculous cholecystitis (122/197; 61.92%) followed by acute or chronic acalculous cholecystitis (37/197; 18.78%). There were 18 cases of chronic cholecystitis with cholesterolosis, 9 cases of Xanthogranulomatous cholecystitis, 4 cases of acute cholecystitis, 3 cases of Chronic Cholecystitis with adenomatous hyperplasia 2 cases and one case each of empyema and carcinoma. The present study carried out in our institution showed gallbladder malignancy was uncommon and was seen only in two case which was diagnosed as adenocarcinoma.

Gallstones were present in 126 cases (63.95%) and significantly associated with various lesions (p-value=0.0001, highly significant). Pigment stones were most common, followed by cholesterol and mixed stones Table 3.

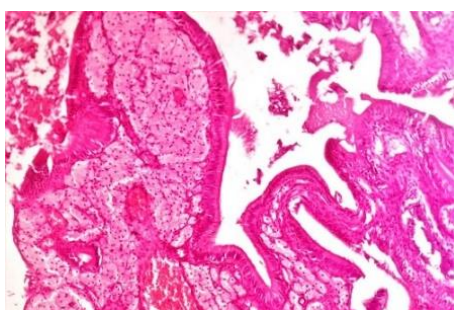
**Table 3: Distribution of Gall Stones**



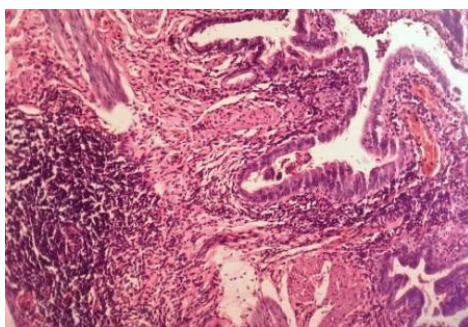
**Fig. 1:** Shows cut-section of gallbladder with partial loss of mucosal velvety appearance and lumen filled with turbid bile



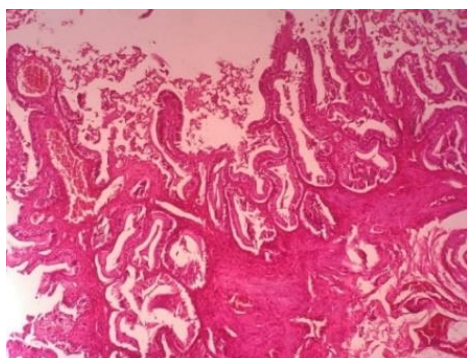
**Fig. 2:** Shows cut-section of gallbladder with total loss of mucosal velvety appearance, ulceration and single pale yellow, roughly ovoid, firm stone is seen in the fundus



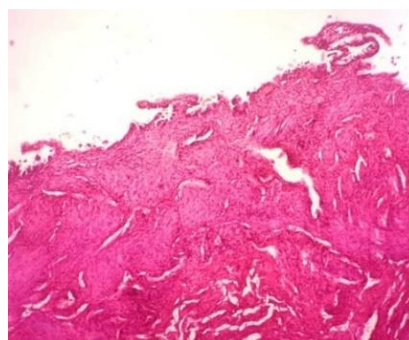
**Fig. 3:** H&E 10x Photomicrograph of Cholesterolosis - Gall Bladder mucosa showing foamy macrophages in lamina propria



**Fig. 4:** H&E 10X Photomicrograph of Chronic Cholecystitis - Gall Bladder wall showing lymphoid aggregates



**Fig. 5:** H&E 10x Photomicrograph showing Gall Bladder with hyperplastic mucosa



**Fig. 6:** H&E 10x Photomicrograph showing Gall Bladder with atrophy and denudation of mucosa

### Discussion

The term cholecystitis refers to a group of disorders that vary in clinical, pathogenetic and pathological characteristics. Characterization of inflammatory pattern helps the pathologists to confirm the diagnosis. Out of 197 cases, 195 cases were non-neoplastic or inflammatory lesions and two cases were malignant lesions. 82% of the cases were chronic cholecystitis. Most of the cases of chronic cholecystitis were associated with cholelithiasis.

Chronic acalculous cholecystitis was much less common in our study. In this study, of the total 197 cholecystectomies, gall stones were seen in 122 (61.92%) cases, finding that was consistent with other studies.<sup>7</sup> There were 74 (37.56%) men and 123 (62.43%) women with a M: F ratio of 0.6:1, which was consistent with Memon et al., and Selvi et al.<sup>8,9</sup> Out of 197 cases 86% patients were complaining of pain in the epigastrium, followed, by pain and vomiting. None of the patients has presented with any evidence of malignancy clinically. This finding correlated well with other studies.<sup>10,11</sup>

Gallstones are a major cause for morbidity throughout the world. They are associated with various lesions like acute cholecystitis, chronic cholecystitis with its variants and gallbladder carcinoma. In the present study 126 cases (63.95%) had stones while in 71 cases (36%) there were no stones. Among calculous cholecystitis, pigmented stones were more predominant 93(76.13%) followed by 17 (13.49%) cases of cholesterol stones and 13(10.31%) cases presented with mixed stones.

These observations were in accordance with the study conducted by Selvi et al.<sup>9</sup> In this study, histopathology examination of all the resected gall bladder specimens (100%) showed had inflammation predominated by dense lymphoplasmacytic infiltrate in 154 cases (78.17%), mild infiltration of lymphocytes seen in 24 cases (12.18%) and 19 cases (9.64%) had mixed inflammation.

Two cases (1.01%) of adenocarcinoma of the gallbladder reported in our study. These cases were diagnosed incidentally on histopathology; there were clinical or radiological suspicion of malignancy. These

two cases were females of ages 48 and 62 respectively. Our study was in concurrence with the other similar studies which reported the incidence of adenocarcinoma gallbladder diagnosed after cholecystectomy was between 0.19% and 3.3%.<sup>2,8</sup>

Eosinophils were seen in a single case (0.5%). Mucosal ulceration was noted in 44 (22.33%) cases, denudation of mucosa was observed in 41 cases (20.81%), fibrosis was seen in 86 (43.65%) cases, 98 (49.75%) cases showed Rokitansky-Aschoff Sinus, hyperplasia of the gall bladder mucosa was encountered in five cases (2.54%) and single case demonstrated metaplasia (0.5%), These observations were similar to the studies done by Sumit G and Baidya R et al.,<sup>10,11</sup> and in discordance with the other similar studies Narendra et al and Naqvi et al.<sup>2,13</sup>

### Conclusion

Gallbladder disease demonstrated diverse spectrum of histopathological changes in the cholecystectomy specimens. In agreement with other studies, the current study has affirmed that it showed female predominance. The study wishes to emphasize that chronic cholecystitis should always be considered as one of first line diagnosis whenever middle aged females presenting with abdominal pain. Two cases of adenocarcinomas were incidentally diagnosed in our study; hence we conclude that complete and meticulous macroscopic and microscopic examinations of all cholecystectomy specimens are mandatory.

**Conflict of Interest:** None

### References

1. Stinton LM, Shaffer EA. Epidemiology of gallbladder disease: Cholelithiasis and cancer. *Gut Liver* 2012;6:172-87.
2. Zhang WJ, Xu GF, Zou XP, Wang WB, Yu JC, Wu GZ, et al. Incidental gallbladder carcinoma diagnosed during

- or after laparoscopic cholecystectomy. *World J Surg* 2009;33:2651-56.
3. Bladder G. Extrahepatic biliary tree and ampulla. In: Mills SE, editor. *Stenberg's Diagnostic Surgical Pathology*. 5th ed., Vol. II. Wolters Kluwer, 2010. p. 1600-51
4. Kafle SU, Sinha AK, Pandey SR. Histomorphology spectrum of gall bladder pathology in cholecystectomy specimens with clinical diagnosis of chronic cholecystitis. *J Nepal Med Assoc* 2014;52(192):600-07.
5. Mahana S, Poflee V, Shrikandae AV. Morphological spectrum of gallbladder lesions presenting as biliary colic. *J Biosci Tech* 2013;4(3):519-24.
6. Mohan H, Punla PS, Dhawan B, Ahal S. Morphological spectrum of gallstone disease in 1100 cholecystectomies in North India. *Indian J Surg* 2005;67(3):140-42.
7. Khan S, Jetley S, Husain M. Spectrum of histopathological lesions in cholecystectomy specimens: A study of 360 cases at a teaching hospital in South Delhi. *Arch Int Surg* 2013;3:102-5.
8. Memon W, Khazada TW, Samad A, Kumar B. Histopathological spectrum of gallbladder specimen after cholecystectomy. *Pak J Med Sci* 2011;27:533-56.
9. Selvi T, Sinha P, Subramaniam PM, Konapur PG, Prabha CV. A clinicopathological study of cholecystitis with special reference to analysis of cholelithiasis. *Int J Basic Med Sci* 2011;2(2):68-72.
10. Sumit G. Histopathological changes in gallbladder mucosa associated with cholelithiasis. *Int J Cur Res Rev* 2013;5(4):126-29.
11. Baidya R, Sigel B, Baidya N L. Histopathological changes in gallbladder mucosa associated with cholelithiasis. *J Pathol Nepal* 2012;2:224-25.
12. Narendra GN, Gautam K. A spectrum of benign gallbladder diseases and their laparoscopic management: An experience of 100 patients. *IJHRMLP* 2015;1(2):25-31.
13. Naqvi SVH, Mangi IH, Dahri FJ, Khaskheli QA, Akhund AA. Frequency of carcinoma of gallbladder in patients with cholelithiasis. *Gomal J Med Sci* 2005;3(2).

**How to cite the article:** Khan D.M, Abilsh S.C. Histopathological spectrum of gallbladder diseases in a tertiary care centre. *Arch Cytol Histopathol Res* 2018;3(4):206-209.