

## Evaluation of Ki-67 marker in differentiating cervical intraepithelial neoplasia and benign lesions: A study of 50 cases

Manisha Bharadwaj<sup>1</sup>, Neil Sharma<sup>2,\*</sup>, B.P Nag<sup>3</sup>, M. L Yadav<sup>4</sup>

<sup>1</sup>Junior Consultant, <sup>2</sup>Assistant Professor, <sup>3</sup>Professor and Head, <sup>4</sup>Professor, <sup>1-4</sup>Dept. of Pathology, <sup>1</sup>Pathologist at Rotary Blood Bank, <sup>2</sup>Government Medical College Bharatpur, Rajasthan, <sup>3,4</sup>Mahatma Gandhi Medical college Jaipur, Rajasthan, India

\*Corresponding Author: Neil Sharma

Email: neil.nanotech@gmail.com

### Abstract

**Introduction:** Cervical cancer is the worldwide third most common cancer and fourth most common cause of cancer related deaths in female population, accounting to approximately 453,300 cases per year and 275, 100 deaths in the year 2008. According to the latest WHO global cancer statistics, the cumulative risk (%) (Age 0-74) of cervical carcinoma is 0.9 with age adjusted ratio of 9.0 (Jemal et al., 2011). Supplementary methods using objective biomarkers are needed to achieve more accurate diagnosis. Ki-67 is a well known proliferative marker, useful for confirmation of the diagnosis in ambiguous cases and CIN grading.

**Aims:** The aim of this study is to evaluate Ki-67 marker by immunohistochemical methods in differentiating CIN from benign cervical lesions.

**Materials and Methods:** The study was done at Department of Pathology, MGMCH, Jaipur it was a Hospital-based observational study consisting of 50 cases.

**Statistical methods:** sensitivity, positive predictive value, negative predictive value, and specificity was calculated.

**Results:** Proliferative index was <10% in all the non neoplastic cases while it was either between 10% to 50% or >50% in neoplastic cases. Accordingly scoring for Ki-67 stained nuclei was done with score 0 means no staining, 1 means weak positive (<10%), 2 means positive (10%-50%) and 3 means (>50%). In our study Statistical analysis of Ki-67 marker shows that sensitivity of this marker is 94.7%, specificity is 96.7%, positive predictive value 94.7%, negative predictive value 96.7% and accuracy is 96%. P value is <0.001, chi square value is 41.868 and degree of freedom is 1.

**Conclusion:** In summary many studies have shown that there is statistically significant relation between proliferative activity, distribution of Ki-67 positive cells and CIN grade. Ki-67 antigen could be a tool to identify women who are at higher risk for progression and/or recurrence of cervical squamous precancerous lesion and in differentiating between benign and malignant cervical lesions.

**Keywords:** Cervix, Ki-67, Benign, Malignant, Cervical intraepithelial neoplasia.

### Introduction

Cervical cancer is the worldwide third most common cancer and fourth most common cause of cancer related deaths in female population, accounting to approximately 453,300 cases per year and 275, 100 deaths in the year 2008.<sup>1</sup>

According to the latest WHO global cancer statistics, the cumulative risk (%) (Age 0-74) of cervical carcinoma is 0.9 with age adjusted ratio of 9.0.<sup>2</sup> In India, cervical cancer is the leading cancer among females between 15 and 44 years of age.<sup>1</sup> Having said this, however, no form of cancer better documents the remarkable effects of prevention, early diagnosis, and curative therapy on the mortality rate than the cancer of cervix.

However, the still very high rate of cervical carcinoma in developing countries like India is because of lack of proper screening methods and lack of health infrastructure which allows for periodical and routine screening.

Potential threat of cancer has reduced significantly in developed countries, due to Papanicolaou smear screening programs. The most important feature determining survival in carcinoma of the cervix is thought to be the clinical stage of the tumour at presentation (Kottmeier, 1971).<sup>3</sup>

Papanicolaou smears or commonly referred as Pap smears is a cost effective and reproducible screening technique for diagnosing precursor lesions of cervical carcinoma. However, Pap test gives significant false

positive (30%)<sup>4</sup> and false negative (15-50%) results due to subjective test criteria.<sup>5</sup>

Apart from the Pap smear screening test, histopathological diagnosis of cervical intraepithelial neoplasias (CINs) and cervical carcinoma is considered as the age old "gold standard" method of diagnosis of cervical neoplasm. However this can also be biased by interobserver variability as reported before.<sup>6</sup>

Nearly every pathologist that practice in a community hospital setting struggle with the accurate and reproducible identification of HPV effect and dysplasia in the female genital tract and recognizes the fact that in certain situation these conditions can be very difficult to distinguish from reactive changes.<sup>7</sup>

These factors limit, present screening programs and histopathological examination and emphasizes the need for the identification of specific biomarkers for dysplastic epithelial cells to aid in primary screening and lesion diagnosis.

A fundamental division of cervical squamous epithelium abnormality can be made between those which lack any potential for evolving into an invasive squamous cell carcinoma and those in which there is a significant risk of progression to an invasive neoplasm.

All of which are benign indeed usually physiological conditions unaccompanied by any increased risk of invasive carcinoma but may misinterpret as premalignant lesion.<sup>8</sup>

Epithelial abnormalities that are potentially capable of progression into an invasive neoplasm have traditionally been categorized either as dysplasia or as carcinoma in situ.<sup>8</sup>

Definition of dysplasia that is employed by WHO is "Dysplasia is a lesion in which part of the thickness of the epithelium is replaced by cells showing varying degree of atypia."<sup>8</sup>

It is usually associated with human papilloma virus infection and is frequently detected on Pap smear as "Squamous intraepithelial lesion". The more common abnormal finding on pap test include low and high grade SIL (LSIL and HSIL), atypical squamous cells of undetermined significance (ASCUS), and atypical squamous cells without excluding high grade SIL. Abnormal Pap smear requires follow up testing that may include Pap test, colposcopy directed biopsies or more extensive biopsies such as a CONE or LOOP Excision electrosurgical procedures (LEEP).<sup>8</sup>

Dysplasia that is seen on cervical biopsies is called CIN. It is grouped into three categories:

CIN-1 (Mild Dysplasia)

CIN-2 (Moderate Dysplasia)

CIN-3 (Severe dysplasia to carcinoma in situ)

According to the guidelines of the American society of colposcopy and cervical pathology (ASCCP), women with cervical biopsy confined to CIN2 or CIN3 should undergo an excisional treatment to prevent potential progression to invasive cancerous growth. These therapies may potentially affect reproductive outcomes, especially in young women; and most low grade squamous intraepithelial lesion (CIN-1) regress spontaneously.

Despite the existing well defined criteria the histomorphologic diagnosis is subjected to high rate of discordance among pathologists. Therefore it is important to have accurate diagnostic interpretation of cervical biopsy specimen to differentiate between benign and CIN lesions and to distinguish between low grade (CIN-1) and high grade CIN (CIN2 and CIN3) to avoid overtreatment of false positive cases and under treatment of false negative cases.<sup>9</sup>

Supplementary methods using objective biomarkers are needed to achieve more accurate diagnosis.

Ki-67 is a well known proliferative marker, useful for confirmation of the diagnosis in ambiguous cases and CIN grading.<sup>10</sup>

The aim of this study is to evaluate Ki-67 marker by immunohistochemical methods in differentiating CIN from benign cervical lesions.

#### **Grading (Score) For Ki-67 Stained sections (Milena Panjkovic)**

Grade 0 No staining

Grade 1 Weak positive (low proliferation), Mount of positive

Grade 2 Positive(moderate proliferation), Mount of positive

Grade 3 Strong positive(high proliferation), Mount of positive

Score 0 and 1 are counted as negative and score 2 and 3 as positive cases.

cell are <10%

cells are >10% but <50%

cells >50%

#### **Aims and Objectives**

The present study was aimed to evaluate the Ki-67 marker in differentiating CIN and benign lesions. To find out the potential correlation between proliferative activity, distribution of Ki-67 positive cells and CIN grade. To assist in identifying the extent of Ki-67 immunostain with increasing grades of dysplasia.

#### **Materials and Methods**

The study was done at Department of Pathology, Mahatma Gandhi Medical College & Hospital, Sitapura, Jaipur (Rajasthan) from June 2014 to October 2016. It was a Hospital based Comparative Cross Sectional Observational Study done on 50 patients

#### **Eligibility Criteria**

##### **Inclusion Criteria**

All patients presenting with complaints of discharge per vagina, growth lower genital tract and cervical biopsy is taken for the proper diagnosis.

##### **Exclusion Criteria**

Biopsy tissue is inadequate. Biopsy tissue is showing only endocervical tissue.

#### **Material for Study**

It is obtained from cervix either from hysterectomy specimens or biopsies received in the department of pathology.

Biopsy tissue was fixed in buffered 4% formaldehyde, embedded in paraffin, cut at 4 micron, and stained with hematoxylin and eosin (HE).

Immunostaining for Ki-67 will be carried out. Following endogenous peroxidase and protein blocking step, the slides will be incubated with primary antibodies. After brief washes, incubation of monoclonal rabbit IgG for 30 minutes will be performed

Mayer's haematoxylin-it is an alum haematoxylin which is chemically ripened with sodium iodate was used as the H&E stain.

Immunoreactive Ki-67 positive cells show dark brown, homogenous or punctuate staining, limited exclusively to the nucleus. Following grading was applied for Ki-67 staining.

**Observations**

The present study was undertaken during a period of 30 months from May 2014 to October 2016. formalin fixed specimens of uterus and cervical biopsies were received in the pathology department of Mahatma Gandhi medical College and Hospital.

The specimens were fixed in formalin, processed and paraffin blocks were made. The blocks were cut at 3-5 micron thickness and stained with hematoxylin and eosin.

Detailed microscopic examination of the tissue was done by the experienced pathologist to arrive at the Histopathological diagnosis.

Immunohistochemical stains performed by using paraffin sections of the (50cases) original ASL diagnostic samples with primary antibody MIB-1 against Ki-67 were received and evaluated as follows:

1. Ki-67 cells present or absent in the upper 2/3<sup>rd</sup> of the squamous epithelial layer.
2. % of stained nuclei in the layers of cervical epithelium for measuring Ki-67 Proliferative Index.

The results were compared with the previous Histological diagnosis done with the routine H&E staining only.

In the present study total 50 cases were studied, out of which 28 cases were clinically diagnosed as benign and 22 were diagnosed as malignant.

In the present study total 50 cases were studied. These 50 cases were divided into 2 groups according to the age. Below 45 years total 11 cases were considered benign and 11 cases were malignant, while above the age of 45years 11 cases were grouped as benign and 11 were malignant. Mean age is 45 yrs.

Out of 50 cases, 7(14%) cases were diagnosed as chronic cervicitis, 10(52%) cases of squamous metaplasia, 11(22%) cases of epithelial hyperplasia, 11(22%) cases of dysplasia, 4(8%) cases of carcinoma in situ and 7(14%) cases of carcinoma (squamous cell carcinoma).

Out of 50 cases of atypical squamous lesions 15 cases were diagnosed as dysplasia on H and E staining. Out of 15 dysplasia cases, 4(26.6%) cases were grouped in to low grade dysplasia while other 11(73.3%) cases were in high grade dysplasia.

Out of 50 cases, total 32 cases were considered non neoplastic ASLS while 18 cases were of neoplastic ASLS. Non neoplastic ASLS include all benign cases and low grade Dysplasia.

**Table 1: Distribution of Ki-67 Stained nuclei in the cervical squamous epithelium.**

SQ. Epitelial Layers	No. of Patients	% of Patients
Basal	14	28%
Supra Basal	11	22%
Lower 1/3 <sup>rd</sup>	4	08%
Middle 1/3 <sup>rd</sup>	7	14%
Upper 1/3 <sup>rd</sup>	2	04%
Full Thickness	12	24%

Table shows that In 14 cases Ki-67 stained nuclei were present only in Basal layer, in 11 cases in Suprabasal layer, in 4cases up to lower 1/3<sup>rd</sup> of squamous epithelial layer, in 7 cases Ki-67 stained nuclei were present in middle 1/3<sup>rd</sup> of layer, 2 cases were showing stained nuclei in upper 1/3<sup>rd</sup>

layer and 12 cases were showing stained nuclei in full thickness of squamous epithelium. Though overlapping of Ki-67 stained nuclei was seen in the middle 1/3<sup>rd</sup> and upper 1/3<sup>rd</sup> of layer.

**Table 2: Extent of Ki-67 Stained nuclei in the ASLS.**

ASLS	Basal	S. Basal	Low1/3rd	Mid1/3rd	Upp1/3rd	F.T.	Total
CC	4	2					6
SM	6	4					10
EH		9	1	1			11
MILD DYS		1	4				5
MOD DYS				4			4
SEV. DYS					6		6
SCC						7	7

In our study stained nuclei in Ch. Cervicitis, Sq. Mtaplasia and in Ep. hyperplasia were limited up to basal and s. basal layer while in mild dysplasia stretched up to

lower 1/3<sup>rd</sup>. In all cases of sever dysplasia nuclei were seen involving up to full thickness.

**Table 3: % of Ki-67 Stained nuclei IN ASLs (P.I).**

% of Stained Nuclei	No. of Cases	% of Cases
0	1	02%
<10%	30	60%
10-50%	6	12%
>50%	13	26%

Out of 50 cases 30cases were showing <10% stained nuclei, 6 cases were showing staining between 10 to 50

nuclei and 13 case were showing >50% stained nuclei.1 case showed no staining.

**Table 4: Pattern of distribution of Ki-67 Stained nuclei.**

Pattern	No. of ASLs	% of ASLs
Not Scattered	30	61.2
Scattered	19	38.7

In 38.2% ASLs Ki-67 stained nuclei were showing scattering pattern and were distributed evenly while in 61.7% ASLs nuclei were limited to only basal and suprabasal layer. No scattering was seen in non neoplastic cases.1case showed no staining.

In neoplastic ASLs atypical mitotic activity is seen.in this study 46% cases were showing atypical mitosis while 54%cases were showing normal mitosis usually present in basal layer.

**Table 5: Ki-67 Scoring.**

Score	No. of Cases	% of Cases
0	1	2%
1	30	60%
2	6	12%
3	13	26%

Score '0' was given to the 1% ASLs.Score 1 was given to 60% cases,score 2 to 12% cases and score 3 to 13%

cases. Score 0 and 1 were counted as negative and score 2and 3 were as positive cases.

**Table 6: Ki-67 Staining results.**

Results	No. of Patients	% of Patients
Positive	19	38%
Negative	31	62%

Above table shows that 38% cases were positive for Ki-67 staining while 62% cases were negative.

**Table 7: Comparision between histopathological diagnosis and Ki-67 results.**

Case	Histopathdiagnosis	Ki-67 Results
Low Grade	32	31
High Grade	18	19

32 case were diagnosed low grade on histopathology and 18 cases were of high grade, while 31 cases were diagnosed as low grade (negative) and 19 case were of high grade (positive) on Ki-67 staining. It shows that there was 1false positive case and1 false negative case, diagnosed on Ki-67 staining considering histopathological diagnosis as 'gold standard'.

Out of 50 cases 36% cases were true positive and 60% cases were true negative on Ki-67 staining while 2%, 2% cases were showing false positive and false negative results respectively.

As our study is qualitative we will apply chi square test. Results are following-

Chi square	-	41.868
P value	-	<0.001
Degree of freedom	-	1

**Statistical analysis in the present study**

Sensitivity-	94.7%
Spesificity-	96.7%
Positive predictive value-	94.7%
Negative predictive value-	96.7%
Accuracy-	96%

## Discussion

There are many borderline lesions histological, biologically, and clinically in the uterine cervix, including relatively newly proposed categories, such as atypical immature metaplasia and transitional metaplasia, whose biologic and clinical characteristics are yet to be determined.

Also well known is the fact that there is substantial interobserver variance in the interpretation of histopathology findings of uterine cervical lesions. Using the loosely characterized diagnostic category of ASL in this already complicated field of uterine cervical pathology potentially might create further confusion. However many pathologist have been using the diagnosis of ASL for describing these borderline lesions in their routine practice.

In the present study we clearly demonstrate that ASL can be classified into 2 groups, neoplastic and nonneoplastic, based on their histologic and immunohistochemical features, as we strongly believe that clear distinction between neoplastic and nonneoplastic ASL is more valuable and clinically relevant than defining ASLs.

Using a reliable and sensitive immunohistochemical technique incorporating a well defined Rabbit monoclonal antibody, directed against a marker of proliferation Ki-67, this work has attempted to differentiate cervical intraepithelial neoplastic and benign lesions of cervix.

The present study is carried at the department of pathology, Mahatma Gandhi Medical College & Hospital, Sitapura, Jaipur (Rajasthan) to evaluate the Ki-67 marker in differentiating cervical intraepithelial lesions and benign lesions.

Present study comprises of 50 cases of ASLs of cervix.

Tam et al (at the 1998 United States and Canadian academy of pathology meeting) 49 reported a study of 47 cervical biopsies diagnosed as normal 20 and low grade intraepithelial lesions 27 and performed immunostain for MIB.

Our study has nearly the same number of cases as given in the above study. However Chisa Ayoma has done the similar study on 37 cases and Dr. Mehrotra Anju (Jobstet Gynecol India vol.58,no.4:July/August 2008)38 reported 153 cases for the same study.

The age ranges in our study from 35yrs to 80yrs.mean age is 45 yrs. accordingly we divided all the cases in to 2 groups, having the age <45 yrs and >45 yrs. similar to above study no correlation is found among the age, Histopathological diagnosis and Ki-67 grading.

In our study we included total 50 cases of ASLs of cervix. Out of 50 cases 28 were clinically diagnosed as benign and 22 as malignant ASLs.

In another study on 153 cases Dr. Mehrotra Anju divided the cases in to 4 groups according to histopathological diagnosis. These cases were normal (35), CIN (60), SCC (44) and non SCC (14). Similarly in our study we divided all the cases in to 6 groups on the basis of histopathological diagnosis. Out of 50 cases 7 (14%) cases were of chronic cervicitis, 10 (20%) cases of squamous metaplasia, 11 (22%) cases of epithelial hyperplasia, 11

(22%) cases of dysplasia, 4 (8%) cases of CA IN SITU and 7 (14%) cases of squamous cell carcinoma.<sup>1</sup>

Chisa Ayoma (2005) classified the cases into 2 categories based on the final diagnosis. Neoplastic (19 cases) and Non neoplastic (18 cases). The cases with the final diagnosis of high grade squamous intraepithelial lesions (HSIL; CIN2 or worse) were classified as neoplastic; cases with cytologic and histologic evaluations consistently revealed at most as CIN1/Low grade squamous intraepithelial lesions (LSIL) were classified as non neoplastic.<sup>11</sup>

Chisa Ayoma (2005) reported that Ki-67 positive nuclei were scattered and evenly distributed throughout the squamous epithelium of neoplastic ASLs. In contrast in non neoplastic ASLs they noted that only basal and parabasal cells in the uterine cervix were Ki-67 positive.<sup>11</sup>

Similarly in our study out of 47 cases 18 cases which were diagnosed high grade on Ki-67 staining were showing scattered pattern and evenly distributed throughout the epithelium. In 29 cases stained nuclei were limited to basal and parabasal layers of squamous epithelium. Out of 31 originally diagnosed benign cases 1 case showed no staining and 1 case was false positive. Out of 19 malignant cases 1 case was false negative.

Paul Liu, Chisa Ayoma (2005) recorded the presence or absence of mitosis (any mitosis normal or abnormal) in ASLs. It has proven to be one of the indicators of neoplastic ASL in this study. Although only abnormal mitotic figure were considered indicator of CIN in some reports. Similarly in our study out of 50 cases 46% patients showed abnormal mitosis. Findings of our study are keeping with the previous study.<sup>11</sup>

Milena panjkovic (2006)(12) assigned scores (P.I.) of 0-3 for Ki-67 stained section, with

Score 0=no staining

Score 1=weak positive; mount of positive cells are<10%

Score 2= positive; mount of positive cell are >10% but<50%

Score 3= strong positive; mount of positive cells are>50%

Score 0 and 1 were counted negative and score 2 & 3 were counted as positive cases. E. Ancuta, Codrina Ancuta (2009)(13) assigned proliferative index for Ki-67 stained section. It was evaluated using score 1 to 3 with

‘+’ meaning low proliferation; 10-30% positive cells

‘++’ meaning moderate proliferation; 30-50% positive cells

‘+++’ Meaning high proliferation ;> 50% positive cells

Dr. Mehrotra Anju & Goel Madhu Mati (14) evaluated labeling index (proliferative index) for Ki-67 stained section. The study was quantitative and they measured intensity of MIB-1.intensities were graded on scale of 0-3 as;

0- negative

1- weak

2- moderate

3- intense.

Present study is similar to the study of Milena Panjkovic study.

In our study 2% patients were showing no (0) stained nuclei, 60% were showing <10%, 12% were showing between 10-50% and 26% were showing >50%.

Maeda et al<sup>15</sup> observed that Ki-67 positive cells increased with increasing grades of cervical lesions.

Mc Cluggage et al<sup>38</sup> also found that the number and distribution of Ki-67 positive cells increased with the grade of CIN lesion.

Gibbon et al<sup>16</sup> reported a change in the expression of MIB-1 from parabasal cells (normal and metaplastic epithelium) to intermediate (low grade SIL) and superficial layers (high grade SIL). In their opinion invasive carcinoma had highest labeling index than high grade dysplasia.

Our findings are also consistent with these studies. Our results showed that MIB-1 staining levels increased with the progression of lesion from non neoplastic ASLs through increasing grades of dysplasia to invasive carcinoma.

In our study out of 7 chronic cervicitis cases 4 cases showed Ki-67 stained nuclei in basal layer and 2 cases showed in basal and suprabasal layer. 1 case had no staining. 6 out of 10 cases of squamous metaplasia showed staining in basal layer and 4 cases showed in suprabasal layer. Out of 11 cases of epithelial hyperplasia 9 cases showed stained nuclei in suprabasal layer. In 1 case stained nuclei were stretched up to lower 1/3<sup>rd</sup> of epithelium but P.I. WAS <10%. In 1 case nuclei were seen up to lower 2/3<sup>rd</sup> of epithelium but abnormal mitosis was seen and nuclei were not evenly distributed max.% of stained nuclei was seen in basal and parabasal layer. Along with this many stain containing lymphocytes were also seen. So this case was considered as false positive case. 5 cases of mild Dysplasia were seen. In 4 cases stained nuclei were seen up to lower 1/3<sup>rd</sup> of epithelium while 1 case showed positivity up to parabasal layer but with abnormal mitosis.

All these cases were considered negative on Ki-67 because P.I. was <10%. In chronic cervicitis, squamous metaplasia and epithelial hyperplasia stained nuclei were limited up to basal and parabasal layer. In mild dysplasia nuclei were limited up to lower 1/3<sup>rd</sup>. No abnormal mitotic activity was seen except in few cases.

S.Payne(1996)<sup>17</sup> studied on 86 cervical biopsy specimen. (10 normal, 11 with koilocytic changes only, 12CIN1, 9CIN2 & 44CIN3). Cases were determined using microwave antigen retrieval and standard 3 step streptavidin biotin peroxide cytochemical technique incorporating the MIB-1 monoclonal antibody. Immunore activity was assessed as occupying either the lower 1/3<sup>rd</sup>, lower 2/3<sup>rd</sup> or all 3/3<sup>rd</sup> of the sq. epithelium. 10 Biopsy specimen were assigned the grade normal and displayed either no abnormality or merely physiological. Variants around of normal (chronic inflammation, metaplasia around the transformation zone or atrophy). In all 10, MIB-1 staining was limited to the lower 1/3<sup>rd</sup> of the ectocervix or transitional zone. Usually it comprised a layer 2-4 cells thick in the immediate suprabasal region. Both immature and mature metaplasia possessed a solely parabasal staining pattern. Out of 12 CIN1 cases in 11 cases MIB1 staining was confined to the lower 1/3<sup>rd</sup> but less regular in

comparison to normal. 1 case had Ki-67 positivity in both lower and middle 1/3<sup>rd</sup>. Findings of our study are consistent with the findings of the previous study.

In present study 19 cases showed positivity for Ki-67 staining. 4 cases were of moderate dysplasia, 6 were of severe dysplasia and the 7 cases were of squamous cell carcinoma. Out of 4 cases of moderate dysplasia in 2 cases stained nuclei were present in lower and middle 1/3<sup>rd</sup>. In other 2 cases nuclei were stretched into all 3 layers. Abnormal mitosis was seen in 6 cases of severe dysplasia. Stained nuclei were seen in lower, middle and upper 1/3<sup>rd</sup> of epithelium. The density of positivity was increased in this group. Dysplastic areas were sharply defined. In all cases of squamous cell carcinoma stained nuclei occupied full thickness as well as stroma. No much difference between CIN2 and CIN3 was seen clearly.

S.Payne<sup>17</sup> selected 44 cases of CIN3. In 32 cases Ki-67 immunoreactivity occupied the lower, middle and upper 1/3<sup>rd</sup> of the epithelium but in some (11 cases) only the lower and middle compartments were stained. The density of positivity was increased in the group with most cells in abnormal area staining. Dysplastic areas were sharply defined with neighboring normal areas.

Kruse et al (2001)<sup>18</sup> suggested that the distribution of Ki-67 positive cell was related with CIN grade but there overlap between CIN2 and CIN3 lesion like in our study.

Marko Mimica (2010)<sup>19</sup> studied on 106 cervical biopsies and concluded that the percentage of Ki-67 positive nuclei fell down in the lower 1/3<sup>rd</sup> and rose in the middle and upper 1/3<sup>rd</sup> layer of the epithelium according to the severity of the dysplasia.

Milana Panjkovic (2006)<sup>12</sup> studied on 45 cervical biopsies. He investigated distribution of Ki-67 positive nuclei through the cervical epithelial layer. Ki-67 positive cells were distributed only in the lower 1/3<sup>rd</sup> of the epithelial layer in CIN1 cases. 7 patients of CIN2 and 13 cases of CIN3 changes respectively had Ki-67 positive cells in the lower and middle 1/3<sup>rd</sup> of the epithelial layer while 3 (23.1%) and 10 (40%) of cases the same dysplastic changes had Ki-67 positive cells distributed in lower, middle and upper 1/3<sup>rd</sup> of the epithelium. No significant difference was seen in the Ki-67 positive cells between CIN2 and CIN3 cases while the difference was highly significant between patients with CIN1 and CIN2 epithelial changes. Our findings are consistent with the above studies.

Statistical analysis of Ki-67 results in our study is as follows.

Sensitivity=	94.7%
Specificity=	96.7%
Positive predictive value=	94.7%
Negative predictive value=	96.7%
Accuracy=	96%
P value=	<0.001
Chi square value=	41.868
Degree of freedom=	1

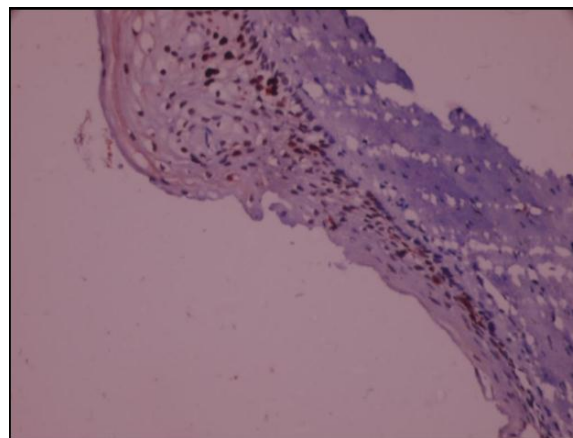
**Table 8: Comparison of the statistical analysis of Ki-67 marker results with the other studies.**

Studies	Sensitivity	Specificity	P value
Marko Miarica	98.4%	97.8%	<0.001
MilanaPanjkovic	-	-	<0.01
Fatemeh sari Aslani	95.6%	85.1%	<0.001

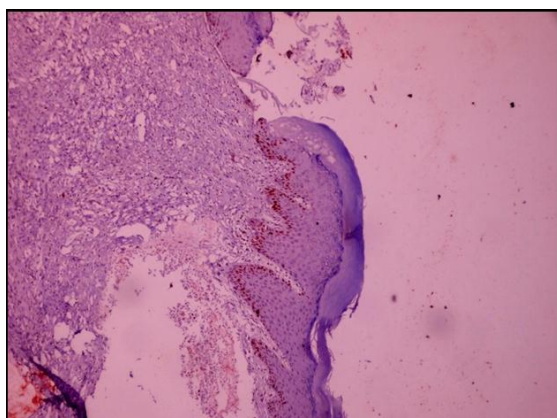
Present study shows the almost similar results with that of the above studies. Now it has been clearly evident that there is statistically significant relation between proliferative activity, distribution of Ki-67 positive cells and CIN grade.

Ki-67 expression has been found to be associated with the grade of dysplasia, indicating that IHC for Ki-67 is a useful adjunctive test in the evaluation of low grade lesion of the cervix.

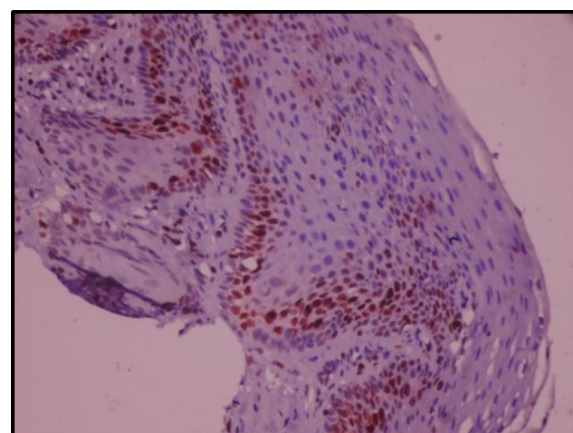
Hence Ki-67 could be a tool to differentiate between neoplastic and non neoplastic ASLs, to identify women who are at risk for progression and/or recurrence of cervical sq. precancerous lesions and to avoid overtreatment of false positive and under treatment of false negative cases



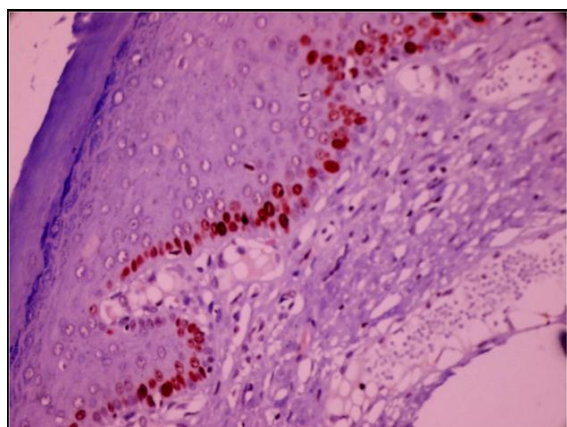
**Fig. 3: Squamous metaplasia in atrophic epithelium showing stained nuclei in full thickness of epithelial layer (40x).**



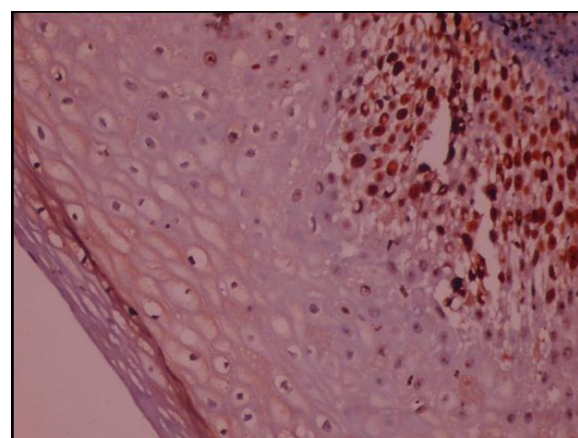
**Fig. 1: Chronic cervicitis, showing stained nuclei in the supra basal layer (10x).**



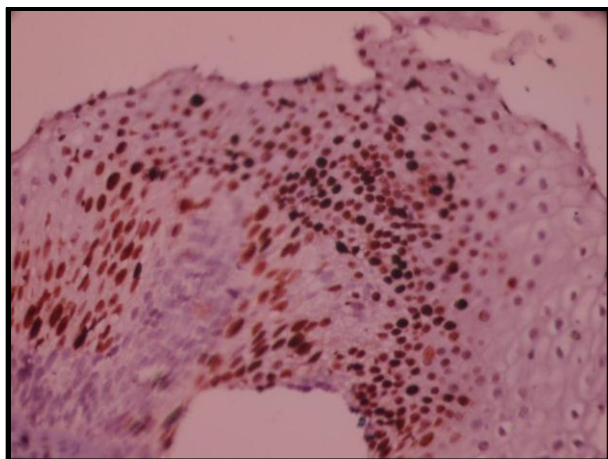
**Fig. 4: Epithelial hyperplasia, stained nuclei are seen in supra basal layer (40x).**



**Fig. 2: Chronic cervicitis showing stained nuclei in suprabasal layer (40x).**



**Fig. 5: CIN-1 stained nuclei are diffuse and involving lower 1/3<sup>rd</sup> of epithelial layer (40x).**



**Fig. 6:** CIN-2 stained nuclei are seen up to lower 2/3<sup>rd</sup> of epithelial layer ( 40x).

### Conclusion

The present study shows that there is statistically significant positive relation between proliferative activity, distribution of Ki-67 positive cells and increasing CIN grade.

Ki-67 staining is highly predictive and it can differentiate reactive cervical lesion from cervical dysplasia.

The assessment of cell proliferation with MIB-1 is useful and less expensive in comparison to other techniques like Thymidine and bromodeoxyuridine labeling quantitation of cellular DNA, which are more expensive and cannot be used in routine diagnostic practice. MIB-1, can be used as an independent discriminant of progression and biological behavior of CIN lesion irrespective of age and menopausal status.

**Conflicts of Interest:** None.

### References

1. Srivastava S, editor. Intraepithelial Neoplasia. InTech; 2012.
2. Jemal A, Bray F, Center MM, Ferlay J, Ward E, Forman D. Global cancer statistics. *CA Cancer J Clin* 2011 Mar;61(2):69–90.
3. KOTTMEIER, HL. Classification and staging of malignant tumors in the female pelvis. *Int J Gynecol Obstet* 1971;9:172.
4. Sherman ME, Schiffman MH, Lorincz AT, Manos MM, Scott DR, Kuman RJ, et al. Toward objective quality assurance in cervical cytopathology. Correlation of cytopathologic diagnoses with detection of high-risk human papillomavirus types. *Am J Clin Pathol* 1994 Aug;102(2):182–187.
5. Arbyn M, Bergeron C, Klinkhamer P, Martin-Hirsch P, Siebers AG, Bulten J. Liquid compared with conventional cervical cytology: a systematic review and meta-analysis. *Obstet Gynecol* 2008 Jan;111(1):167–177.
6. Stoler MH, Schiffman M, Atypical Squamous Cells of Undetermined Significance-Low-grade Squamous

- Intraepithelial Lesion Triage Study (ALTS) Group. Interobserver reproducibility of cervical cytologic and histologic interpretations: realistic estimates from the ASCUS-LSIL Triage Study. *JAMA* 2001 Mar 21;285(11):1500–1505.
7. focus\_nov\_2002.pdf. Available from: [http://www.ihcworld.com/\\_newsletter/2002/focus\\_nov\\_2002.pdf](http://www.ihcworld.com/_newsletter/2002/focus_nov_2002.pdf)
8. Buckley CH, Butler EB, Fox H. Cervical intraepithelial neoplasia. *J Clin Pathol*. 1982 Jan;35(1):1–13.
9. Kalof AN, Cooper K. Our approach to squamous intraepithelial lesions of the uterine cervix. *J Clin Pathol* 2007 May;60(5):449–55.
10. Sari Aslani F, Safaei A, Pourjabali M, Momtahan M. Evaluation of Ki67, p16 and CK17 Markers in Differentiating Cervical Intraepithelial Neoplasia and Benign Lesions. *Iran J Med Sci* 2013 Mar;38(1):15–21.
11. Aoyama C, Liu P, Ostrzega N, Holschneider CH. Histologic and immunohistochemical characteristics of neoplastic and nonneoplastic subgroups of atypical squamous lesions of the uterine cervix. *Am J Clin Pathol* 2005 May;123(5):699–706.
12. PanjkoviÊ M, IvkoviÊ-Kapicl T. Ki-67 expression in squamous intraepithelial lesions of the uterine cervix. *Arch Oncol* 2006;14(1-2):23–25.
13. Ancuța E, Ancuța C, Cozma LG, Iordache C, Anghelache-Lupașcu I, Anton E, et al. Tumor biomarkers in cervical cancer: focus on Ki-67 proliferation factor and E-cadherin expression. *Rom J Morphol Embryol* 2009;50(3):413–418.
14. Goel MM, Mehrotra A, Singh U, Gupta HP, Misra JS. MIB-1 and PCNA immunostaining as a diagnostic adjunct to cervical Pap smear. *Diagn Cytopathol* 2005 Jul;33(1):15–19.
15. Maeda MY, Simões M, Wakamatsu A, Longatto Filho AL, Oyafuso M, de Mello ES, et al. Relevance of the rates of PCNA, Ki-67 and p53 expression according to the epithelial compartment in cervical lesions. *Pathologica* 2001 Jun;93(3):189–195.
16. Gibbons D, Fogt F, Kasznica J, Holden J, Nikulasson S. Comparison of topoisomerase II alpha and MIB-1 expression in uterine cervical squamous lesions. *Mod Pathol* 1997 May;10(5):409–13.
17. Payne S, Kernohan NM, Walker F. Proliferation in the normal cervix and in preinvasive cervical lesions. *J Clin Pathol* 1996 Aug;49(8):667–671.
18. Kruse AJ, Baak JPA, de Bruin PC, Jiwa M. Ki-67 immunoquantitation in cervical intraepithelial neoplasia (CIN): a sensitive marker for grading. of pathology [Internet]. 2001; Available from: [https://onlinelibrary.wiley.com/doi/abs/10.1002/1096-9896\(2000\)9999:9999%3C::AID-PATH719%3E3.0.CO;2-E](https://onlinelibrary.wiley.com/doi/abs/10.1002/1096-9896(2000)9999:9999%3C::AID-PATH719%3E3.0.CO;2-E)
19. Mimica M, Tomić S, Kardum G, Hofman ID, Kaliterna V, Pejkić L. Ki-67 quantitative evaluation as a marker of cervical intraepithelial neoplasia and human papillomavirus infection. *Int J Gynecol Cancer* 2010 Jan;20(1):116–169.

**How to cite this article:** Bharadwaj M, Sharma N, Nag BP, Yadav ML, Evaluation of Ki-67 marker in differentiating cervical intraepithelial neoplasia and benign lesions: A study of 50 cases. *Arch Cytol Histopathol Res* 2019;4(1):11-18