

Histopathological study of distribution of non-Neoplastic and neoplastic lesions in intestinal lesions

Pooja Patel^{1*}, Jignasa Bhalodia²

¹Resident Doctor, ²Professor and HOD, Dept. of Pathology, GMERS Medical College and Hospital, Sola, Ahmedabad, Gujarat, India

*Corresponding Author: Pooja Patel

Email: drpooja109@gmail.com

Abstract

Introduction: The small and large intestine account for the majority of GI tract. They are the sites of a broad array of diseases. These include both neoplastic and non-neoplastic, such as inflammatory lesions, polyps, cancerous growths. Colorectal cancer is the fourth ranking cancer worldwide, accounting for approximately 9% of all cancers. This study was conducted to study histopathological spectrum of lesions in intestine and their age and sex distribution.

Materials and Methods: It was a retrospective study conducted in the Department of Pathology, GMERS Medical College and Civil Hospital, Sola, Ahmedabad from January 2018 to December 2018. The specimens included were endoscopic biopsies as well as resections of colon and part of intestine.

Results: Total 131 intestinal specimens were received in our hospital over the period of January 2018 to December 2018. Overall non neoplastic lesions (87.8%) were more common than neoplastic lesions (12.2%). Most common non neoplastic lesion in small intestine was peptic ulcer and in large intestine was fistula. In large intestine, most common neoplastic lesion was adenocarcinoma.

Conclusion: This study concludes that a variety of lesions occur in small and large intestine which have a vague presentation. Timely histopathological diagnosis and its clinical correlation help in early management and improve the survival.

Keywords: Intestinal lesions, small intestine, large intestine, neoplastic, non-neoplastic, adenocarcinoma, malignant melanoma

Introduction

The small intestine and large intestine account for the majority of GI tract.¹ They are the sites of a broad array of diseases.² These include both neoplastic and non neoplastic, such as inflammatory lesions, polyps, cancerous growths, with some of the inflammatory lesions being premalignant. Epithelial tumors are major cause of morbidity & mortality. Colorectal cancer is the fourth ranking cancer worldwide, accounting for approximately 9% of all cancers.² Adenocarcinomas are the commonest malignancies arising in the colorectal region, other being carcinoid, anal zone carcinoma & melanoma.³ This study was conducted to study histopathological spectrum of lesions in intestine and their age and sex distribution.

Materials and Methods

Specimens from small and large intestines were included in the study. The study period was from January 2018 to December 2018. It was a retrospective study conducted in the Department of Pathology, GMERS Medical College and Civil Hospital, Sola, Ahmedabad. The specimens included were endoscopic biopsies as well as resections of colon and part of intestine. The biopsies received were fixed in 10% buffered formalin and processed in an automated processor. The paraffin embedded sections were taken and stained with Hematoxylin and Eosin. Special stains like Giemsa, Zeihl Neelson, Fite Faraco, Alcian blue and Periodic Acid Schiff stains were used as and when necessary.

Results

Total 131 intestinal specimens were received in our hospital over the period of January 2018 to December 2018. The site wise distribution is shown in Table: 1. Large intestinal

lesions (71.8%) were more common than small intestinal lesions (28.2%).

As shown in Table: 2; out of total specimens 77.8% were of males and 22.2% of females.

As shown in Table: 3; non-neoplastic lesions are more common in both small and large intestines. Overall non-neoplastic lesions (87.8%) were more common than neoplastic lesions (12.2%).

Table: 4 shows histopathological distribution of non neoplastic intestinal lesions. Most common non-neoplastic lesion in small intestine was peptic ulcer and in large intestine was fistula.

Out of neoplastic lesions, 12 were malignant and 4 were benign as shown in Table: 5.

As shown in Table: 6; in large intestine, most common neoplastic lesion was adenocarcinoma.

Table 1: Site wise distribution of intestinal specimens

Site of lesion	No. of biopsies
Small intestine	37(28.2%)
Large intestine	94(71.8%)

Table 2: Sex wise distribution of intestinal specimens

Sex	Number
Male	102(77.8%)
Female	29(22.2%)

Table 3: Distribution of specimens according to nature of lesion

Site	Non neoplastic	Neoplastic
Small intestine	36	1
Large intestine	79	15
Total	115(87.8%)	16(12.2%)

Table 4: Distribution of non neoplastic intestinal lesions according to histopathology

Site	Lesion	number
Small Intestine	Peptic ulcer	11
	Acute infarction	4
	Acute necrotizing inflammation	4
	Acute suppurative inflammation	1
	Acute on chronic enteritis	2
	Gangrene	5
	Tuberculosis	3
	Diverticulosis	1
	Intussusception	1
	Meckel's diverticulum	1
	Necrotizing granulomatous inflammation	1
	Congestion	1
	Strangulated hernia	1
	Large Intestine	Fistula
Hemorrhoids		17
Nonspecific inflammation		4
Acute colitis		2
Amoebic colitis		2
Acute necrotizing enterocolitis		3
Granulomatous inflammation		2
Tuberculosis		1
Bacterial colitis		1
No result	1	
Total		115

Table 5: Distribution of neoplastic intestinal lesions according to nature

Nature of neoplastic lesion	No. of cases
Benign	4
Malignant	12

Table 6: Distribution of neoplastic intestinal lesions according to histopathology

Site	Lesion	Number
Small intestine	Squamous cell carcinoma	1
Large intestine	Condyloma acuminata	2
	Dysplasia	2
	Squamous cell carcinoma	1
	Adenocarcinoma	9
	Malignant melanoma	1
Total		16

Table 7: comparison of distribution of histologic types of adenocarcinoma

Histologic type	Our study	Ritesh et al. ³
Well differentiated adenocarcinoma	5(55.56%)	11(18.03%)
Moderately differentiated adenocarcinoma	3(33.33%)	35(57.37%)
Poorly differentiated adenocarcinoma	0(0%)	1(1.64%)
Mucinous adenocarcinoma	1(11.11%)	11(18.02%)
Signet ring cell adenocarcinoma	0(0%)	3(4.92%)
Total	9(100%)	61(100%)

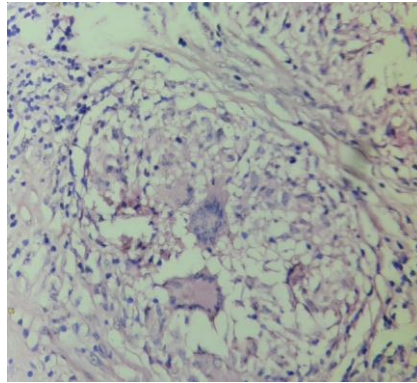


Fig. 1: (a) shows caseating granuloma with Langhans giant cells surrounded by rim of lymphocytes on Hematoxylin and Eosin stain.

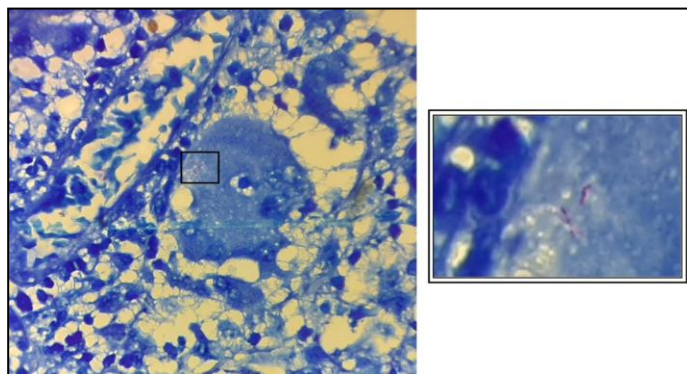


Fig. 1: (b) shows acid fast bacilli on Zeihl-Neelson stain

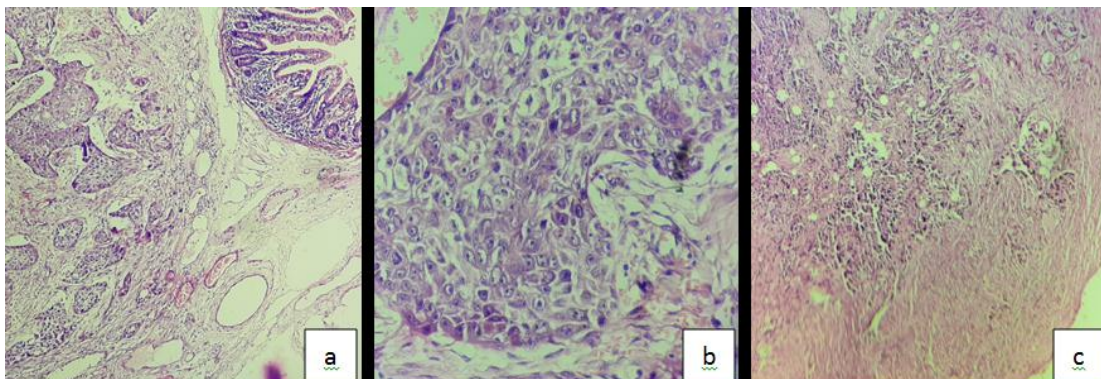


Fig. 2: (a), (b) and (c): (a) shows nests of squamous cell carcinoma in submucosal area on low power view (10x); (b) shows nest of dysplastic squamous cells on high power view (40x); (c) shows metastasis in lymph node

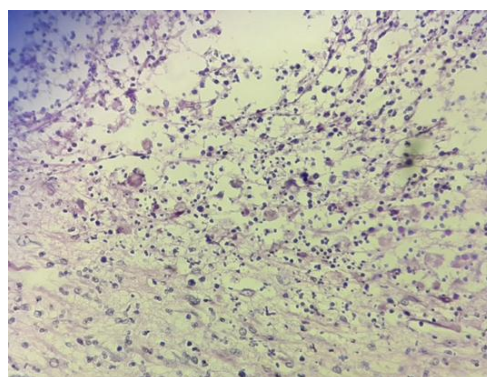


Fig. 3: PAS stained section shows round to oval shaped trophozoites of Entameba Histolytica present in necrotic debris

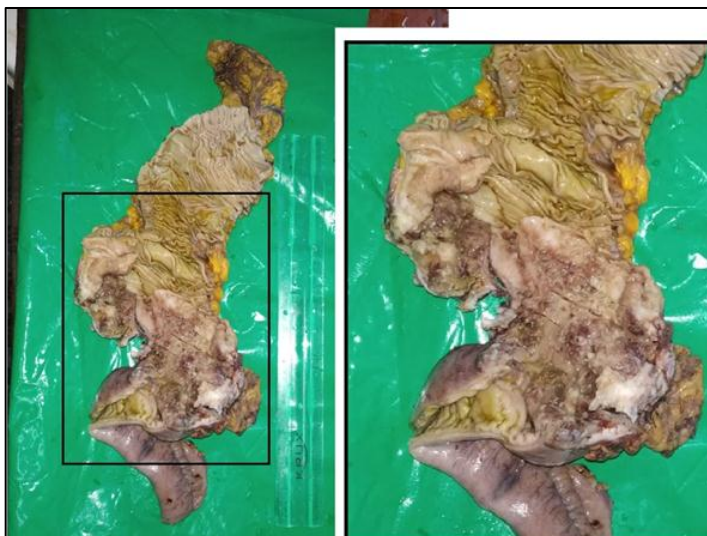


Fig. 4: (a): gross appearance of mucinous adenocarcinoma of colon presenting as ulcero-infiltrative grayish white mass with cystic areas filled with mucin

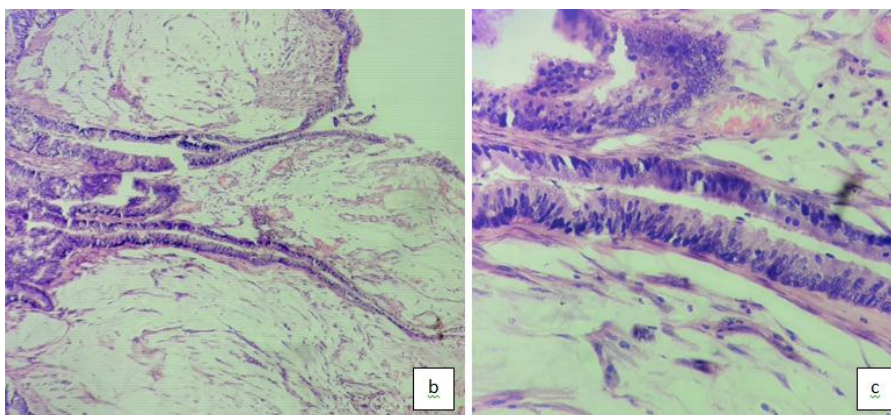


Fig. 4: (b) and (c) show microscopic picture of mucinous adenocarcinoma: large mucin lakes with malignant epithelial cells forming glands

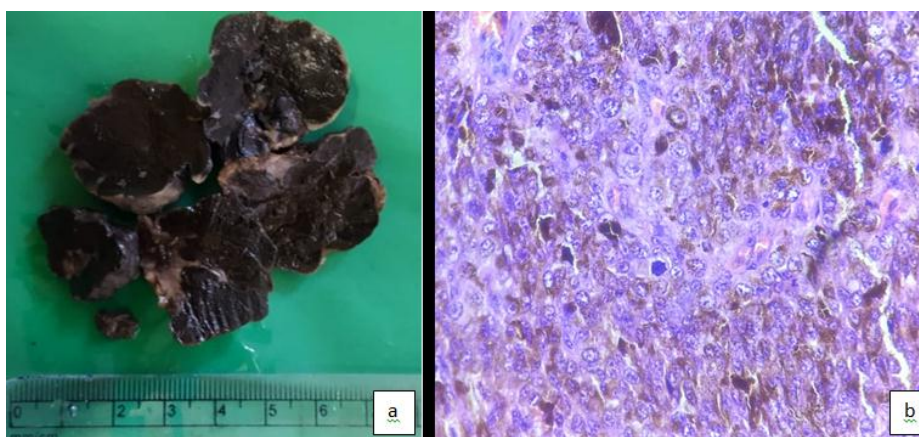


Fig. 5: (a) and (b): (a) shows polypoid mass with blackish cut surface; (b) malignant epithelioid cells with abundant melanin pigment in cytoplasm

Discussion

A total of 131 cases of intestinal lesions were studied over a period of one year from January 2018 to December 2018. Among them, there were 115 cases of non neoplastic lesions

and 16 cases of neoplastic lesions. Amongst the non neoplastic lesions, most common lesion was fistula accounting for 40%.

Of 16 cases of neoplastic lesions, 12 cases were of malignant neoplasms on histopathological examination, 4 cases of benign neoplasms. It was observed that, out of 142 malignant lesions of all sites in the body, 12 cases were of intestinal malignancies, thus constituting 8.45% of all malignant lesions during the study period.

Lesions of Small Intestine

Most common lesion diagnosed was peptic ulcer. There were 3 cases of tuberculosis all involving terminal ileum. In one, perforation was present. Tuberculous granulomas are caseating in nature and have peripheral infiltration containing lymphocytes, plasma cells and Langhans type of giant cells.⁴ Acid fast bacilli were demonstrated on Zeihl – Neelson stain. Fig. 1 (a) and (b) show tuberculous granuloma in H & E stain and Acid fast bacilli in ZN stain. Squamous cell carcinoma was detected in resected intestine with metastasis in mesenteric lymph node. Mucosa was free from tumor. Later on it was found to be metastatic from other site. Fig. 2 (a), (b) and (c) show histomorphology of SCC on low power and high power view and metastatic foci in lymph node.

Lesions of Large Intestine

Most common diagnosis given was fistula followed by hemorrhoids. Tuberculosis was diagnosed in 1 case. 2 cases of amoebic colitis were recorded. Confirmation was done by demonstration of trophozoites of *Entamoeba histolytica* by Periodic acid-Schiff (PAS) staining.⁵ As seen Fig. 3, trophozoites are round to ovoid with abundant cytoplasm and small round nuclei.

Total 11 malignant cases were reported. Out of them, 9 were of Adenocarcinoma, 1 of squamous cell carcinoma and 1 of malignant melanoma. Table: 7 shows comparison of distribution of histologic types of adenocarcinoma with study done by Ritesh et al. The results were in discordance with Ritesh et al.³ In our study most common type was well differentiated adenocarcinoma while in study done by Ritesh et al. most common was moderately differentiated one.

One case of mucinous carcinoma was reported. Fig. 4 (a),(b) and (c) show gross and microscopic features of mucinous adenocarcinoma of colon. Mucinous carcinoma presents as grayish white solid cystic exophytic mass reaching upto serosa. Cystic spaces were filled with mucin lakes. Microscopically mucinous foci constitute atleast 50% of tumor mass with malignant cells forming glands.⁵

One case of malignant melanoma was reported. Figure: V shows gross and microscopic features of malignant melanoma. It was received as a resected polypoid mass. Cut surface was brownish black. Microscopically it showed malignant epithelioid cells with some binucleated and multinucleated bizarre tumor giant cells. The epithelioid cells contain abundant melanin pigment in cytoplasm.⁶

Thus histopathological examination was useful in reaching the final diagnoses including rare lesions like mucinous adenocarcinoma, malignant melanoma, etc. Special stains were useful in identifying causative

organisms. Examples are: Zeihl Neelson stain for *M. tuberculosis* and Periodic Acid-Schiff stain for *E. Histolytica*.

Conclusion

This study concludes that a variety of lesions occur in small and large intestine which have a vague presentation. It makes their diagnosis difficult. Timely histopathological diagnosis and its clinical correlation help in early management and improve the survival.

Conflict of Interest: None.

References

1. Masgal M., Vaddadi V, Patil A, M Anita. Histopathological spectrum of intestinal lesions. *J Diagn Pathol Oncol* 2018; 3(4):330-34.
2. Nanavati MG., Parikh JH, Gamit KS. A Histopathological Study of Intestinal Lesions. *Int J Sci Res* 2014;3(9).
3. Ritesh Sulegaon, Smita Shete, Dinesh Kulkarni. Histological Spectrum of Large Intestinal Lesions with Clinicopathological Correlation. *J Clin Diagn Res* 20159(11):EC30-EC34.
4. H. D. Tandon, A. Prakash. Pathology of intestinal tuberculosis and its distinction from Crohn's disease. *Gut* 1972;13:260-69.
5. Rosai, J., Ackerman, L. V., & Rosai, J. Rosai and Ackerman's surgical pathology, 11th edition. Page: 662, 679. 2011.
6. Raja J, Hegde R, Srodon M. (October 26, 2017) A Case of Primary Melanoma of the Transverse Colon. *Cureus* 9(10): e1803. DOI 10.7759/cureus.1803

How to cite this article: Patel P, Bhalodia J. Histopathological study of distribution of non-Neoplastic and neoplastic lesions in intestinal lesions. *Arch Cytol Histopathol Res* 2019;4(2):138-42.