

Histomorphological study of changes in heart – An autopsy study

Shah Saloni N^{1*}, Patel Kinara A², Patel Himani B³, Bhalodia Jignasa N⁴

¹Resident Doctor, ²Associate Professor, ³Assistant Professor, ⁴Professor and HOD, ¹⁻⁴Dept. of Pathology, ¹⁻⁴GMERS Medical College and Civil Hospital, Sola, Ahmedabad, Gujarat, India

***Corresponding Author: Shah Saloni N**

Email: saloninshah2010@gmail.com

Abstract

Introduction and Objectives: During the last five decades an increasing trend is seen in incidence of cardiac deaths especially among urban population. As post-mortem analysis of heart is the sole way to study gross and histopathological changes in healthy or diseased heart, an autopsy study of heart was therefore planned to observe various histomorphological changes.

Materials and Methods: A prospective randomized study of 161 autopsies submitted for postmortem analysis was conducted in the Department of Pathology, GMERS Medical College and Civil Hospital, Sola over a period of one year from January 2018 to December 2018. Out of 161 autopsies, specimen of heart was received in 159 autopsies, out of which 7 were autolysed. Hence, 152 specimen of whole heart were included in our study. The specimens of whole heart were examined for gross appearance and microscopic section were studied to observe various histomorphological changes and findings were correlated clinically.

Results and Conclusions: Among sudden deaths, coronary atherosclerosis was found to be the most common pathogenic factor leading to ischemic heart disease. Also, three vessel involvement was the most common pattern in coronary atherosclerosis. Hence, thorough examination of cardiovascular system is necessary in case of autopsy to reach to cause of death.

Keywords: Autopsy, Coronaries, Heart, Histology, Morphology.

Introduction

During the last five decades an increasing trend is seen in incidence of cardiac deaths especially among urban population. In India incidence of ischemic heart disease has increased to about 10 percent.^{1,2} The occurrence of sudden death presents a great challenge to the general autopsy pathologist and as cardiac autopsy is the main diagnostic tool to study various histomorphological changes in normal and diseased heart, an autopsy study of heart was undertaken to establish the cause and nature of death, to determine the frequency of acute coronary lesions in sudden cardiac death.³ As revealed in autopsy findings, majority of sudden and unexpected deaths result as a sequel to cardiovascular disease.⁴ It has been observed that in many instances gross pathology alone could not help to decide the cause of death, histopathology can conclusively opine the involved cardiac pathology.⁵ Hence this study was done to study various histomorphological changes in autopsied heart specimens and also to study association of acute coronary events with myocardial infarction.

Materials and Methods

We conducted a prospective randomized study on 161 autopsy specimen submitted for postmortem analysis in Department of Pathology, GMERS Medical College and Civil Hospital, Sola over a period of one year from January 2018 to December 2018. Out of total 161 autopsies received, specimen of whole heart was received in 159 autopsies, out of which 7 were autolysed. Hence, 152 autopsy cases were included in our study.

Gross Examination

Formalin fixed specimens were inspected externally, weighed and then dissected by inflow outflow method of cardiac dissection. Whenever required, short axis method was followed.⁶ The heart was weighed after removal of extraneous vessels and residual postmortem blood clot. The external surface was examined for any visible pathology and areas of myocardial infarction were noted i.e. whether recent or old. Measurement of thickness of right ventricular wall, left ventricular wall and interventricular septum were done. The valves were examined for stenosis and calcification. Areas of myocardial ischaemia (whether recent or old) were noted, and their location and sizes were recorded. All the three coronary arteries i.e. right coronary artery, left anterior descending artery and left circumflex coronary artery were examined using sections at regular intervals of 4-5mm. The ascending aorta was checked for dilatation, thickening or atheromatous plaque.

Microscopic Examination

Sections were taken from right and left ventricular wall, interventricular septum, apex, right and left coronary arteries (both branches) and stump of aorta. Additional sections were taken wherever necessary. Tissues were processed and subjected to paraffin section at 4 µm thickness, and then were stained with routine hematoxylin and eosin staining method.^{7,8}

Results were analyzed using Epi Info software (SPSS) in Microsoft Excel. Chi-square test and p-value <0.05 was considered significant.

Results

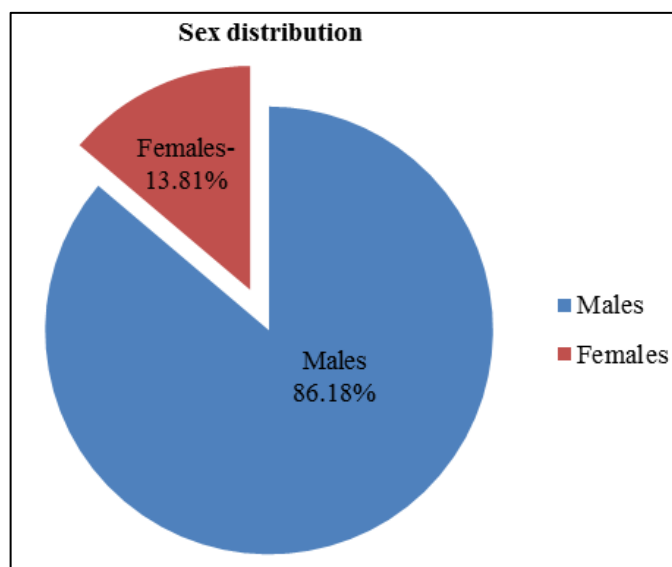


Fig. 1: Sex distribution of Cases

Table 1: Age wise distribution of cases

| Age | No. of cases |
|--------|--------------|
| 0- 10 | 01 (0.65%) |
| 11- 20 | 14 (9.21%) |
| 21- 30 | 26 (17.10%) |
| 31- 40 | 25 (16.44%) |
| 41- 50 | 29 (19.07%) |
| 51- 60 | 32 (21.05%) |
| 61- 70 | 22 (14.47%) |
| 71-80 | 02 (1.31%) |
| 81-90 | 01 (0.65%) |
| 91-100 | 00 (0.0%) |

Table 2: Morphological changes in heart according to age group distribution

| Age (Years) | Morphological Changes in Heart | | | | | |
|-------------|--------------------------------|---------|----------|--------------------------|------------|-------------|
| | Normal | Old MI* | Acute MI | Coronary atherosclerosis | Congestion | Hypertrophy |
| 0 - 10 | 1 | 0 | 0 | 0 | 0 | 0 |
| 11- 20 | 8 | 0 | 0 | 0 | 2 | 4 |
| 21 - 30 | 12 | 3 | 4 | 7 | 3 | 4 |
| 31- 40 | 9 | 5 | 4 | 12 | 4 | 3 |
| 41- 50 | 9 | 4 | 11 | 26 | 5 | 0 |
| 51- 60 | 8 | 8 | 13 | 30 | 0 | 3 |
| 61- 70 | 4 | 9 | 4 | 15 | 0 | 5 |
| 71- 80 | 0 | 1 | 1 | 2 | 0 | 0 |
| 81-90 | 0 | 0 | 0 | 1 | 0 | 1 |
| 91- 100 | 0 | 0 | 0 | 0 | 0 | 0 |
| Total | 51 | 30 | 37 | 93 | 14 | 20 |

*MI, Myocardial Infraction.

Figure 1 and Table 1 summaries sex and age distribution of cases respectively.

Out of 152 autopsy, 141(92.76%) were of males and 11(7.24%) were of females (Fig. 1). Our study included cases of age between 0- 90 years. In present study, it was observed that maximum number of cases were seen in age group of 51- 60 years i.e. 32 (21.05%). (Table 1).

Table 2 shows various morphological changes seen in heart according to age distribution. In histomorphological evaluation, most common finding was coronary atherosclerosis, followed by acute and old myocardial infarction (Ischemic Heart Disease). In 51(33.55%) cases, normal histology of myocardium was noted. (Table 2)

Table 3: Changes in coronaries

| Coronary artery | Mild AS [§] | Moderate AS | Severe AS | Calcification | Thrombus | Critical narrowing |
|------------------|----------------------|-------------|-----------|---------------|----------|--------------------|
| RCA [*] | 15 | 11 | 29 | 15 | 3 | 2 |
| LCA [†] | 14 | 12 | 34 | 17 | 4 | 5 |
| LAD [‡] | 13 | 11 | 36 | 16 | 3 | 6 |

*RCA, Right Coronary Artery; †LCA, Left Coronary Artery; ‡LAD, Left Anterior Descending; §AS, Atherosclerosis. Table -3 demonstrates changes noted in coronary arteries.

Out of the three coronary arteries, severe atherosclerosis was seen most commonly in left anterior descending artery (LAD) (38.70%) followed by left coronary artery (LCA) (36.56%) and right coronary artery (RCA) (31.18%). Secondary changes in coronary artery like calcification, thrombus formation, critical narrowing of lumen etc were more commonly seen in left coronary artery followed by left anterior descending artery and right coronary artery.(Table 3)

Table 4: Frequency distribution of areas involved in ischemic heart disease (IHD)

| Walls Affected | Acute MI [§] | Old / Healed MI |
|-----------------------------|-----------------------|-----------------|
| Only RV [*] | 0 | 0 |
| Only LV [†] | 3 (8.10%) | 0 |
| Only IV [‡] Septum | 0 | 2 (6.67%) |
| LV and IVS | 12 (32.43%) | 2 (6.67%) |
| Apex | 1 (2.70%) | 6 (20%) |
| Apex and IVS | 2 (5.40%) | 2 (6.67%) |
| All | 19 (51.35%) | 18 (60%) |

*RV, Right Ventricle; †LV, Left Ventricle; ‡IV, Interventricular ; §MI, Myocardial Infarction.

Table-4 summarizes the frequency distribution of areas involved in Ischemic Heart Disease.

In the present study, it was observed that most common pattern of involvement in IHD was diffuse i.e. involvement of all the areas of left ventricular wall, interventricular septum and apex (55.22%) followed by involvement of left ventricular wall and septal wall (20.89%) (Table 4).

A significant association was found between increasing age and incidence of ischemic heart disease and also between coronary atherosclerosis and myocardial infarction ($p < 0.05$).

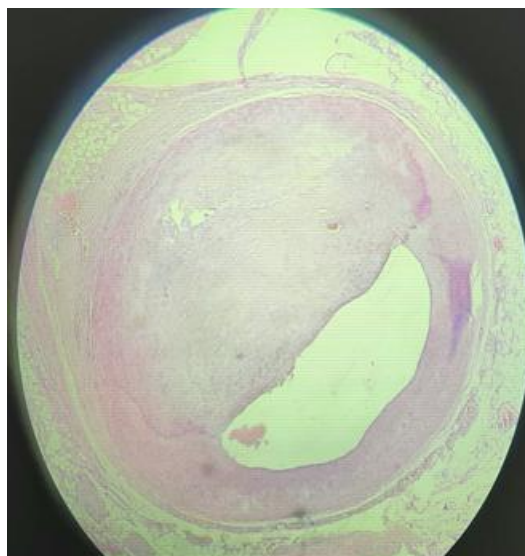


Fig. 2: Photomicrograph showing intimal thickening in severe atherosclerosis with critical narrowing of lumen (H & E, 40X)

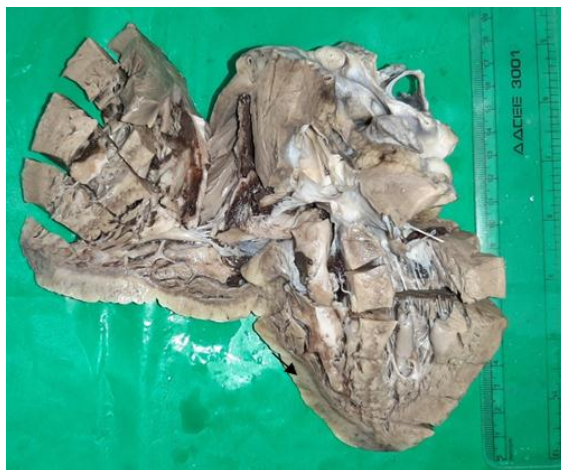

Fig. 3: Gross appearance of myocardial ischemia showing whitish mottled patch in left ventricular wall.

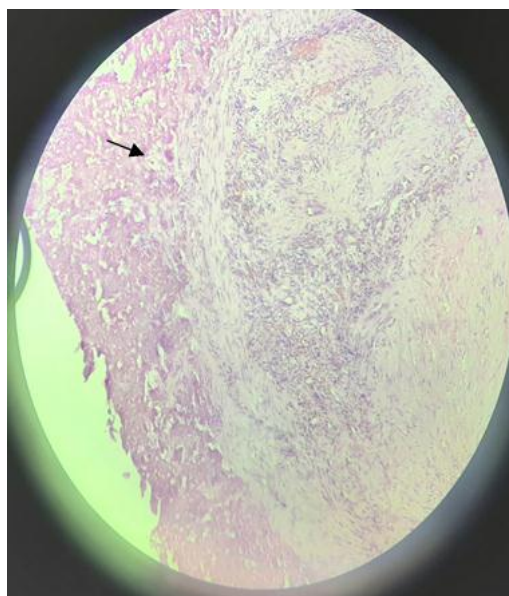


Fig. 4: Photomicrograph of granulation tissue and loose collagen in old myocardial infarction (→) (H&E, 40X)

Discussion

Keeping in mind the main aim of the autopsy pathologist i.e. to help reach the cause of death and cardiovascular causes being the most common one as mentioned in literature, the cardiac autopsies were performed with the aim to observe histomorphological changes that could guide to the cause of death especially when there is history of no specific disease or co-morbidities. In the present study, it was observed that out of total 152 autopsy studied, 141 were male (92.76%) and 11 were female (7.24%) with maximum number of cases in 51- 60 year age group. Many studies on sudden death conducted by Farb A, Thomas A, Chugh SS and others also revealed same proportion indicating that sudden natural death from all causes (cardiac and non cardiac) was more common in men.⁹⁻¹¹

In this study, most common histomorphological finding observed was coronary atherosclerosis i.e. 93(61.18%) which is comparable to other studies done by Chandrakala Joshi et al (64%) and Garg S et al (55.3%).^{12,13} Secondary

changes like calcification was present in 48(51.61%) and thrombus formation in 10(10.75%) which is comparable to study by Garg S et al that showed calcification in 53.3% of cases and Marwah Nisha et al that observed thrombosis in 7.5% of cases.^{11,13} In terms of frequency of involvement, LAD (38.70%) was observed to have a higher severe atherosclerosis than RCA. Gradwohl quoted the ranges from various published analysis as LAD to be 45-64%, while RCA come next in frequency, 24-46% followed by left circumflex 3-10%, and least affected in left main coronary.¹⁴

In cases of ischemic heart disease, we tried to find out the frequency distribution of various areas involved by examining atleast one section each from LVW, RVW, IVS and apex. 37 of the 67 cases (55.22%) of IHD had involvement of all the areas followed by involvement of left ventricular wall and interventricular septum (20.89%). Isolated involvement of RVW was not seen. Our results

were in accordance to those well documented in literature.^{2,15}

In the end, we tried to correlate the pathological changes with alleged cause of death (COD), if mentioned, and to find out the probable cause of death in cases of sudden death with no known cause. The histopathological changes of ischemic heart disease correlated in many cases with the alleged COD mentioned in police papers e.g. heart attack, chest pain or cardiac arrest. There were more chances to get the features of MI if patient presented with heart attack/ chest pain. Features of chronic IHD associated with coronary atherosclerosis were found in many cases with some other alleged COD e.g. accident, drug abuse or some chronic illness like diabetes, indicating that their could just be a precipitating factor over the underlying diseased heart.

Limitations

In the present study, post-mortem investigation to detect myocardial infraction like three Tesla Magnetic Resonance Imaging (3T-MRI), Histochemical staining by triphenyl tertazolium chloride and quantitative myoglobin assay were not done to reach to the cause of death due to lack of such sophisticated instruments.

Conclusions

Present study analyzed histomorphological changes in autopsied heart in different age groups. The most common cause of death was found to be myocardial ischaemia due to atherosclerosis. Three vessel involvement was found to be the most common pattern. Also, it was seen that incidence of Ischemic Heart Diseases are more common in males and its incidence increases with increasing age.

Thus, in case of autopsy, cardiovascular system should be carefully examined to reach the cause of death.

Conflict of Interest: None.

References

1. Goldberger JJ, Basu A, Boineau R . Risk stratification for sudden cardiac death a plan for the future. *Circ* 2014;129:516-26.
2. Frederick JS, Richard NM, The Heart. In: Vinay Kumar, editor. Robbins & Cotran Pathologic Basis of Disease: South Asia Edition. Vol I , 9th edn. New Delhi: Reed Elsevier India Private Limited; 2015.p.538-50.
3. Marwah N, Sethi B, Gupta S, Duhan A, Singh S, Sen R, et al. Histomorphological Spectrum of Various Cardiac Changes in Sudden Death: An Autopsy Study. *Iran J Pathol* 2011;6:179-86.
4. Reddy KS. Cardiovascular disease in non-Western countries. *N Engl J Med* 2004;350:2438-510.
5. Tabib A, Loire R, Chalabreysse L. Circumstances of death and gross and microscopic observations in a series of 200 cases of sudden death associated with arrhythmogenic right ventricular cardiomyopathy and/or dysplasia. *Circ* 2003;108:3000-5.
6. William DE. Cardiovascular System. In: Jurgen L, editor. Handbook of Autopsy Practice, 3rd edn. Totowa : Humana Press ; 2002.p.21-43.
7. Lena TS, John DB. Tissue Processing. In: Michael H, editor. Theory and Practice of Histological Techniques, 6th edn. Philadelphia : Churchill Livingstone ; 2011.p. 83-91.
8. Marilyn G. The Hematoxylin and Eosin. In: Michael H, editor. Theory and Practice of Histological Techniques, 6th edn. Philadelphia: Churchill Livingstone; 2011:121-32.
9. Farb A, Tang AL, Burke AP, Sessums L, Liang Y, Virmani R et al. Sudden coronary death. Frequency of active coronary lesions, inactive coronary lesions, and myocardial infarction. *Circ* 1995;92:1701-9.
10. Thomas AC, Knapman PA, Krikler DM, Davies MJ. Community study of the causes of natural sudden death. *BMJ* 1988;297:1453-6.
11. Chugh SS, Kelly KL, Titus JL. Sudden cardiac death with apparently normal heart. *Circulation* 2000;102:649-54.
12. Joshi C. Postmortem study of histopathological lesions of heart in cases of sudden death- an incidental finding. *J Evid Based Med Healthc* 2016;3:184-8.
13. Garg S, Hasija S, Sharma P, Kalhan S, Saini N, Khan A et al. A histopathological analysis of prevalence of various heart diseases: an autopsy study. *Int J Res Med Sci* 2018;6:1414-8.
14. Bohrod MG. The essentials of forensic medicine. *JAMA* 1986;255:1506-7.
15. Rao D, Sood D, Pathak P, Dongre SD. A cause of sudden cardiac deaths on autopsy findings: a four year report. *Emerg* 2014;2:12-7.

How to cite this article: Shah SN, Patel KA, Patel HB, Bhalodia JN. Histomorphological study of changes in heart – An autopsy study. *Arch Cytol Histopathol Res* 2019;4(2):159-63.