

Histopathological study of adenoid cystic carcinoma in lacrimal gland

Pratikkumar B Desai^{1*}, Ami Shah²

¹Assistant Professor, ²Associate Professor, ¹GMERS Medical College, Vadnagar, Gujarat, B J Medical College, Ahmedabad, Gujarat, India

*Corresponding Author: Pratikkumar B Desai

Email: pratik01desai@gmail.com

Abstract

Introduction: The lacrimal gland is secretory gland situated in the lacrimal gland fossa. Adenoid cystic carcinoma of lacrimal gland is most common malignant tumor of lacrimal gland and very crucial to differentiate between adenocystic carcinoma and pleomorphic adenoma of lacrimal gland because of different outcome.

Aims and Objectives: To study the incidence, histopathological pattern, and distribution into the age, sex of Adenoid cystic carcinoma in to the lacrimal gland.

Materials and Methods: A Retrospective study of 14 cases of Adenoid cystic carcinoma in lacrimal gland during period of 10 years were studied. A detailed history of patients were taken with special attention to the age, sex, macroscopic (gross examination) and microscopic features of tissue. Microscopic examination is done under standard H & E staining procedure.

Result and Conclusion: Total 57 cases of lacrimal gland tumor were studied among them 14 cases of adenoid cystic carcinoma, its most common malignant tumor of lacrimal gland. Its most common age for presentation is 4th to 6th decade, and most common histological pattern present in mixed pattern. And its incidence are slightly more common in female. Other detail discussed in to the result and discussion section.

Keywords: Adenoid cystic carcinoma, Lacrimal gland, Histological patterns, Age, Sex.

Introduction

Lacrimal gland is secretory gland situated in the lacrimal gland Foss, behind the supraorbital rim. Histologically, the lacrimal gland is divided into acini and ducts. Individual acini and lobules of acini are separated from each other by interlobular and intralobular connective tissue.¹ Adenoid cystic carcinoma is an infiltrative, highly malignant epithelial tumor of lacrimal gland. It has been suggested that this tumor arise from intralobular duct cells at the transition zone between the acini and the ducts.² Structure of lacrimal gland is similar to the lacrimal gland so for the classification of lacrimal gland malignant tumor is done according to the WHO classification of salivary gland malignant tumor.³ Approximately 25 % of primary epithelial tumor of the lacrimal gland is adenoid cystic carcinoma.⁴ Adenoid cystic carcinoma is the second most common epithelial tumor after pleomorphic adenoma and the most common malignant epithelial tumor of the lacrimal gland.⁵ Mortality in to the adenoid cystic carcinoma of lacrimal gland is due to the blood borne spread to the lung and adjuvant direct invasion into the cranial cavity.⁴ The common age for presentation of tumor is after 40s or 50s of life.⁶⁻⁷ Adenoid cystic carcinoma is very rare in to the children and adolescents. Clinically patient present with a short history of pain, numbness, ptosis, motility disturbance and diplopia. Grossly, the tumor is globular, round appearance and deceptively circumscribe. On cross section Greyish white surface is seen. Microscopically, Adenoid cystic carcinoma is characterized by aggregates or cord like arrangement of neoplastic cells with cystic spaces that contain mucinous material. Hyalinised stroma maybe separate elongated cords. Adenoid cystic carcinoma of lacrimal gland tumor displays many microscopic architectural patterns like: Basaloid or solid, comedo carcinoma, sclerosing "cylindromatous carcinoma", cribriform, Swiss chess pattern and tubular or ductal. Most

commonly there is an admixture of more than 2 or 2 pattern are seen.⁸ Adenoid cystic carcinoma of the lacrimal gland shows ultrastructurally 3 different cell type 1. Cell shows bundle of tonofilaments. 2. Cell shows features of myoepithelial 3. Small cuboidal cells. Diagnosis of Adenoid cystic carcinoma is little difficult. In some cases, the mucoid material and the cuffing of myoepithelial cell mimics a pleomorphic adenoma. Rarely, predominant Basaloid pattern into the tumor are confused with Basal cell Adenocarcinoma or infiltrative Basal cell carcinoma of the eyelid. Differential diagnosis is important because Basaloid Adenoid cystic carcinoma is high grade malignancy and basal cell adenocarcinoma is a low grade malignancy. The expression of C-kit, a transmembrane receptor tyrosine kinase, in adenoid cystic carcinoma helps distinguish it from other low grade tumors.⁹ DNA analysis of salivary gland adenoid cystic carcinoma shows that tumor to be aneuploidy.¹⁰ The expression of P53 may correlate with prognosis.¹¹

Materials and Methods

A retrospective study of 14 cases of Adenoid cystic carcinoma of lacrimal gland tumors were studied. These cases are collected over period of 10 years. Clinical history was taken with specific focus on age, sex and histopathological examination include macroscopic examination and microscopic examination with special stains like PAS (periodic acid Schiff's) stain and immunohistochemistry where it required. For histopathological examination specimen were processed in 10% buffered formalin and then processed, sectioned and stained with Haematoxylin and Eosin stain. For Microscopic Examination Haematoxylin and Eosin stained sections were studied from various different area. Sections were examined for diagnosis of lesion, others histological characteristic and

differentiation and for individual tumor cells type which includes size, characters of nucleus, shape, nucleolus.

Result

Total 57 cases of lacrimal gland tumor were studied among them 14 cases of Adenoid cystic carcinoma so 24.56% incidence rate for Adenoid cystic carcinoma. Other tumor was diagnosed are pleomorphic adenoma 38 cases (66.66%), mucoepidermoid carcinoma 2 cases (3.51%), squamous cell carcinoma 1 case (1.75%), primary ductal cell carcinoma 1 case (1.75%), and malignant mix tumor 1 case (1.75%)(table1) but in this study our focus on Adenoid cystic carcinoma, incidence of Adenoid cystic carcinoma is 24.56 % in our study. Present study consists of 14 cases of Adenoid cystic carcinoma of lacrimal gland. When studied according to the age group, then 0-20 years' groups consist of zero (0) cases, 4 cases in 21-40 years' age group consist of 28.57% cases, 8 cases in 41-60 years age groups consist of 57.14 cases, and > 60 years age group consist of 2 cases (14.29%) (Table 2). When 14 cases studied according to sex then out of 14 cases, 9 cases (64.29%) were in female and 5 cases (35.71%) were in males (Table 3). When studied focus on histopathological features of Adenoid cystic carcinoma, specifically various microscopic histopathological pattern then, cribriform pattern in 6 cases (42.86%), tubular pattern in 5 cases (35.71%), sclerotic pattern in 3 cases (21.43%), Basaloid pattern in 2 cases (14.29%), and mixture of two or more than two pattern which is known as a mixed pattern is seen in 7 cases(50%)(table 4), and some other histopathological features like perinural invasion is seen in 4 cases (28.57%), vascular invasion is seen 2 cases(14.29%), mitotic Fig. (0 to 6 per HPF) in 3 cases (21.43%).(table 5)

Discussion

A study of 14 cases of Adenoid cystic carcinoma of lacrimal gland over 10 years was done. When cases are divided according to age and sex then results are summarized in Table 2. So among total 14 cases the maximum cases in age group is 41-60 years age group (Table 2) contain 8 cases

(57.14%), second age group which contain most cases is 21-40 years age group contain 4 cases (28.57%), and after that > 60 years age group contain 2 cases (14.29%), and followed by 0-20 years contain 0 cases. So Adenoid cystic carcinoma is very rare in early age in childhood in our study. Secondly when focus in sex distribution of tumor in specific age group as well as in total cases result is out of 14 cases total 9 cases (64.29%) are seen in female and 5 cases (35.71%) are seen in male. And when divided into specific age group and then incidence noted according to sex then individual age group shows no clear cut female predominance (Table 3). Now on when focused on various histopathological pattern on microscopy study results are following. On microscopy 7 cases (50%) cases show mixed pattern, 6 cases (42.86%) shows cribriform pattern (Fig. 1), 5 cases (35.71%) shows tubular pattern, 3 cases (21.43%) shows sclerotic pattern, 2 cases (14.29%) shows Basaloid pattern. Other histological changes are also detected but they are not in notifiable amount. Among 14 cases 4 cases (28.57%) are shows perinural involvement, when in 02 cases (14.29%) shows clear cut vascular invasion, and in 3 cases (21.45%) mitotic figure noted. So on above result the most common histological pattern seen on microscopy is mixed pattern (50 %), second most common is cribriform in 42.86% cases, followed by tubular pattern (35.71%), and sclerotic pattern in (21.43%), Basaloid pattern in 14.29 % cases.so for the summary Adenoid cystic carcinoma is relatively common in female and common presenting age group is late age (5th decade onward) and most common histological pattern present is the mixture of 2 or more than 2 pattern. And comparison for incidence in various study for adenoid cystic carcinoma (table 6) is done then results are, in our study the incidence of ACC is 14 cases (24.56%), FONT & GAMEL 1987 study⁴ 70 cases (26 %), Wright et al 1992 study¹² 38 cases (30 %), Font et al 1998 study³ 12 cases (27 %). So the incidence frequency percentage s are quite matching with other different study.

Table 1: Incidence of tumor in lacrimal gland

No	Tumor	No of cases	Percentage (%)
1	Pleomorphic adenoma	38	66.66 %
2	Adenoid cystic carcinoma	14	24.56 %
3	Mucoepidermoid carcinoma	02	3.51%
4	Squamous cell Carcinoma	01	1.75%
5	Primary Ductal carcinoma	01	1.75%
6	Mixed Mullerian Tumor(MMT)	01	1.75%
Total		57	100 %

Table 2: Adenoid cystic carcinoma's incidence according to age in lacrimal gland

Age Group (Years)	No of Cases Adenoid Cystic Carcinoma	(%)
0-20	0	0 %
21-40	4	28.57%
41-60	8	57.14%
>60	2	14.29%
Total No O Cases	14	100%

Table 3: Adenoid cystic carcinoma's incidence according age and sex in lacrimal gland

Age groups(years)	No of cases in female	No of cases in male	Total
0-20	00	00	00
21-40	02	02	04
41-60	06	02	08
>60	01	01	02
Total	09	05	14

Table 4: Histological patterns present in Adenoid cystic carcinoma of lacrimal gland

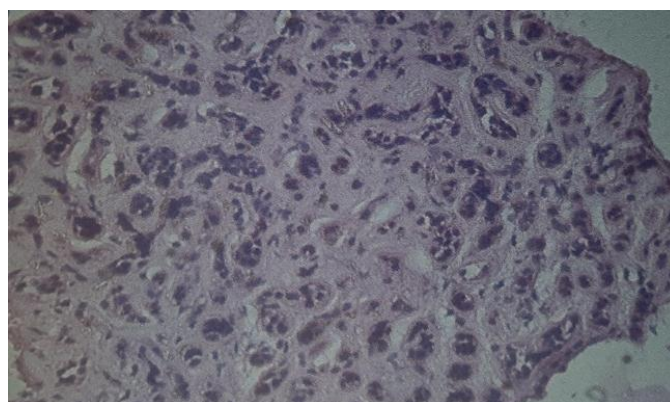
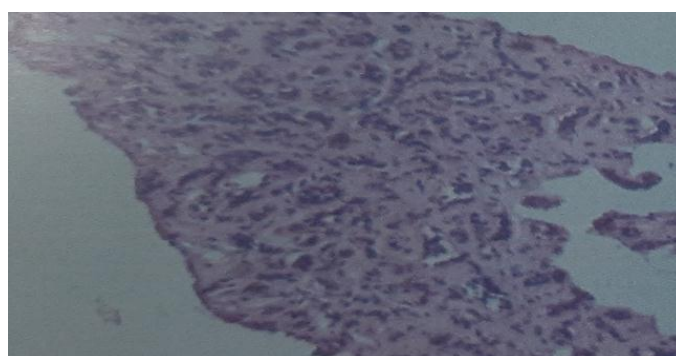
No	Histological patterns	No of cases	Percentages (%)
1	Mixed(≥ 2 patterns) patterns	7	50 %
2	Cribriform patterns	6	42.86 %
3	Tubular patterns	5	35.71 %
4	Sclerotic patterns	3	21.43 %
5	Basaloid patterns	2	14.29 %

Table 5: Other histological features

No	Histological features	No of cases	Percentages (%)
1	Perinural invasion	04	28.57 %
2	Vascular metastasis	02	14.29 %
3	Mitosis	03	21.45 %

Table 6: Frequency of adenoid cystic carcinoma in lacrimal gland in various study

Study Name	Incidence of Adenoid cystic carcinoma
Font & Gamel 1987	70(26 %)
Wright et al 1992	38(30%)
Font et .1998	12(27%)
OUR STUDY	14(24.56%)

**Fig. 1:** Cribriform pattern in adenoid cystic carcinoma (CRI-Briform Pattern, H & E Stain,10X)**Fig. 2:** Cri-briform pattern in Adenoid cystic carcinoma (H & E STAIN,40X)

Conclusion

This study of adenoid cystic carcinoma of lacrimal gland shows Adenoid cystic carcinoma is the most common malignant epithelial tumor of the lacrimal gland. The common age for Adenoid cystic carcinoma is the late age mostly 41-60 year age groups contain 57.14% cases, if bar is raised and group is made 41-60 + > 60 years groups then more than 70% or exactly 71.43% cases fall in that group and in early and middle life means in childhood and adult this tumor is less prevalent but incidence are there .And after that focus on gender we found that out of 14 cases 9 cases are seen in female means 64.29% cases are seen in female show it indicate slight female preponderance, but in individual age group no evidence of female preponderance. On comment in histological pattern on microscopy shows most common histological pattern noted was mixture of 2 or more than 2 pattern which is seen in 50% cases, followed by the cribriform pattern in 42.86 % cases.

Conflict of Interest: None.

References

- Iwamoto T, Jakobiec FA. A comparative ultra-structural study of the normal lacrimal gland and its epithelial tumors. *Hum pathol* 1982;13:236-62.
- Ostrowski ML, Font RL, Halpern J, Nicolitz E, Barnes R, Clear cell epithelial-myoepithelial carcinoma ARISING IN PLEOMORPHIC ADENOMA OF THE LACRIMAL GLAND. *Ophthalmol* 1994;101:925-30.
- Font LC, Croxatto J, Rao N. Tumors of the Eye and Ocular Adnexa. Vol 55th ed. Washington, DC American Registry of pathology and Armed forces institute of pathology 2006
- Font RL, Gamel JW, Adenoid cystic carcinoma of the lacrimal gland: a clinicopathologic study of 79 cases. In: Nicholson D, ed. *Ocular pathology update*. New York: Masson Publishing USA: 1980:277-83
- Grossniklaus HE, Abbuhl MF, McLean IW, Immunohistologic properties of benign and malignant mixed tumor of the lacrimal gland. *Am J Ophthalmol* 1990;110:540-9
- Lee DA, Campbell RJ, Waller RR, Ilstrup DM. A clinicopathologic study of primary adenoid cystic carcinoma of the lacrimal gland. *Ophthalmol* 1985;92:128-34.
- Wright JE, Rose GE, Garner A. Primary malignant neoplasms of the lacrimal gland. *Br J Ophthalmol* 1992;76:401-7
- Tellado MV, McLean IW, Specht CS, Varga J. Adenoid cystic carcinomas of the lacrimal gland in childhood and adolescence. *Ophthalmol* 1997;104:1622-5.
- Gamel JW, Font RL, Adenoid cystic carcinoma of the lacrimal gland: the clinical significance of a basaloid histologic pattern. *Hum Pathol* 1982;13:219-25.
- Iwamoto T, Jakobiec FA, A comparative ultrastructural study of the normal lacrimal gland and its epithelial tumors. *Hum Pathol* 1982;13:236-62. Sturgis CD, Silverman JF, Kennerdell JS, Raab SS. Fine-needle aspiration for the diagnosis of primary epithelial tumors of the lacrimal gland and ocular adnexa. *Diagn Cytopathol* 2001;24:86-9.
- Penner CR, Folpe AL, Budnick SD. C-kit expression distinguishes salivary gland adenoid cystic carcinoma from polymorphous low-grade adenocarcinoma. *Pathol* 2002;15:687-91.
- Wright JE, Rose GE, Garner A. Primary malignant neoplasms of the lacrimal gland. *Br J Ophthalmol* 1992;76:401-7.

How to cite this article: Desai PB, Shah A. Histopathological study of adenoid cystic carcinoma in lacrimal gland. *Arch Cytol Histopathol Res* 2019;4(2):164-7.