

## Primary tuberculosis of male breast: A rare case presentation

Ashrafulla M.R<sup>1\*</sup>, Madakatti B.S<sup>2</sup>, Giridhar R. Kuknoor<sup>3</sup>, Mayur M Kadam<sup>4</sup>, Yettinamath K.M<sup>5</sup>

<sup>1,5</sup>Pathologist, <sup>2</sup>HOD of General Surgeon, <sup>3</sup>District Surgeon, General Surgeon, <sup>1,5</sup>Dept. of Pathology, <sup>2,4</sup>Dept. of general Surgery, District Hospital Dharwad, Karnataka, India

\*Corresponding Author: Ashrafulla M.R

Email: ashrafulla@icloud.com

### Abstract

The primary tuberculosis of breast is a rare disorder which can be mistaken for pyogenic or neoplasm's of the breast. We are reporting a case of 60 year old male who presented with a swelling in right breast. Surgeons made a diagnosis of Breast abscess, Neoplasm and Radiologist gave a diagnosis of breast abscess. FNAC of the swelling revealed granulomatous mastitis with superadded acute inflammation.

**Keywords:** Breast, FNAC, Abscess, Swelling, Tuberculous mastitis.

### Introduction

Tuberculosis is a chronic granulomatous disease, most commonly involve Lungs, but it can involve any organ in the body. Tuberculosis of the breast is a rare entity, which is often mistaken for other lesions of the breast.<sup>1,2</sup> The tuberculosis of the breast was first explained by Sir Astley Cooper in the year 1829 and recorded the occurrence of "Scrofulous swellings in the bosom" of young women.<sup>3</sup> Breast tuberculosis can be part of haematogenous spread, but isolated breast tuberculosis can occur which is a rare incidence as previously described in many literatures. The Breast tuberculosis is very rare in males which can be confused with Gynecomastia and breast carcinoma.<sup>10</sup> So proper evaluation is required to prevent delay in start of treatment.

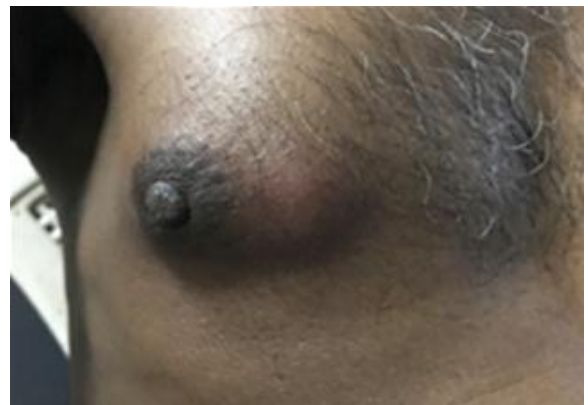### Case Report

A 60 year old male patient presented to surgery OPD, district hospital Dharwad with 1 to 2 months history of swelling in the right breast and fever more in the night. The patient didn't had any positive TB contacts at the time of presentation. No history of diabetes mellitus/hypertension/Tuberculosis/bronchial asthma or any other disease was present. Surgeons made a diagnosis of Breast abscess, Neoplasm and Radiologist gave a diagnosis of Breast abscess.

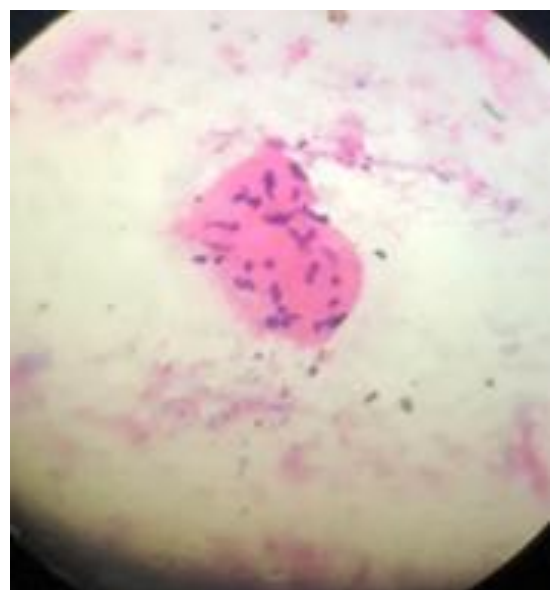
On examination, swelling was in sub areolar and inner side of the right breast. Swelling measured 4x4 cms, skin over the swelling was erythematous and on palpation slightly tender. No axillary nodes were palpable. Chest X-ray was normal. Random blood sugar was 102mg/dl, HIV test was negative. ESR was high.

FNAC was done with 5ml syringe with 23G needle, Aspiration was purulent, 3 slides were made. Haematoxylin & Eosin stain, Leishman stain and Auramine-Rhodamine stain were used; Microscopy showed epithelioid cell granulomas, Langhan's type giant cells with necrotic material, Auramine-Rhodamine stain for tubercle bacilli was positive. Diagnosis of primary tuberculous mastitis was made. Medical officer of primary health center Belavatagi,

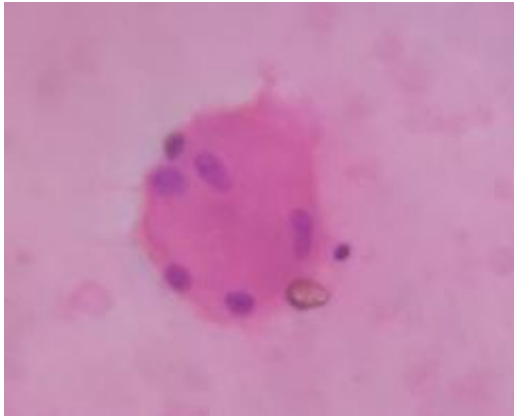
Haliyal taluk, Karwar district was informed to start anti tuberculous treatment under RNTCP Programme. He is responding to treatment and currently followed up.



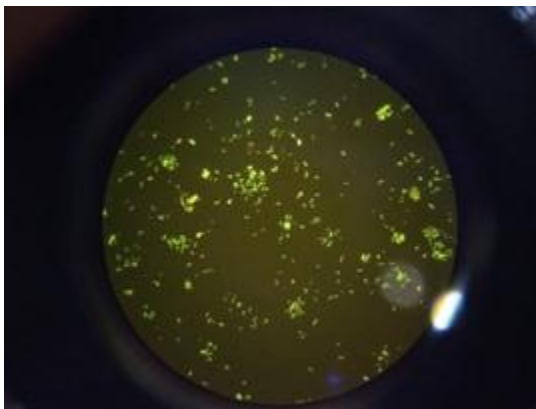
**Fig. 1:** Swelling in the right breast



**Fig. 2:** Epithelioid cell granuloma



**Fig. 3:** Langhan's type of giant cell



**Fig. 4:** Tubercle bacilli seen under fluorescent microscope

### Discussion

Breast tissue along with skeletal muscle and spleen resist for survival and multiplication of tubercle bacilli.<sup>9</sup> Hence tuberculous mastitis is a rare occurrence. The disease, although almost exclusively a prerogative of the female, is not limited to females. In 1 series of 439 patients, as many as 4% were males.<sup>8</sup> In our one year study of FNAC of 71 breast lesions, 69 were females and 2 were males, Tuberculous mastitis amounts to 1.4% of FNACs. Tuberculosis of the breast is more commonly seen in females of reproductive age group who are multipara, it is very uncommon in males, prepubescent females and elderly women.<sup>9</sup> our case was a male, so it is a rare entity. Tuberculosis flourishes among urban people may be due to poverty, overcrowding and also in elderly people, immunocompromised conditions like HIV. Our patient is poor, elderly individual from rural area.

The Tuberculosis of the breast can be primary when there is no foci of infection in the body elsewhere and secondary as result of spread from other organs.<sup>5,6</sup> In our case, there was no evidence of tuberculosis in the body, so tuberculous mastitis was considered as primary form, which is a rare presentation of the tuberculosis.

Most common site of lump in breast is seen in central or upper outer quadrant.<sup>4</sup> In our case swelling was in sub areola and inner side of the right breast.

The differential diagnosis of breast TB includes Granulomatous inflammatory diseases, such as idiopathic Granulomatous mastitis, Sarcoidosis and fat necrosis<sup>7</sup>

FNAC is an important tool for the diagnosis of breast tuberculosis with identification of epithelioid cell granulomas and tubercle bacilli under microscopy or mycobacterial culture.<sup>5</sup> In present case FNAC was done, Epithelioid cell granulomas, Langhan's type of giant cell were seen under microscope and tubercle bacilli was identified with Auramine rhodamine stain. Imaging modalities has limited value but FNAC is a safe, easy, opd procedure for the diagnosis.

### Conclusion

Tuberculosis of the male breast is very rare, because of rarity can be misdiagnosed as suppurative lesion or Neoplasm of breast, hence all the cases of breast abscess or lump in the breast should be investigated thoroughly as the disease can be treated conservatively.

**Conflict of Interest:** None.

### References

1. Kalac N, Ozkan B, Bayiz H, Dursun AB, Demira F. Breast tuberculosis. *Breast* 2002;11(4):346-9
2. Banerjee SN, Ananthkrishnan N, Mehta RB, Parkash S, Tuberculous mastitis:a continuing problem. *World J Surg* 1987;11:105-9
3. Mckeown KC, Wilkinson KW. Tuberculosis disease of the breast. *Br J Surg* 1952;39:420
4. Yuen JHF, Lam TPW, Leong L, Primary tuberculosis of the breast. *J Hong Kong Coll Radiol* 2003; 6(1):33-5
5. Tewari M, Shukla HS. Breast tuberculosis: diagnosis, clinical features & management. *Indian J Med Res* 2005;122:103-10
6. Jah A, Mulla R, Lawrence FD, Pittam M, Ravichandran D, Tuberculosis of the breast: experience of a UK breast clinic serving an ethnically diverse population. *Ann R Coll Surg Engl* 2004;86:416-9.
7. Meral Sen, Canan Gorpelioglu, Mikdat Bozer. Isolated primary breast tuberculosis-report of three cases and review of the literature. *Clin (Sao Paulo)*.2009; 64(6):607-10
8. Morgan, M.: Tuberculosis of the breast. *Surg Gynecol Obstet* 1931;53:593.
9. Hamit HF, Ragsdale TH. Mammary tuberculosis. *JR SOC Med* 1982;75:764-5
10. Quaglio G, Pizzol D, Bortolani A, Manenti F, Isaakidis P, Putoto G et al. Breast tuberculosis in men: A systematic review. *Plos One* 2018;13(4):e0194766.

**How to cite this article:** Ashrafulla MR, Madakatti BS, Kuknoor GR, Kadam MM, Yettinamath KM. Primary tuberculosis of male breast: A rare case presentation. *Arch Cytol Histopathol Res* 2019;4(2):177-78.