



Original Research Article

Establishment of nuclear grade evaluation method for endometrial endometrioid carcinoma, and the significance of separately evaluating nuclear atypia of the glandular and solid structure parts

Haruhiko Yoshioka^{1,*}, Miho Iwaya², Kayo Horie¹, Yoshihito Yokoyama³, Jun Watanabe¹

¹Dept. of Bioscience and Laboratory Medicine, Hirosaki University Graduate School of Health Sciences, Aomori, Japan

²Dept. of Clinical Examination, Odate Municipal General Hospital, Odate, Japan

³Dept. of Obstetrics and Gynecology, Hirosaki University Graduate School of Medicine, Aomori, Japan



ARTICLE INFO

Article history:

Received 07-08-2019

Accepted 14-08-2019

Available online 01-10-2019

Keywords:

Endometrium

Endometrioid carcinoma: EMC

Nuclear grade: NG

Case-nuclear grade: Case-NG

Glandular and solid part-nuclear grade score pattern: GS-NG

ABSTRACT

Aim: The objectives of this study were to: 1) establish a nuclear grade evaluation method for endometrioid carcinoma, and 2) evaluate the nuclear grade of each part in cases in which glandular and solid parts are present within the same tumor, and confirm its correlation with clinicopathological factors, through which the usefulness of this nuclear grade evaluation method was assessed.

Material and Methods: Samples were 19 preparations of specimens (4 endometrium in proliferation phase, 8 endometrioid carcinoma G1 and 7 G3 cases) in HE-stained histological preparations (2- μ m thin sections). The nuclear grade evaluation method for endometrioid carcinoma comprises 6 items of the nuclear atypia index and each item is scored 1-3. The nuclear grade (NG) was classified as follows based on the total score (6-18 points): NG-I, 6-10; II, 11-13; III, 14-18. Then, in cases in which glandular and solid parts were present within the same tumor, the nuclear grades of these parts were separately evaluated. The nuclear grade pattern (glandular and solid part-nuclear grade score pattern: GS-NG pattern) was classified into 4 types: GS-NG patterns 1-4. The highest NG score in each case, designated as "case nuclear grade (Case-NG)", was positively correlated with p53 expression, and two patients who died of primary disease were Case-NG III.

Conclusion: Histological nuclear grade evaluation method for endometrioid carcinoma, and the significance of separately evaluating nuclear atypia of the glandular and solid structure parts, was a useful method.

© 2019 Published by Innovative Publication.

1. Introduction

The prevalence and mortality of endometrial cancer have recently increased in Japan.¹ Endometrial cancer originates from the endometrium, and is divided into estrogen-dependent Type I and estrogen-independent Type II. Endometrial endometrioid carcinoma (endometrioid carcinoma) accounts for most of Type I cases. Endometrioid carcinoma develops from endometrial hyperplasia as a precursor lesion or often accompanies endometrial hyperplasia as a background lesion. Histologically, it is classified mainly based on structural atypia into Grade 1

(G1: the solid part accounts for 5% or less) to Grade 3 (G3: the solid part exceeds 50%).² G3 often invades deeply into the muscle layer even in the early stage of advancement, being highly malignant, and the prognosis is poor. Therefore, objective evaluation of the grade is clinicopathologically important. However, other than structural atypia, the objective index of malignancy has not been sufficiently investigated.

Moreover, although the grade is to be increased by one rank when nuclear atypia is high-grade, no nuclear atypia evaluation method has been established and grade judgment is difficult in some cases. Fewer studies on the nuclear grade have been reported.³⁻⁵ Thus, we examined a nuclear grade evaluation method for endometrioid carcinoma.

* Corresponding author.

E-mail address: yoshioka@hirosaki-u.ac.jp (H. Yoshioka).

Endometrioid carcinoma exhibiting no features of transition between the glandular and solid parts with a clear boundary within the same case (EMC with GS) may be observed in clinical practice. But there is no description of this in the WHO classification² and it is difficult to decide the final nuclear grade for each part. Moreover, the relationship between the nuclear grade in these cases and malignancy is unclear.

The objectives of this study were to: 1) establish a nuclear grade evaluation method for endometrioid carcinoma, and 2) evaluate the nuclear grade of each part in cases in which glandular and solid parts are present within the same tumor, and confirm its correlation with clinicopathological factors, through which the usefulness of this nuclear grade evaluation method was assessed.

2. Materials and Methods

2.1. Definition of EMC with GS

This was defined as cases with glandular and solid structure with a clear boundary within the same tumor without features of transition between the 2 parts.

A schema and photographs of the distribution mapping of the glandular and solid parts are shown in Figure 1.

2.2. Nuclear grade evaluation method

2.2.1. Materials

This study was approved by the ethics committee of Hirosaki University Graduate School of Medicine (No. 2013-232). HE-stained samples from patients diagnosed with endometrioid carcinoma between April 2010 and December 2014 at the Gynecology Department of Hirosaki University Hospital were used.

2.2.2. Nuclear grade score (NG score) and nuclear grade (NG)

The criteria of items to evaluate NG were investigated by observing 12 visual fields in HE-stained histological preparations (2- μ m thin sections) (objective lens: 20-times magnification) of 4 cases of endometrium in the proliferate phase (Pro-phase), 24 visual fields of 8 cases of endometrioid carcinoma G1 (G1), and 21 visual fields of 7 cases of endometrioid carcinoma G3 (G3), for a total of 19 cases (57 visual fields).

NG evaluation method was as follows: Each visual field was scored 1-3 based on the criteria with regard to the following 6 items: 1) irregularity of nuclear size, 2) irregularity of nuclear morphology, 3) chromatin morphology, 4) chromatin distribution, 5) nucleolar size, and 6) proliferation ability (features of nuclear division). Each item was scored 1-3 based on the criteria (Figure 2) and their total score was adopted (range: 6-18) for NG.

Regarding irregularity of nuclear size, homogenous size or variation by less than 2-times was scored as 1 and variation by 3- times or more was scored as 3. Nucleoli scored as 1 were small non-noticeable nucleoli similar to those in the normal endometrial proliferative phase, and nucleoli scored as 3 were large noticeable nucleoli in HPF (objective lens: 40- times magnification). Proliferation ability was evaluated as follows: Fewer than 5, 5 or more but fewer than 10, and 10 or more nuclear divisions per 10 HPF were scored as 1, 2, and 3, respectively, and this was observed in a hot spot.⁶

NG was evaluated based on NG score described below:

NG score was evaluated in 3 visual fields (objective lens: 20-times magnification) in each case and the highest score was adopted as NG score. The mean of NG scores determined by 3 raters (one pathologist and 2 cytotechnologists) was adopted as the final NG score.

2.2.3. Case nuclear grade (Case-NG)

NG grade of EMC with GS was evaluated in 27 visual fields each in the glandular growth part (G-GS) and solid growth part (S-GS), for a total of 54 visual fields, contained in HE-stained tissue samples from 9 patients whose prognoses were confirmed.

NG of G-GS and S-GS were determined from NG scores. For the final NG of each case (Case-NG), the grade of the part with a higher score was adopted. Then, NG of G-GS and S-GS of EMC with GS were compared with those of G1 and G3.

2.2.4. Correlation between Case-NG and clinicopathological factors

The correlations of the Case-NG with the final pathological diagnosis, surgical stage,² nuclear p53-positive rate, which is a prognostic factor for endometrial cancer^{7,8} (cut-off: 20%, 0%: 0 point, above 0 to 20% or lower: 2, higher than 20%: 3, designated as p53 score), and the outcome of EMC with GS were investigated.

2.3. Statistical analysis

The cut-off value of NG was determined by ROC analysis using Excel statistics 2012. Each score was subjected to the Shapiro-Wilk test and the results were non-normal. Thus, the significance of differences was analyzed using the Mann-Whitney U-test setting the significance level at 0.05% or lower.

Inter-rater reliabilities of NG score and NG were analyzed using the intraclass correlation coefficient (ICC).

ICC value was evaluated as follows: 0.21-0.40, fair; 0.41-0.60, moderate; 0.61-0.80, substantial; 0.81-1.00, almost perfect.⁹

The correlations between Case-NG and the clinicopathological factors were determined using Spearman's rank correlation. Significant differences in the variance of NG

score items were confirmed using the Kruskal-Wallis test. For the statistics software, SPSS 16.0 Japan was used.

3. Results

3.1. Evaluation of NG of EMC with GS

Inter-rater reliabilities of NG score and NG calculated from the intraclass correlation coefficients (ICC) were 0.74 and 0.96, respectively, and the evaluations were substantial and almost perfect, respectively, demonstrating the inter-rater reliability of the method to be sufficient. NG was classified into 3 grades as follows based on the cut-off value calculated by ROC analysis of NG score:

Nuclear grade type I (NG-I): 6-10 points

Nuclear grade type II (NG-II): 11-13 points

Nuclear grade type III (NG-III): 14-18 points

NG scores for each histology are shown in Table 1. A significant difference in variance ($p < 0.001$, Kruskal-Wallis test) was noted in all NG score items in each histology.

The results of comparison of NG score s between G1 and G-GS are shown in Figure 3. The score of G-GS (median [min, max]: Med, interquartile range: IR) (Med: 12 [7, 16], IR: 3) was significantly higher than those of Pro-phase (Med: 8 [7, 12], IR: 1) and G1 (Med: 11 [8, 14], IR: 2).

Similarly, the results of comparison of NG score s between G3 and S-GS are shown in Figure 4. The score of S-GS (Med: 13 [8, 18], IR: 5) was lower than that of G3 (Med: 15 [11, 18], IR: 2), but it exhibited variation (IR).

NG of G-GS and S-GS in each case of EMC with GS are shown in Table 2.

3.2. Correlation between evaluation of Case-NG and clinicopathological factors in EMC with GS

The correlations between the Case-NG and the final pathological diagnosis, surgical stage, p53 score, and outcome of EMC with GS are shown in Table 2.

NG of EMC with GS based on the combination of NG of G-GS and S-GS was classified into 4 types (GS-NG patterns 1-4).

GS-NG pattern-1: NG - I in both parts in one case (Case 1, 11.1%)

GS-NG pattern-2: Intermediate type (intermediate between GS-NG pattern -1 and 3) in 4 cases (Cases 2 and 5-7, 44.4%)

GS-NG pattern-3: NG-III in both parts in 2 cases (Cases 3 and 9, 22.2%)

GS-NG pattern-4: Divergent type (difference between G-GS and S-GS NG scores was 6 or greater) in 2 (Cases 4 and 8, 22.2%)

NG score of G-GS was higher than that of S-GS (reverse case) in 2 cases (Cases 6 and 7, 22.2%).

Next, the correlations of Case-NG with the surgical stage, p53 score, and outcome were investigated. The correlation of Case-NG with the surgical stage was low

($rs=0.42$), but a high positive correlation with p53 score, a poor prognostic factor, was noted ($rs=0.90$).

Regarding the relationship with the outcome, 2 patients died of primary disease (Case 3: Stage IA with invasion of less than 1/2 of the myometrium without vascular invasion. The disease recurred as carcinomatous peritonitis and the patient died after 3 years and one month. Case 8: Stage IVB. Six cycles of TC were performed after surgery, but the patient died of intraperitoneal recurrence after 8 months) and NG was Case-NG III, being high, in both cases.

HE histological staining of a sample from Case 3 is shown in Figure 5. This case was GS-NG pattern 3 and the patient died of primary disease, being a poor outcome, even though the surgical stage was Stage 1A.

4. Discussion

4.1. Nuclear grade evaluation method for endometrioid carcinoma

There have been few studies in which a histological nuclear grade evaluation method for endometrioid carcinoma was objectively converted into numerals. In a study on cytology of endometrioid carcinoma, the nuclear grades 1-3 were determined based on the scores of 10 items among the characteristics of endometrioid carcinoma cells in cytology preparations, which enabled investigation of the nuclear grade of endometrioid carcinoma.³

In our study, NG score was determined from the 6 evaluation items among the histopathological nuclear findings of endometrioid carcinoma: 1) irregularity of nuclear size, 2) irregularity of nuclear morphology, 3) chromatin morphology, 4) chromatin distribution, 5) nucleoli, and 6) proliferation ability (features of nuclear division). NG score was determined from these items, and classified into 3 grades: 6-10 points, NG-I; 11-13, NG-II; 14-18, NG-III.

Tumors for which the nuclear and histological grades are reflected in the treatment include non-invasive papillary urothelial carcinoma,¹⁰ which is divided into low and high grades based on the structural and nuclear grades.

In vasivoductal carcinoma of the mammary gland⁶ is classified into histological grades (Grades I-III) based on the structural and nuclear grades. NG of this carcinoma is classified into NG 1-3 by classifying the degree of atypia (score 1-3 points) and combining this with the nuclear division score (score 1-3 points).

In the WHO classification of prostate tumors,¹¹ the sum of histological grades 0-4 and NG I- III is defined as WHO Grade, and NG is judged based on the findings of atypia.

In the WHO classification concerning endometrial cancer,² the nuclear atypia evaluation method is not specifically described. The objective evaluation of nuclear atypia in the G-GS and S-GS in each tissue using histopathological preparations of endometrioid carcinoma

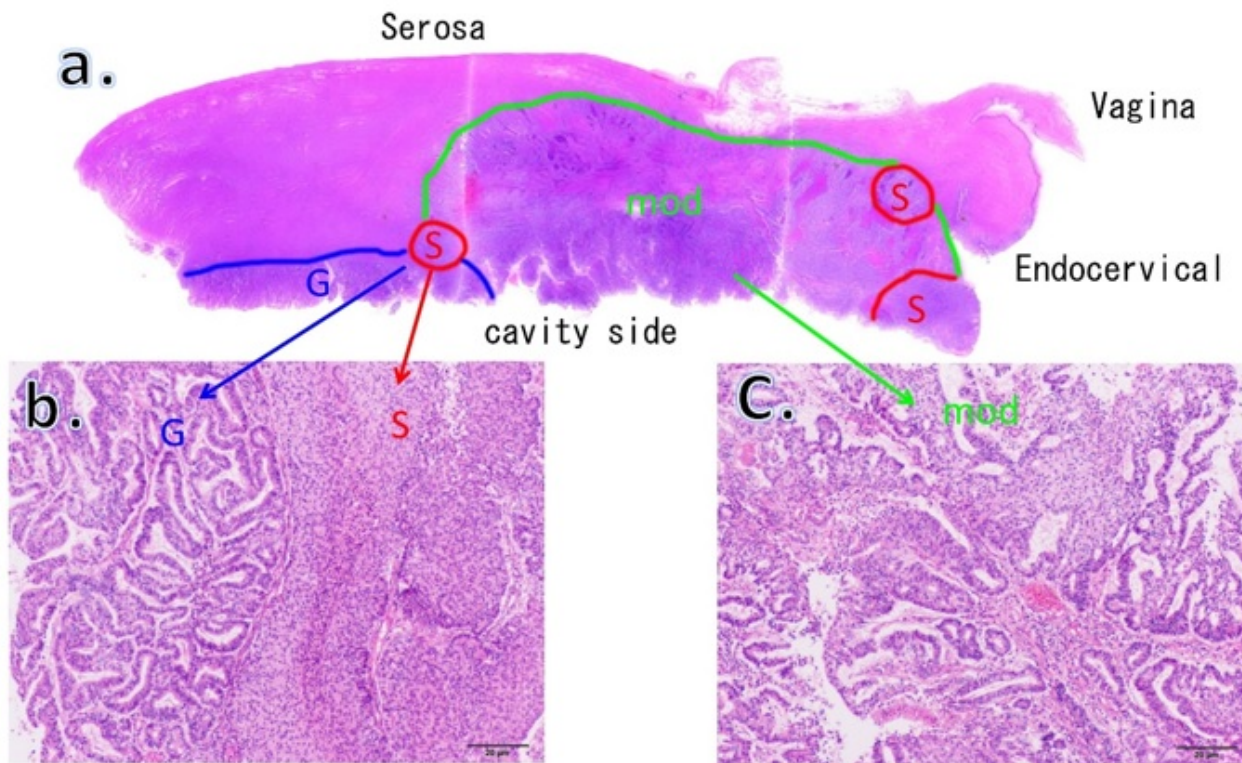


Fig. 1: Endometrioid carcinoma exhibiting no features of transition between the glandular and solid parts with a clear boundary within the same case (EMC with GS); **a:** Schema of the distribution mapping of glandular component (G-GS), solid growth component (S-GS) (Table 2, case 7).; **b:** G-GS(G) and S-GS(S) (H.E. stain, x4); **c:** Moderate differentiated component (Mod) (H.E. stain, x4)

Table 1: Comparison of nuclear grading score in each histology

Cases [Score range:1-3]	Irregularity of nuclear size	Nuclear morphological irregularity	Chromatin morphological granularity	Chromatin distribution	Size of nucleoli	Proliferative ability	Nuclear grade score [range: 6~18 points]
Pro-phase(n=12)	1.1±0.4	1.1±0.3	1.9±0.4	1.2±0.5	1.4±0.5	1.0±0.0	7.8±1.1
G1 (n=24)	1.8±0.5	1.9±0.3	1.9±0.4	2.1±0.5	1.5±0.5	1.9±0.8	11.0±1.4
G3 (n=21)	2.5±0.6	2.3±0.5	2.3±0.7	2.6±0.5	1.9±0.5	3.0±0.0	14.6±1.6
G-GS (n=27)	1.9±0.7	1.9±0.6	2.0±0.6	2.2±0.7	1.6±0.7	2.0±0.5	11.6±2.5
S-GS (N=27)	2.2±0.7	2.2±0.6	2.3±0.5	2.6±0.5	2.0±0.8	2.2±0.9	13.5±2.8
p value *	<0.001	<0.001	<0.001	<0.001	<0.001	<0.001	<0.001

*Kruskal Wallis test (One-way analysis of variance)

performed in this study is a new attempt. When 2 or more NG were observed within the same case, such as those in EMC with GS, the higher nuclear grade was adopted, which was also novel.

Using the nuclear grade evaluation method (intraclass correlation coefficient ICC=0.74-0.94) of EMC with GS established in this study, reduction of inter-rater differences in evaluation of NG is expected.

4.2. NG of EMC with GS

NG of EMC with GS was classified into 4 types using NG evaluation method [GS-NG pattern 1: NG- I in both parts in 1 case (Case 1, 11.1%), GS-NG pattern 2: intermediate type (intermediate between GS-NG pattern- 1 and 3) in 4 cases (Cases 2 and 5-7, 44.4%), GS-NG pattern 3: NG-III in both parts in 2 cases (Cases 3 and 9, 22.2%), GS-NG pattern 4: divergent type (difference between G-GS and S-GS NG scores was 6 or greater) in 2 (Cases 4 and 8, 22.2%)]

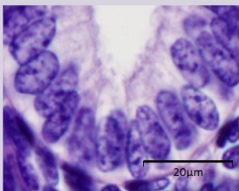
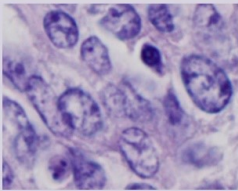
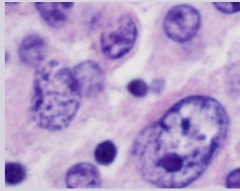
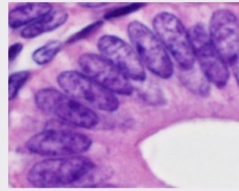
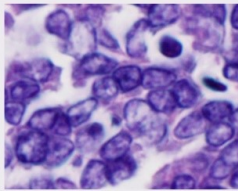
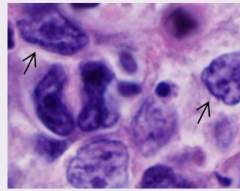
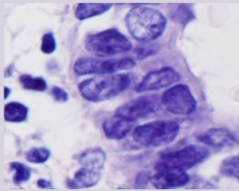
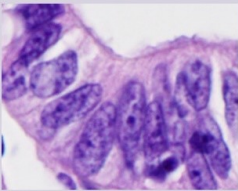
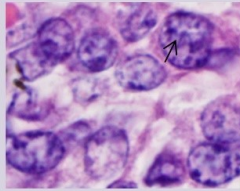
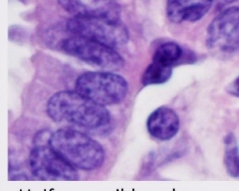
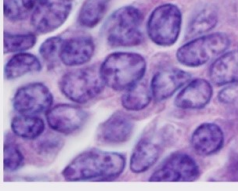
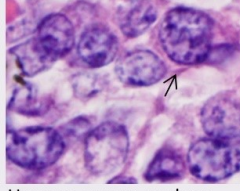
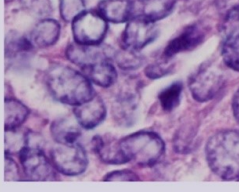
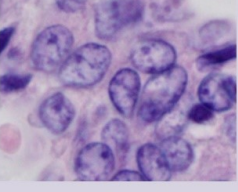
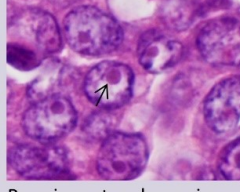
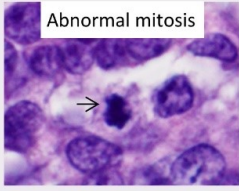
items	Score 1 point	Score 2 point	Score 3 point
Irregularity of nuclear size	 <p>Uniform size, or less than double</p>	 <p>midpoint</p>	 <p>3 times or more</p>
Nuclear morphological irregularity	 <p>Similar form, or mild</p>	 <p>midpoint</p>	 <p>Completely different, or Severe (→)</p>
Chromatin granularity	 <p>Fine, or minute chromatin</p>	 <p>midpoint</p>	 <p>Coarse, or aggregate chromatin (→)</p>
Chromatin distribution	 <p>Uniform, mild nuclear membrane thickening</p>	 <p>midpoint</p>	 <p>Uneven, severe nuclear membrane thickening(→)</p>
Large nucleoli	 <p>Not prominent, or small size</p>	 <p>midpoint</p>	 <p>Prominent, or large size (→)</p>
Proliferation potency (mitosis)	 <p>Abnormal mitosis → < 5 /10 HPF (→)</p>	<p>6 ≤、<10 /10HPF (Object ×40)</p>	<p>11 ≤ /10HPF (Object ×40)</p>

Fig. 2: Criteria images of six items for nuclear grade score

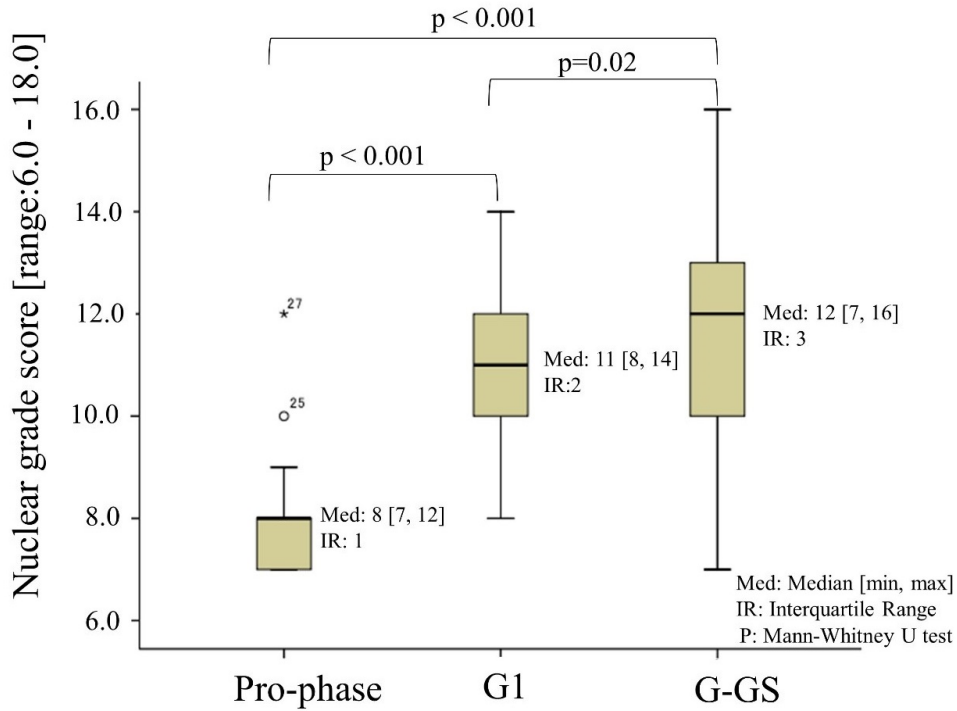


Fig. 3: Comparison between proliferative phase (Pro-phase) and G1 of endometrioid carcinoma (G1) and glandular part of endometrioid carcinoma of clear border growth between glandular and solid part (G-GS)

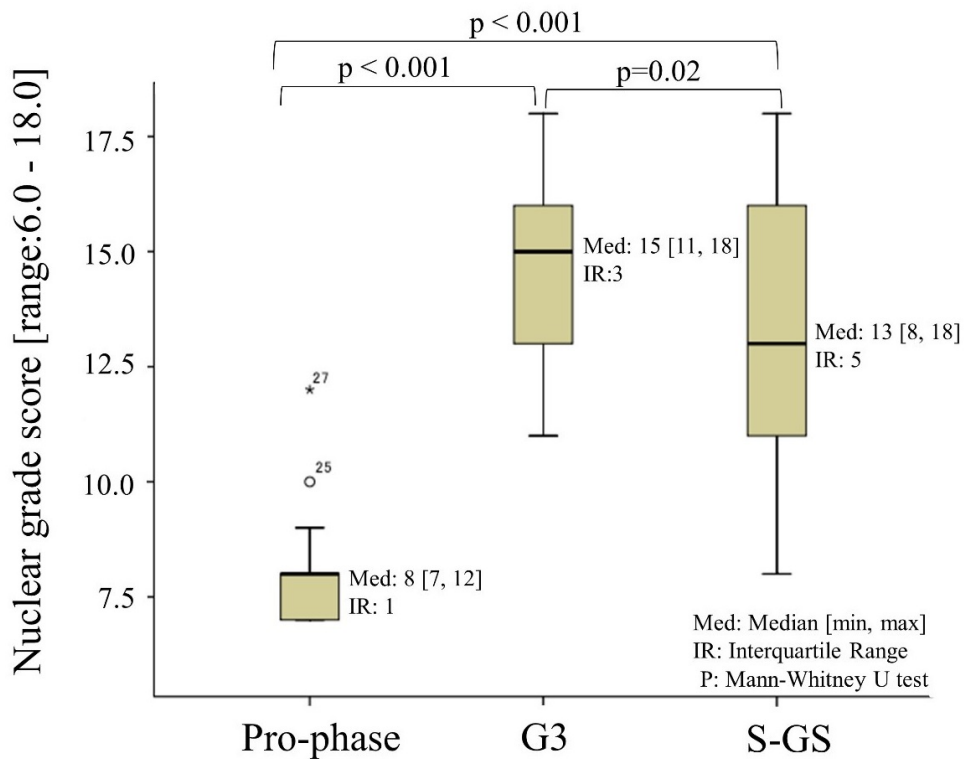


Fig. 4: Comparison between proliferative phase (Pro-phase) and G3 of endometrioid carcinoma (G3) and solid part of endometrioid carcinoma of clear border growth between glandular and solid part (S-GS)

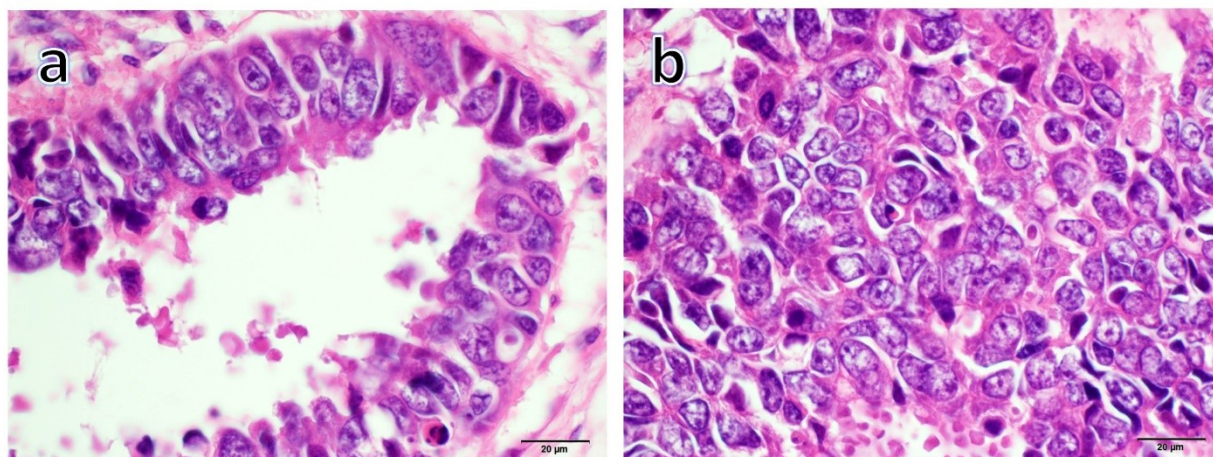


Fig. 5: GS- NG pattern-3 of endometrioid carcinoma of clear border growth between glandular and solid part. HE stain, $\times 40$; **a:** Glandular part of endometrioid carcinoma of clear border growth between glandular and solid part (G-GS) presented NG-III.; **b:** Solid part of endometrioid carcinoma of clear border growth between glandular and solid part (S-GS) presented NG-III.

Table 2: Comparison of nuclear grading of EMC with GS and clinicopathological parameters

Cases	Pathological grades	Surgical stage	P53 score	G-GS scores (Grade)	S-GS scores (Grade)	Case-nuclear grades	Prognosis
1	G2	IB	0	9 (I)	10 (I)	I	Disease-free survival
2	G3	IA	0	11 (II)	13 (II)	II	Disease-free survival
3	G1	IA	2	15 (III)	16 (III)	III	Death by tumor
4	G3	IIIC2	2	11 (II)	17 (III)	III	Disease-free survival
5	G3	IA	0	12 (II)	13 (II)	II	Disease-free survival
6	G3	IA	1	14 (III)	13 (II)	III	Disease-free survival
7	G2	IIIC1	0	12 (II)	11 (II)	II	Disease-free survival
8	G3	IVB	1	12 (II)	18 (III)	III	Death by tumor
9	G3	IIIA	2	16 (III)	17 (III)	III	Disease-free survival

Of these, Case-NG score (range: 6-18) of patients who died of primary disease (Cases 3 and 8) were 16 and 18, respectively, and both were Case-NG III, clarifying that it is important to separately evaluate G-GS and S-GS, and determine NG in each part to evaluate Case-NG in cases of EMC with CGS, even in G1 cases considered to have a good prognosis.¹²

In cases of NG III and Case-NG III, such as Case 3, in particular, the outcome may be poor even though the stage is IA. It was clarified that the necessity of strict follow up and increase in the grade from G1 to G2 in these cases.

GS-NG pattern 4 of EMC with GS: divergent type (the difference in NG score between G-GS and S-GS is 6 or greater) was noted in 2 cases (Cases 4 and 8, 22.2%), and NG score of G-GS may be higher than that of S-GS in some

cases (reverse case), as noted in 2 cases (Cases 6 and 7, 22.2%). Thus, the cancer development mechanisms in these cases may be different from that in G1.

In GS-NG pattern 3 (NG- III in both parts) and GS-NG pattern 4 (divergent type) of EMC with GS, Case-NG was high and the positive correlation with the poor prognostic factor P53 was strong, suggesting a poor prognosis.^{7,8} It is necessary to examine the association with genetic abnormalities such as p53 gene mutation and amplification of PIK3CA. In addition, why NG score of S-GS of EMC with GS is lower than that of G3 requires further investigation (Table 1, Figure 4). Furthermore, whether the mechanism of divergence of the NG score of GS-NG pattern 4 (divergent type) is due to dedifferentiation of S-GS needs to be clarified.^{13,14}

The usefulness of the nuclear grade evaluation method in which nuclear atypia is evaluated by the histological structure of endometrioid carcinoma in consideration of its correlation with the final pathological diagnosis, surgical stage, and p53 score was investigated.

The outcome of EMC with GS may be predicted by Case-NG determined by evaluating the NG of each component, G-GS and S-GS, which suggested the necessity of separately evaluating NG of the components.

5. Source of funding

None.

6. Conflict of interest

None.

References

1. A report of gynecologic oncology committee of Japan. *Acta Obstet Gynecol Jpn*. 2008;60:1001–1085.
2. Japan Society of Obstetrics and Gynecology. The Japanese Society of Pathology. The General Rules for Clinical and Pathological Management of Uterine Corpus Cancer, Pathological edition, 4th ed. Japan: Kanehara ; 2017,.
3. Nishimura Y, Watanabe J, Jobo T, Hattori M, Arai T, Kuramoto H. Cytologic scoring of endometrioid adenocarcinoma of the endometrium. *Cancer Cytopathol*. 2005;105:8–12.
4. Richard JZ, Robert JL, Karen LD, Marrow CP. The Utility of the Revised International Federation of Gynecology and Obstetrics Histologic Grading of Endometrial Adenocarcinoma Using a Defined Nuclear Grading System, A Gynecologic Oncology study. *Cancer*. 1995;75:81–86.
5. Kato T. Determination of Nuclear atypia of endometrial lesion. In: Tumor Pathology differential diagnosis Atlas, The Uterine Corpus. Tokyo: Bunkodo. 2014;p. 146–151.
6. Colditz G, Chia KS. Invasive breast carcinoma. In: Lakhani SR, Ellis LO, Schnitt SJ, Tan PH, van de Vijver MJ. WHO Classification of Tumours of Breast. 4th ed. Lyon: IARC press ; 2012,.
7. Watanabe J, Nishimura Y, Tsunoda S, Kawaguthi M, Okayasu I, Kuramoto H. Liquid-Based Preparation for Endometrial Cytology -Usefulness for Predicting the Prognosis of Endometrial Carcinoma Preoperatively. *Cancer Cytopathol*. 2009;117:254–263.
8. Salvesen HB, Iversen OE, A. Prognostic Significance of Angiogenesis and Ki-67, p53, and p21 Expression: A Population-Based Endometrial Carcinoma Study. *J Clin Oncol*. 1999;17(5):1382–90.
9. Landis JR, Kosh GG. The measurement of observer agreement for categorical data. *Biometrics*. 1997;33:159–174.
10. Japan Radiological Society: General Rule for Clinical and Pathological Studies on Renal Pelvic, Ureteral and Bladder Cancer. *Jpn Urol Assoc*. 2011;p. 79–137. The Japanese Society of Pathology. 1st ed. Japan: Kanehara.
11. Humphrey PA, Egevad L, Amin MB, Epstein JI, Helpap B, et al. WHO Classification of Tumours of The Urinary System and Male Genital Organs. Holger M, Peter AH, Thomas MU, Victor ER, editors ; 2016,. Acinar adenocarcinoma. 4st ed. Lyon: IARC press.
12. Mikami Y. Current Status of Endometrial Cancer Histological classification. In: Tumor Pathology differential diagnosis Atlas, The Uterine Corpus. Tokyo: Bunkodo. 2014;p. 2–14.
13. E, Devis PN, Erkekin L, Campoy T, Martinez I, E. The EMT signaling pathways in endometrial carcinoma. *Clin Transl Oncol*. 2012;14:715–720.
14. Cristina MM, Inigo E, Irene F, Xavier D, Jaime P, Xavier MG. Epithelial to mesenchymal transition and stem cells in endometrial cancer. *Hum Pathol*. 2013;44:1973–1981.

Author biography

Haruhiko Yoshioka Assistant Professor

Miho Iwaya Cytotechnologist

Kayo Horie Assistant Professor

Yoshihito Yokoyama Professor

Jun Watanabe Professor

Cite this article: Yoshioka H, Iwaya M, Horie K, Yokoyama Y, Watanabe J. Establishment of nuclear grade evaluation method for endometrial endometrioid carcinoma, and the significance of separately evaluating nuclear atypia of the glandular and solid structure parts. *Arch Cytol Histopathol Res* 2019;4(3):220-227.