



Case Report

A case report of myxoid liposarcoma of buccal mucosa

Lakshmi Agarwal^{1,*}, Anamika, Manmohan², Rajeev¹

¹Dept. of Pathology, Government Medical College, Kota, Rajasthan, India

²Pushpadai Cancer Care Center, Kota, Rajasthan, India



ARTICLE INFO

Article history:

Received 29-08-2019

Accepted 05-09-2019

Available online 01-10-2019

Keywords:

Oral cavity
Liposarcoma
Rare
Morphology
Surgery

ABSTRACT

Liposarcoma is one of the commonest malignancies of adipose tissue. It occurs rarely in oral cavity. Due to its rarity, it possesses a diagnostic challenge to both the clinician and pathologist. But awareness about this entity can help in diagnosing this lesion and thereby decreasing the mortality and morbidity of the patients. We present a case report of myxoid liposarcoma in a 55 years old male, treated with surgery followed by radiotherapy. The patient is followed up for 3 years and is free of disease.

© 2019 Published by Innovative Publication.

1. Introduction

Liposarcoma is considered to be the commonest soft-tissue sarcoma of adipose tissue and was first described by Virchow in 1857.^{1,2} But it is very rarely found in the oral cavity. Buccal mucosa is the most common site followed by floor of the mouth, tongue etc. WHO has classified it into four types with unique clinical settings and behaviour. They are dedifferentiated liposarcoma, myxoid liposarcoma, pleomorphic liposarcoma, and liposarcoma not otherwise specific. Myxoid liposarcoma is the most common variant. The peak incidence is between 40 and 60 years of age, with men more frequently affected than women. The rarity of this tumor in oral cavity can lead to misdiagnosis and inappropriate management. Here we present a case of myxoid liposarcoma of oral cavity

2. Case Report

A 55-year-old male patient was referred for the assessment of the thickening of the right cheek and heaviness of face.

On examination, a soft, painless space occupying lesion in the buccal space was found. The overlying mucosa was healthy. There were no associated neck nodes. CT scan of face revealed a contrast enhanced mass at buccal space with infra orbital extension. Maxillary bone, zygoma and infra orbital plate/small bone appeared free [Figure 2]. Trucut biopsy of the mass was reported as myxoid variant of liposarcoma. Metastatic workup was done and found to be a localized disease. Wide local excision of tumor with negative margin was done and adjuvant radiotherapy was given [Figure 1].

Grossly tumor appeared as multiple pieces of creamy-brownish tissue with soft to elastic consistency measuring 4cm in greatest diameter [Figure 3]. Histopathological examination of the excised tumor revealed a neoplastic tissue composed of monomorphic stellate shaped cells without atypia. Prominent chicken wire vasculature was evident [Figure 4]. Numerous signet ring lipoblasts, particularly at periphery of lobules were also seen [Figure 5]. Mitosis and necrosis were absent. There was no metaplastic cartilage and bone formation. The separately sent margin was negative. IHC was done. The tumor cells

* Corresponding author.

E-mail address: drlaxmiagarwal@gmail.com (L. Agarwal).

were positive for vimentin and negative for desmin, CK, CD34 [Figures 6 and 7].

The final diagnosis of myxoid variant of liposarcoma was made.

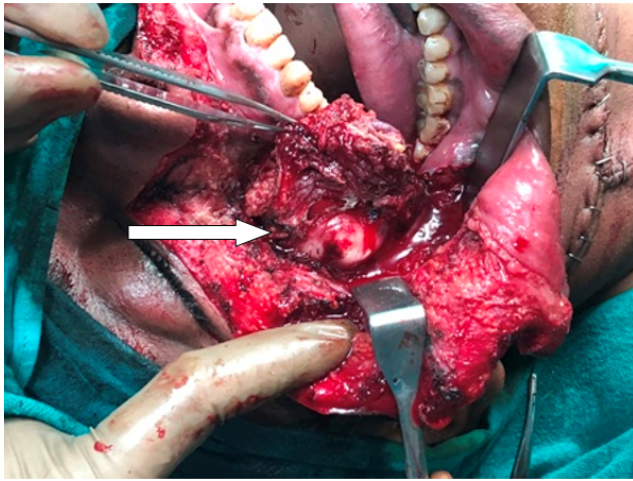


Fig. 1:

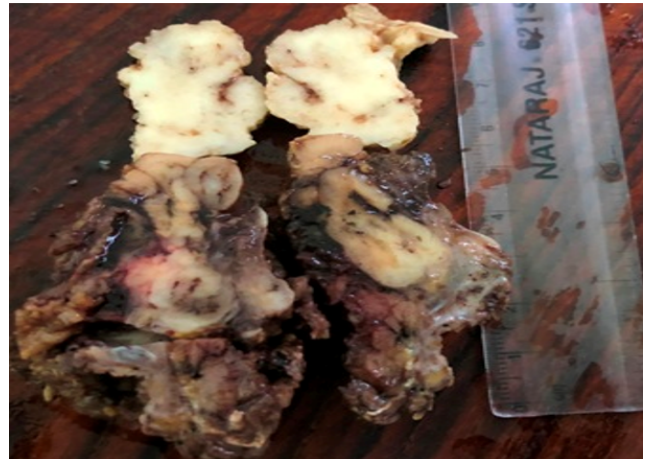

Fig. 3:

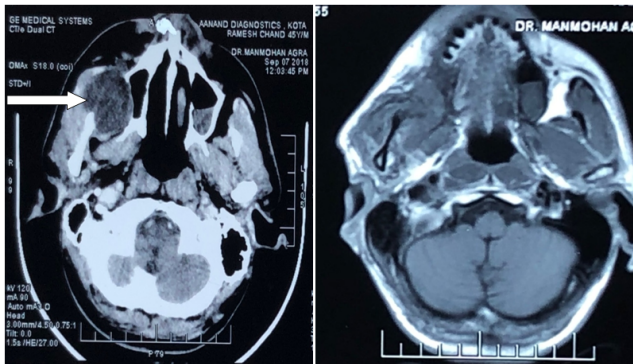


Fig. 2: Pre-operative image; Post operative

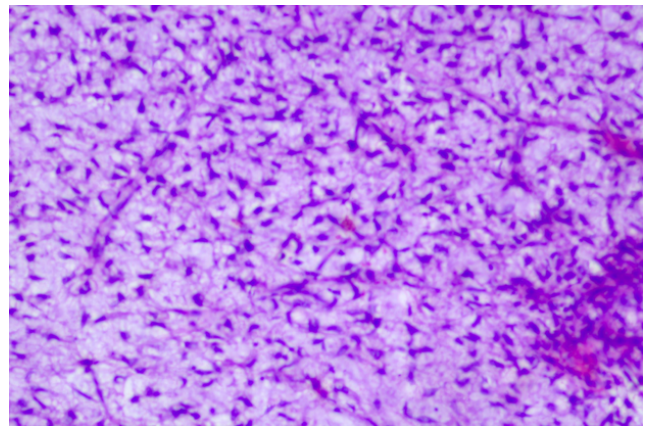


Fig. 4: H&E image, 10X showing lipoblast and chicken wire vasculature against myxoid background

3. Discussion

Liposarcomas are slow growing tumor and most patients have no symptoms until the tumor reaches a size large enough to cause pain, tenderness or functional disturbances. They are usually well-circumscribed neoplasms, not encapsulated, firmer and less easily compressible than lipomas. Liposarcomas rarely metastasize unless these tumors become dedifferentiated.³ They tend to recur locally. Myxoid liposarcoma occur rarely in oral cavity. The most common site is limbs. Karen J. Fritchie et al³ has described various patterns which include traditional myxoid, traditional round cell, pseudoacinar, lipoblast-rich, island, stromal hyalinization, lipomatous, cord-like, nested, chondroid metaplasia, and hemangiopericytoma (HPC)-like. The traditional myxoid was found to be the most

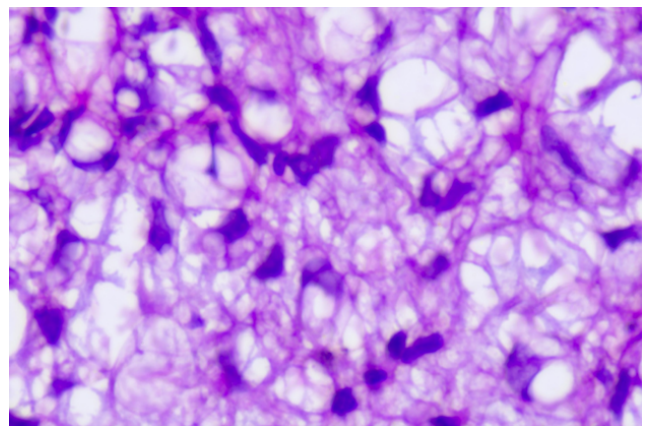


Fig. 5: H&E 40X image showing lipoblast, multi and uni vacuolated

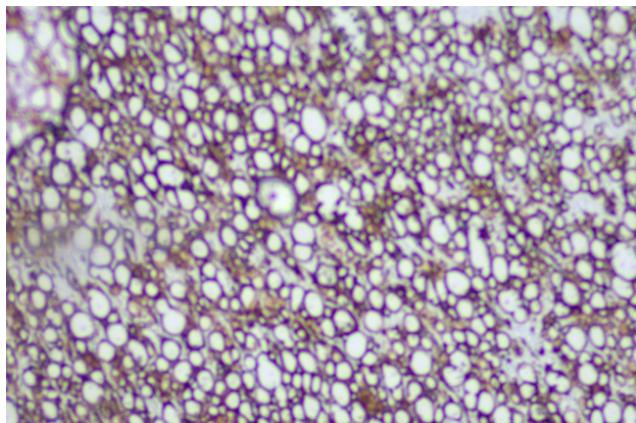


Fig. 6: IHC: Vimentin positive

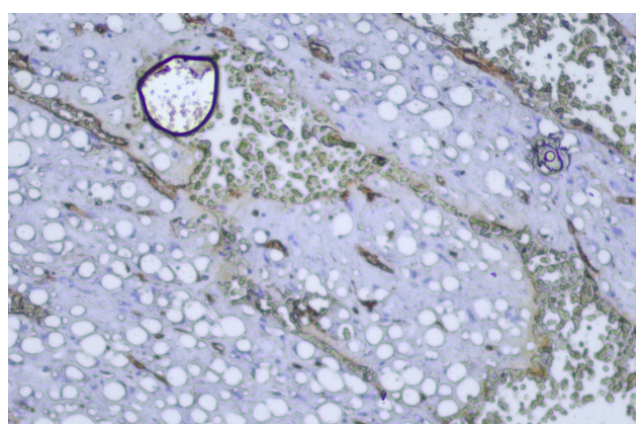


Fig. 7: IHC: CD 34 negative

common and has good prognosis. The pathognomonic t(12;16)(q13;p11) translocation that results in expression of the FUS-DDIT3 fusion protein is found in 90% of patients, whereas a smaller proportion carries *EWSR1-DDIT3* gene fusions. Though the diagnosis of this tumor is straight forward as morphology of this tumor is very characteristic, it can be misdiagnosed clinically. It possesses a diagnostic challenge for both clinician and pathologist due to its rarity and lack of characteristic sign and symptoms. Clinical and radiologic findings have limited value for definite diagnosis. Sometimes histopathology may pose diagnostic challenge due to overlapping histopathological features. The differential diagnosis includes various benign and malignant lesions such as lipomas, branchial cyst and lymphoma. The presence of fat in CT and MRI images may suggest a lipomatous tumor such as lipoma and liposarcoma. However, it's fairly difficult to definitely diagnose such masses between liposarcomas and other soft tissue neoplasm based on radiography. Histological examination along with IHC and cytogenetic plays a significant role in diagnosing and further sub classification of this tumor. Both myxoid and round cell liposarcomas have the same genetic translocation.^{4,5} It has 69–100% of

disease-specific survival with high risk of local recurrence (7–28%). The presence of hypercellularity or round cell differentiation is associated with worsening of prognosis and higher rate of metastases. Histologic grade, tumor subtype, location and free surgical margins are considered as most reliable prognostic factors.⁶ A <5 cm maximum diameter is also considered a favorable prognostic factor for oral liposarcomas. Myxoid liposarcoma has favourable prognosis.

Complete surgical excision with free margin and radiotherapy is the mainstay of treatment. The role of radiation is controversial. Pack and Pierson⁷ reported an increase in 5-year survival from 50% to 87% with combined surgery and radiation therapy compared to surgery alone. Evans⁸ studied 55 cases and found that there is decrease in local recurrence for patients with myxoid liposarcoma treated with surgery followed by radiation compared to surgery alone. However, a significant difference in survival between the two groups was not shown. Lymph nodes dissection is not indicated as the metastasis to nodes is rare. In the present case also, the patient was treated with surgery followed by radiotherapy. He was followed for three years and is free of tumor [Figure 2].

4. Conclusion

Intraoral liposarcoma is a rare lesion. Histological classification is indispensable not only in discriminating the variant, but also in predicting clinical behavior and prognosis. Immunohistochemistry helps in this, and provides the key to discriminate between the various forms. Awareness about this entity can reduce the mortality and morbidity associated with this tumor. Complete excision of tumor with free margin followed by radiotherapy is the treatment of choice.

5. Source of funding

None

6. Conflict of interest

None

References

1. Virchow R. A case of malignant occurring in part in the form of fat neuroma tumors. *Virchows Arch Pathol Anat.* 1857;11(3):281–288.
2. Kim YB, Leem DH, Baek JA, Ko SO. Atypical lipomatous tumor/well-differentiated liposarcoma of the gingiva: A case report and review of literature. *J Oral Maxillofac Surg.* 2014;72:431–439.
3. Fritchie KJ. Histologic Spectrum of Myxoid Liposarcoma. *Am J Clin Pathol.* 2012;137:229–239.
4. Davis EC, Ballo MT, Luna MA, Patel SR, Roberts DB, et al. Liposarcoma of the head and neck: The University of Texas M. D. Anderson cancer center experience. 2009;31:28–36.
5. Fletcher CDM, Bridge JA, Hogendoorn PCW. Pathology and Genetics of Tumours of Soft Tissue and Bone. 4th ed. Lyon: IARC Press; 2013. WHO Classification of Tumours of Soft Tissue and Bone. ;.

6. Gagari E, Kabani S, Gallagher GT. Intraoral liposarcoma: Case report and review of the literature. *Oral Surg Oral Med Oral Pathol Oral Radiol Endod.* 2000;89:66–72.
7. Pack GT, Pierson JC. Liposarcoma: a study of 105 cases. *Surg.* 1954;36:686–712.
8. Evans HL. Liposarcoma: a study of 55 cases with a reassessment of its classification. *Am J Surg Pathol.* 1979;3:507–522.

Anamika PG Student

Manmohan Consultant Oncosurgeon

Rajeev Professor

Author biography

Lakshmi Agarwal Assistant Professor

Cite this article: Agarwal L, Anamika , Manmohan , Rajeev . A case report of myxoid liposarcoma of buccal mucosa. *Arch Cytol Histopathol Res* 2019;4(3):279-282.